

Case Report

Simplest Way to Fabricate Custom Made Ocular Prosthesis- A Case Report

Dr. Lylajam. S¹, Dr. Rajkumar Bansal², Dr. K. Harshakumar³,
Dr. Prasanth Viswambaran⁴

¹Professor, ²Post graduate student, ³Professor & HOD, ⁴Assistant Professor,
Department of Prosthodontics, Government Dental College, Thiruvananthapuram

Corresponding Author: Dr. Rajkumar Bansal

ABSTRACT

Loss of eye whether congenital or due to trauma causes disfigurement and affects the patient psychologically. An ocular prosthesis can improve the esthetic as well as confidence of the patients. Ocular prosthesis can be custom made or readymade eye shell. To improve the comfort and matching of the prosthesis with that of adjacent natural eye a custom made ocular prosthesis is preferred. In this case report custom made eye is fabricated from an impression made in stock eye shell.

Key words: ocular impression; ocular prosthesis; iris painting; stock tray

INTRODUCTION

Face is the presentable part of the human body. Eyes are the most important organ of the body, the loss of which causes disfigurement of the face and affect the patient psychologically. Some patients lost their ocular structure due to trauma or due to congenital defect. Removal of eye ball is called enucleation and extraocular muscles remain intact after enucleation. An ocular prosthesis is an artificial substitute for an enucleated eye ball. A prosthesis which adapt well, improves the psychological state of the patient and also increases the patient's confidence. ⁽¹⁾

An ocular prosthesis may be available readymade (stock ocular) shells or can be custom made. A stock ocular prosthesis can be given when time limitation exists and cost factor is taken into consideration. ⁽²⁾ But a stock ocular prosthesis has many disadvantages, such as ill-fitting, improper shade matching with natural adjacent eye. Whereas a custom made ocular prosthesis have

properadaptation, it may have slight movements and matches the iris position as that of the adjacent natural eye. ^(3,4) Here a custom made ocular prosthesis fabrication is described where the readymade eye shell is used as impression tray.

CASE REPORT

A female patient aged 38 years reported to the department of prosthodontics Govt. Dental College Thiruvananthapuram with chief complaint of ill- fitting right eye prosthesis. She had a history of trauma and eye ball was enucleated followed by placement of stock eye prosthesis. On examination there was some inflammation due to ill-fitting prosthesis, so the patient was advised to discontinue the prosthesis. After two weeks there was complete healing. The internal anatomy of socket in resting position was good especially the mobility of posterior wall due to intact musculature. Patient counseled about the treatment and regarding expected result.

Technique;

Topical anesthesia 0.5% tetracaine hydrochloride was applied to increase the patient's comfort during impression procedure. The existing stock eye shell was adjusted and used as conformer and a special tray was made and a hollow stem is attached to the tray. The tray stem assembly was evaluated before making impression for over extension. The patient was seated in upright position and Impression material light body was injected through the stem in to the socket (fig 2) and the patient was asked to do various functional movements.

The impression was removed after it was set and the light body impression boxed by alginate material to get a mold (fig.3). After 10 minutes an incision was made from the superior aspect along the stem of

impression tray to the bottom of alginate impression mold (fig 4). The mold spread apart, the impression and the tray removed and the alginate mold was closed properly. Molten wax was poured in to the mold using sprue made by the stem of impression tray (fig. 5). After 15 minutes wax pattern was removed, smoothed and tried for proper contouring (fig.6). Iris button was attached to the wax pattern and invested in a flask and processed with heat cure resin after characterization of scleral part. After processing it was polished using pumice and disinfected with 0.5% chlorhexidine. After thoroughly cleaning with saline solution to prevent chemical irritation it was inserted (fig. 7&8)

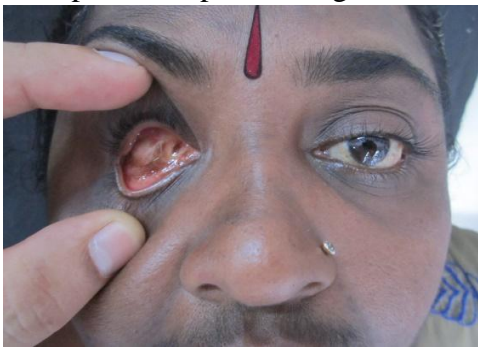

Fig. 1pre operative

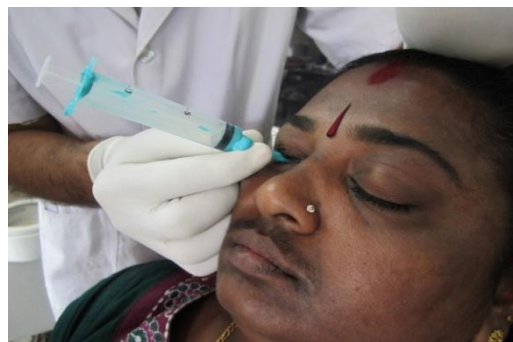

Fig. 2 impression making



Fig. 3 boxing of impression

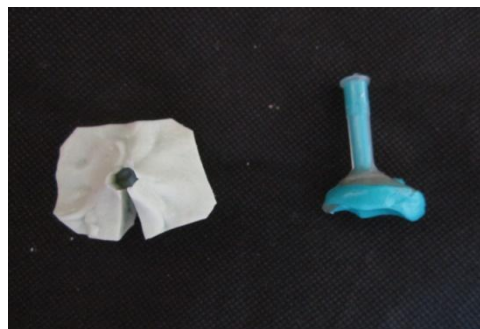

Fig. 4 boxed mould and impression




Fig. 5 pattern making.




Fig. 6 pattern trial



Fig. 7 finished prosthesis



Fig. 8 Post -Operative View

DISCUSSION

The disfigurement caused by the loss of eye is very traumatic physically and psychologically. Proper fit of prosthesis is necessary for the functions of the prosthesis. For a proper fit of prosthesis, it is mandatory that the impression should be made properly. The custom made ocular prosthesis conforms accurately to the socket as the prosthesis fabrication is based on the existing anatomy of the patient's eye socket, thus giving benefits of increased adaptation, movements of the eye ball, and the exact match of the iris position as that of adjacent natural eye. ⁽¹⁾ According to Beumer et al ⁽⁵⁾ intimate contact between the ocular prosthesis and the tissue bed is needed to distribute even pressure, so a prefabricated prosthesis should be avoided moreover the voids in the prefabricated prosthesis collect mucus and debris, which can irritate mucosa and act as a potential source of infection, which are minimized by only custom made prosthesis.

CONCLUSION

A simple technique for fabrication of a custom made ocular prosthesis has been described. A properly fabricated custom

made prosthesis enhances the patient's comfort and confidence by increased adaptiveness and natural appearance.

REFERENCES

1. Cain JR. custom ocular prosthetic . J prosthet Dent. 1982;48:690-4.
2. Taicher S, Steinberg HM, Tubiana I, Sela M. Modified stock-eye ocular prosthesis. J Prosthet Dent. 1985;54:95-8
3. Da Breo. Surgical and prosthetic consideration in management of orbital tumour. J Prosthet Dent.1992;67:106-12.
4. Ow Rk, Amrith S. ocular prosthesis use of a tissue conditioner material to modify a stock ocular prosthesis. J prosthet Dent. 1997;78:218-22.
5. Taylor TD, editor. Clinical maxillofacial prosthesis. London: Quintessense publication; 1998. Page 265-77.
6. Beumer J, editor. Maxillofacial rehabilitation prosthodontics and surgical consideration. St Louis (MO): Isiyaku Euro America Publication 1996.

How to cite this article: Lylajam. S, Bansal R, Harshakumar K et al. Simplest way to fabricate custom made ocular prosthesis- a case report. Int J Health Sci Res. 2017; 7(6):344-346.
