

Case Report

Double Crystalline Lens - A Rare Case Report

Sajad Khanday¹, Anshulee Sharma¹, Raashid Maqbool Wani²

¹Department of Ophthalmology, Government Medical College, Srinagar (Kashmir), India

²Consultant, ASG Eye Hospital, Srinagar (Kashmir), India

Corresponding Author: Raashid Maqbool Wani

ABSTRACT

Introduction: To report the case of an eye with congenital double crystalline lens.

Method: This is an observational case report.

Case Report: General physical examination of the patient showed marfanoid habitus. Slit lamp examination was performed which showed a cataractous chunk of lens material in the anterior chamber, pushing the iris behind. There was pupillary distortion and iris defect at 6 o' clock position, with synechiae formation between the iris and the cataractous lens. The other lens was at normal position.

Conclusion: To our knowledge, this is the first case reported with a diagnosis of congenital double crystalline lens, with one cataractous lens in the anterior chamber and the other at its normal position.

Key words: Cataractous lens, Lens Duplication

INTRODUCTION

Congenital anomalies of the lens include a wide range from lens coloboma to primary aphakia and doubling of the lens. The doubling of lens is a very rare anomaly, with only a few case reports with duplicated lens, that is, a single eye carrying two lenses has been described. [1-4] However, the exact mechanism is not known.

CASE REPORT

An 18 year old girl, presented to our department with chief complaints of diminution of vision and opacity in the left eye. The patient had noticed the opacity one year back. There was no history of any treatment or surgical intervention. In addition, no history pertaining to any trauma was given. Birth history was not significant.

General physical examination showed marfanoid habitus with long

tapering fingers (arachnodactyly), flat foot, positive Steinberg thumb sign and positive Walker Murdoch wrist sign. Chest, CVS, Abdominal and CNS examination was normal.

The Visual acuity was 6/9 in right eye and 6/60 in left eye. Best corrected visual acuity was 6/6 in right eye with -0.25D Sphere and 6/18 in left eye with -3D Sph/-1Dcyl \times 150°. Intra ocular pressure was 16mmHg in right eye and 18 mmHg in the left eye. The right eye was clinically normal with a normal fundus.

On slit lamp examination, the left eye showed cataractous chunk of lens material in the anterior chamber, pushing the iris behind, making the pigmented epithelial layer visible through the dilated pupil (Figure 1). There was papillary distortion with peaking of pupil at 5 o' clock and iris defect at 6 o'clock position, with

synechiae formation between the iris and the cataractous lens (Figure 2). The other lens was at normal position with few pigments over its anterior surface. The fundus was normal with a normal B-Scan study.



Figure 1:

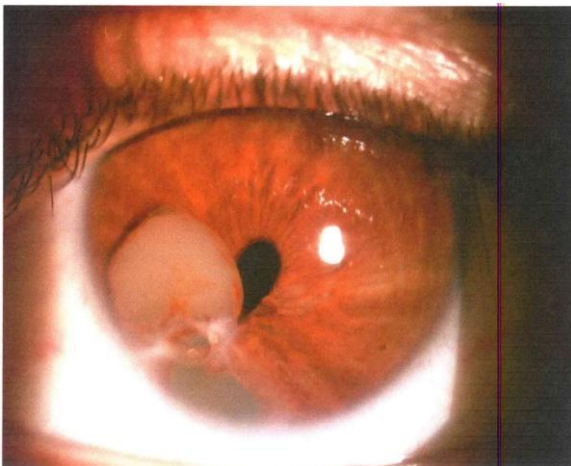


Figure 2:

DISCUSSION

Congenital duplication of lens is very rare phenomenon with only few cases reported so far. Partial congenital aphakia is a rare condition in which the lens appears to be partially divided by a deep furrow. [1] In the case of congenital duplication of lens reported by Thakkar et al two lenses were placed obliquely in a straight line with a clear area in between. [2] Absence of zonules and capsule between the two lenses was also noted. Richardson reported a case in which the two lenses were asymmetrical, one being larger than the other. [3] The patient also had corneal metaplasia, complete

coloboma of iris and fundus. Rupal Bhatt et al. reported a case with horizontally placed bilobed lens sharing a common capsular bag with an inferior iris coloboma. [4]

The mechanism for this anomaly is not known yet. Whether it is part of a phylentogenic spectrum or represents development from two embryonically separate lenses remains a question. Duke Elder has tried to explain the occurrence of the two entities based on separate embryonic developmental sequences. [1] He suggested that the metaplastic changes in the surface ectoderm leads the lens plate to invaginate at two place and forms two lens vesicles which results in double lens.

The major ocular abnormality in Marfan syndrome is ectopia lentis (lens subluxation or dislocation). While relatively little is known about the exact mechanism of this ocular pathology in Marfan syndrome, a number of theories have been suggested. Wheatley et al (1995) found that while fibrillin is localized to the superficial capsule and ciliary epithelial surface at the attachment of the zonules in normal eyes, Marfan patients lack such localization and exhibit abnormal ciliary processes with absent or severely disorganized zonules. [5] This pathology was found to be positively correlated with lens subluxation. Clinically, ectopia lentis is bilateral in 60-87% of Marfan patients and is stable from childhood. [5] However, the association of double crystalline lens and Marfans has not been established.

REFERENCES

1. Elder D. Anomalies of lens. In: System of Ophthalmology. Henry Kempton; 1969.p.688-741.
2. Thakkar H. Singh R. Congenital double crystalline lens. J Cataract Refract Surg 2003; 29:405-6.
3. Richardson O. Congenital anomalies of the anterior segment. Transcan Ophthalmol Soc 1951; 14:102-3.
4. Rupal Bhatt, Jitendra Jethani, Praveen Saluja, Vinay Bharti, Single lens to lens duplication: The missing link. Indian

- journal of Ophthalmology 2008; 56:67-68.
5. Wheatley H, Traboulsi E and Flowers B et al. Immunohistochemical localization of fibrillin in human ocular tissues. Relevance to the Marfan syndrome. Arch Ophthalmol 1995; 113:103-109.

How to cite this article: Khanday S, Sharma A, Wani RM. Double crystalline lens - a rare case report. Int J Health Sci Res. 2019; 9(1):303-305.
