

Original Research Article

## Quantitative Evaluation of Argyrophilic Nucleolar Organizer Regions in Different Histopathological Grades of Oral Squamous Cell Carcinoma

Girish. KL<sup>1</sup>, Pradeesh Sathyan<sup>2</sup>

<sup>1</sup>Professor, <sup>2</sup>Reader, Department of Oral Pathology,  
Sree Mookambika Institute of Dental Sciences, Kulasekharam

Corresponding Author: Girish. KL

### ABSTRACT

**Context:** Oral cancer is one of the tenth most common cancers worldwide and is a major problem in India and account for 50-70% of all cancers diagnosed. The most common type of oral cancer is squamous cell carcinoma, constituting about 90% of all oral malignancies and causing more deaths than any other oral disease. Dysplasia is an important feature of squamous cell carcinoma. The degree of epithelial dysplasia serves as a useful guide in diagnosis, histological grading and management of such lesions. Many recent reports have suggested that the number of nucleolar organizer regions (NORs) per nucleus is related to cellular proliferation and differentiation. NORs can be identified indirectly by means of argyrophilia of their associated proteins.

**Aims:** To evaluate the argyrophilic nucleolar organizer regions (AgNORs) in normal mucosa and different histopathological grades of oral squamous cell carcinoma.

**Materials and Methods:** The study included a total of forty samples of which ten cases each of well differentiated, moderately differentiated and poorly differentiated oral squamous cell carcinomas constituted the study group, whereas ten cases of normal mucosa formed the control group. AgNORs were analyzed in formalin fixed paraffin embedded tissue sections of histopathologically confirmed cases using silver staining technique. Counting of AgNORs was done and the mean AgNOR count was obtained and statistically analyzed using ANOVA test.

**Results:** There was a significant rise in mean AgNOR count of oral squamous cell carcinomas in the order of well differentiated ( $6.59 \pm 0.20$ ), moderately differentiated ( $7.96 \pm 0.22$ ) and poorly differentiated ( $8.84 \pm 0.24$ ) compared to that of normal mucosa ( $2.49 \pm 0.30$ ).

**Conclusions:** A high positive correlation was observed between NORs of well differentiated, moderately differentiated and poorly differentiated oral squamous cell carcinomas. The mean values of NORs increased as the grades increased.

**Key Words:** AgNORs, Silver staining, Squamous cell carcinoma

### INTRODUCTION

The occurrence of cancer has occupied a position of special significance, as a much feared disease and as an object of intensive biomedical investigation. Millions of new cases of invasive cancer are diagnosed each year of which oral cancer has a quite high incidence. This high rate of incidence of oral cancer has instigated workers in the various fields for its early

diagnosis. The need for diagnostic certainty depends upon the penalty for being wrong about the patient's true state. This is especially true in situations where establishment of a treatment threshold is wholly dependent upon diagnostic accuracy of an insidious disease. <sup>[1]</sup>

A broad array of chemical, physical and biologic agents can cause cancer either directly or indirectly. Most of the chemical

and physical agents like ionizing radiation or ultraviolet light may damage or alter DNA. The precise manner in which these agents damage DNA and lead to cancer is still under intensive investigation. One unifying hypothesis proposes that DNA damage results in breaks, translocations or deletions that activate oncogenes i.e. genes that have the potential to cause unrestrained growth if mutated in crucial ways. [2]

The nucleus plays an important role in the control of proliferation and protein synthesis. Nucleolar organizer regions (NORs) are loops of ribosomal DNA that occurs in the nucleoli. The NORs DNA possess ribosomal DNA genes which are transcribed by RNA polymerase I and ultimately direct ribosome formation and protein synthesis. The number of NORs in each cell nucleus reflects the cellular activity. NORs can be identified with the help of silver staining technique by which they are visualized in the nuclei of cells as brown or black dots by virtue of argyrophilia of NOR associated proteins. [3]

The Argyrophilic nucleolar organizer regions (AgNORs) as replicatory markers may have a place in objectively characterizing dysplasia and cell proliferation in tissue specimens. AgNOR staining is useful for studying normal proliferating cells, because it may be a quantitative marker of incipient cellular alterations before the histological hallmarks appear. This method has been considered to represent new additional diagnostic tool in tumour pathology. It has been employed to study the proliferative activity of various lesions. It was also stated that AgNOR count may provide information on cancer prognosis supplementary to that obtained from DNA flow cytometric analysis. [4]

The specificity and simplicity of the argyrophilic nucleolar organizer region staining procedure has led to widespread application of this technique in human pathology. AgNOR analysis is used to determine the prognosis of many oral lesions. Many recent reports have suggested that the number of AgNORs per nucleus is

related to cellular proliferation and differentiation. Thus AgNORs have been used as a diagnostic aid in histological grading as well as a prognostic indicator in various oral lesions. [5]

## MATERIALS AND METHODS

The present study was carried out in the department of oral pathology and microbiology. Archival tissues from paraffin embedded blocks from the department and also recent cases in the dental OPD were considered. The study group consisted ten tissue blocks each of histopathologically confirmed cases of well differentiated (WDSQCC), moderately differentiated (MDSQCC) and poorly differentiated (PDSQCC) oral squamous cell carcinomas. Ten cases of normal mucosa constituted the control group. From each tissue block two sections each of 3-4 micron thickness were obtained. One set of sections were stained with haematoxylin & eosin stain to histologically confirm the diagnosis and the other set of sections were stained with silver staining technique for AgNOR count. The histopathological grading of oral squamous cell carcinomas was done according to Broders grading system. [6]

### Staining technique

The improved method of silver staining technique for nucleolar organizing regions was done according to the standard protocol recommended by Ploton et al in 1986. [7] The sections were dewaxed in xylene for about 3-5 minutes and then rehydrated through decreasing grades of ethanol followed by thorough washing in running deionized water for 8-10 minutes. Ten slides were stained in each batch by incubating them at 40<sup>0</sup>c in dark for 20 minutes. Post stained sections were washed in running deionized water for 5-8 minutes, dehydrated through ascending grades of ethanol concentrations, finally cleared in xylene and mounted in DPX. Lymphocytes present in the connective tissue showing one or two AgNORs were used as the internal control for the staining technique. No

counterstains were used to eliminate the risk of over shadowing the AgNORs.

### Counting of AgNORs

The AgNORs were counted as per the standardized procedure recommended by Crocker et al in 1989. [8] In each of the sections, 100 individual cells were examined from the representative areas of the epithelium. The methodical and systematic quantification of AgNORs was carried out using an oil immersion objective (100x). NORs were distinctly visible as black “dots” or “blebs” of varying size, in the brown stained nucleus on a pale yellow back ground of the cells. By careful focusing, AgNOR dots were counted; both intra nucleolar and extra nucleolar dots were included in the counting regime. However nuclei that are over lapped or those with indiscernible AgNORs were excluded. The photomicrographs were obtained using a research microscope.

### Evaluation of AgNORs

AgNORs were counted in each nucleus and all the values were expressed in terms of mean  $\pm$  Sd. Data obtained was analyzed using, statistical package for social sciences (SPSS) version 16 for windows operating system. ANOVA test was applied and statistical significance between the groups at 95% confidence interval and p value less than 0.05 was considered to be statistically significant.

## RESULTS

Based on the clinical and histopathological correlation, the thirty cases of oral squamous cell carcinomas were divided into three groups of ten each representing well differentiated, moderately differentiated and poorly differentiated. The patients with squamous cell carcinoma in our study were in the age group of the 35-76 years with the mean age of 54 years and there was male predominance with the male to female ratio of 2:1. Documentation of the associated habits and common site of the lesion showed tobacco chewing as the most prevalent cause and buccal mucosa as the most favourable site.

In the present study the mean value of AgNORs was  $2.49 \pm 0.30$  in normal mucosa, whereas mean AgNOR counts were  $6.59 \pm 0.20$ ,  $7.96 \pm 0.22$  and  $8.84 \pm 0.24$  in well differentiated, moderately differentiated and poorly differentiated oral squamous cell carcinomas respectively. A high positive correlation was observed between NORs of various grades of oral squamous cell carcinomas. The mean values of NORs increased as grades increased. The increase in the mean values of NORs was significant in all groups. The increase in mean value of AgNOR count in various grades of oral squamous cell carcinoma was statistically highly significant when compared with the normal mucosa

Table 1: Multiple comparison of AgNORs among different groups

Groups	AgNORs	P-value
Normal mucosa	$2.49 \pm 0.30$	$p < .001$
WDSQCC	$6.59 \pm 0.20$	
MDSQCC	$7.96 \pm 0.22$	
PDSQCC	$8.84 \pm 0.24$	

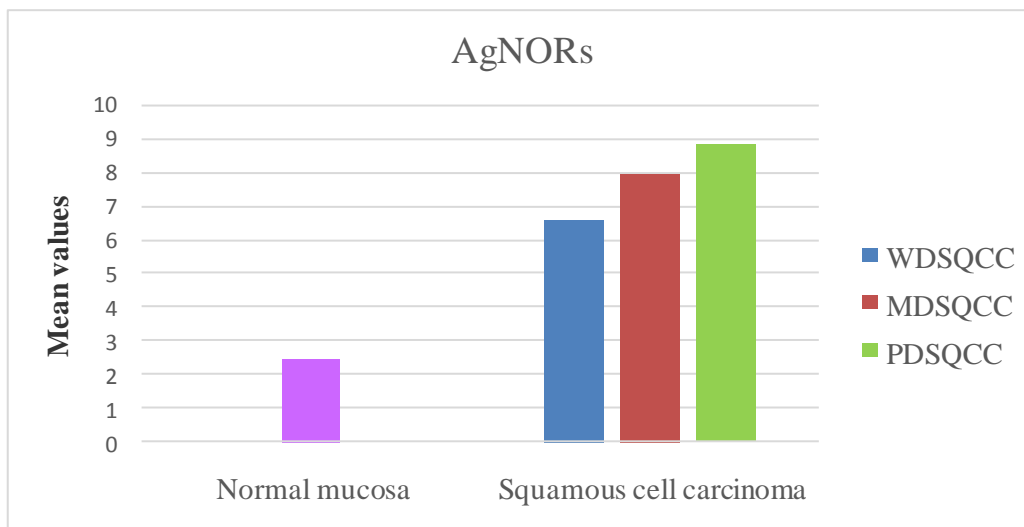
## DISCUSSION

The cellular proliferation is regarded as one of the most important biological mechanisms in carcinogenesis. The assessment of cellular proliferation in histological material is a valuable component of conventional histopathological analysis, and a variety of methods can be used to quantify this. Ideally such methods should be simple, reproducible, and applicable to conventionally processed histological and cytological preparations. The method should be relatively inexpensive and interpretation of the results should be straightforward. In general, a high proliferative activity is associated with poor prognosis. The NOR quantity is strictly related to the rapidity of cell proliferation; higher the NOR quantity, the shorter the cell doubling time. [9]

In the present study the control group consisted of normal mucosa and the mean value of NORs was  $2.49 \pm 0.30$ . This finding is in agreement with various investigators like Cabrini et al in 1992 ( $2.95 \pm 1.42$ ), [10] Rajendran R, Nair SM in

1992 ( $2.50 \pm 0.52$ ) [11] and XinXie et al in 1997 ( $2.3 \pm 0.4$ ). [12] Similarly there was a significant rise in mean AgNOR count of oral squamous cell carcinomas in the order of well differentiated ( $6.59 \pm 0.20$ ), moderately differentiated ( $7.96 \pm 0.22$ ) and poorly differentiated ( $8.84 \pm 0.24$ ). The findings of the present study was similar with the previous study on oral squamous cell carcinomas by Chattopadhaya A et al

(2002) [13] & Sano et al (1991). [14] They opined that the increase in AgNOR count was related to the prognosis of the lesion, which indicates the poor prognosis rate of different grades of oral squamous cell carcinoma as the mean count increases. They suggested that the lesions became less differentiated and more aggressive as the AgNOR count tends to increase.



Graph 1: Showing AgNORs in different grades of squamous cell carcinoma

Hanemann JA et al in 2011 did a study to assess silver-binding nucleolar organizer region in squamous cell carcinoma and to relate the mean count to the histologic grading. The findings of their study showed mean number of AgNORs per nucleus to be 3.20 for the well-differentiated, 5.33 for the moderately differentiated and 8.27 for the poorly differentiated. They concluded that the mean AgNOR counts to be useful for histological grading of squamous cell carcinoma. [15] Similarly Mehkri S et al in 2010 studied the NORs in various differentiation grades of oral squamous cell carcinoma and reported a mean count of  $5.73 \pm 1.62$ ,  $5.67 \pm 1.19$  in well differentiated and moderately differentiated oral squamous cell carcinomas respectively. The authors concluded that oral squamous cell carcinoma with high AgNORs count may have an aggressive character and that high

AgNOR numbers are highly suggestive of poor prognosis of the lesion. [16]

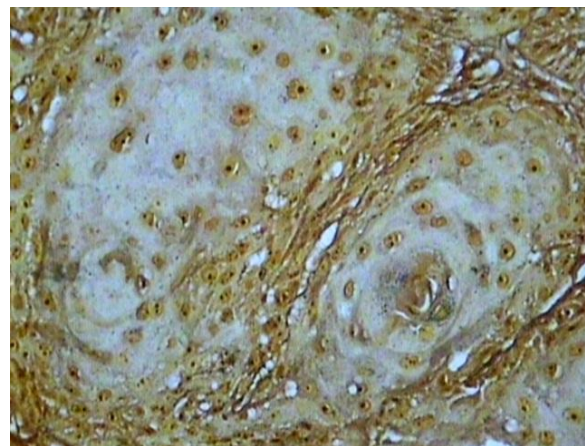


Figure 1: Histopathology showing AgNORs in squamous cell carcinoma (Silver stain,  $\times 400$ )

Chatterjee et al in 1997 assessed AgNORs in oral carcinomas in relation to their differentiation grade, cytokinetics and also progression of disease. In their study the grade III oral squamous cell carcinoma

showed higher AgNOR count. This might well imply that the rapidity of cell proliferation, as assessed by AgNOR quantification, is probably the kinetic parameter which correlates better with the outcome of oral squamous cell carcinoma and the counts are strong prognostic marker for patients with carcinoma. [17]

Since the proliferation changes during the cell cycle reflect the net effect of genetic damage and therefore, include the accumulated changes in genes, they may be regarded as more useful prognostic indicators than individual oncogene alterations. Our own results indicate that the silver nitrate staining for NORs is a useful method for aiding the diagnosis and grading of malignant mucosal lesions. Thus this method can be routinely used along with other laboratory techniques and is also helpful as a prognostic marker.

## CONCLUSION

The field of AgNORs as potential tools for diagnosis, prognosis, comparisons and grading of oral lesions is ripe and vast. A large group of oral lesions still remains to be assessed as to the value of AgNOR significance. While it cannot be said with certainty and conviction that AgNORs are definitively diagnostic or prognostic, it is surely observed that they can serve as a reliable tool adjunct to histopathological diagnosis. Their ease of demonstration and high specificity to cellular proliferation make them the best available histopathological marker in the arsenal of an oral histopathologist.

**Source(s) of support:** Nil

**Presentation at a meeting:** Nil

**Conflicting Interest (If present, give more details):** Nil

## REFERENCES

1. Khanna AK, Yadav SK, Dixit VK, Mohan Kumar. AgNOR Count and objective AgNOR Pattern Assessment (SAPA) score in Carcinoma of the Pancreatic Head including periampullary tumors. *J Pancreas (Online)* 2005;6(6):575-580.

2. SandhyaPanjetaGulia, EmaniSitaramam, Karri Prasada Reddy. The role of silver staining nucleolarorganiser regions (AgNORs) in lesions of the oral cavity. *J ClinDiagn Res* 2011; 5(5):1011-15.
3. AmanChowdhry, RevatiShaileshDeshmukh, Deepika Shukla, Deepika Bablania, Shashwat Mishra. Quantitative estimation of AgNORs in normal, dysplastic and malignant oral mucosa. *Biomed Pap Med FacUnivPalacky Olomouc Czech Repub* 2013;158(2):282-87.
4. Amit Chattopadhaya, JG Chawla, JJ Doshi. Silver binding nucleolar organizer regions: A study of oral leukoplakia and squamous cell carcinoma. *Int J of Oral &MaxfacSurg* 1994;23:374-377.
5. Dinesh V Rajput and Jagdish V Tupkari. Early detection of oral cancer: PAP and AgNOR staining in brush biopsies. *J Oral MaxilloFacPathol* 2010;14(2):52-8.
6. Broders AC. The microscopic grading of cancer. *SurgClin North Am* 1941; 21:947 – 962.
7. Ploton D, Menager M, Jeannesson P, Himber G, Pigeon F, Adnet JJ. Improvement in the staining and in the visualisation of the argyrophilic proteins of the nucleolar organizer region at the optical level. *Histochem J* 1986;18:5-14.
8. Crocker J, Boldy DAR, Egan MJ. How should we count AgNORs? Proposals for a standardised approach. *J Pathol* 1989;158:185-88.
9. Migaldi M, Criscuolo M, Zunarelli E, Bianco LL, Martinelli AM, Barbolini G. p20 and AgNOR nucleolar protein expression: A comparison with nuclear proliferation markers in oral pathology. *Oral Surg Oral Med Oral Pathol Oral RadiolEndod* 1998;85:189-96.
10. Cabrini RL, Schwint AE, Mendez A, Femopase F, Lanfranchi H, Ifoiz ME. Morphometric study of nucleolar organizer regions in human oral normal mucosa, papilloma and squamous cell carcinoma. *J Oral Pathol Med* 1992; 21:275-279.
11. Rajendran R and Nair SM. Silver binding nucleolar organizer region proteins as a possible prognostic indicator in oral submucous fibrosis. *Oral Surg Oral Med Oral Pathol* 1992;74:481-486.
12. Xie X, Clause OP, Sudbo J, Boysen M. Diagnostic and prognostic value of nucleolar organizer regions (AgNORs) in

- normal epithelium, dysplasia, and squamous cell carcinoma of oral cavity. *Cancer* 1997;79(11):2200-8.
13. Chattopadhyay A, Ray JG, Caplan DJ. AgNOR count as objective marker for dysplastic features in oral leukoplakia. *JOPM* 2002;31(9):512-517.
  14. Sano K, Takahashi H, Fujita S. Prognostic implication of silver binging nucleolar organizer regions (AgNORs) in oral squamous cell carcinomas. *J Oral Pathol Med* 1991;20:53-56.
  15. Hanemann JA, Miyazawa M, Souza MS. Histologic grading and nucleolar organizer regions in oral squamous cell carcinomas. *J Appl Oral Sci.* 201;19(3):280-5.
  16. Mehkri S, Iyengar AR, Nagesh KS, Bharati MB. Analysis of cell proliferation rate in Oral Leukoplakia and Oral Squamous Cell Carcinoma. *J ClinExp Dent.* 2010;2(4):e173-7.
  17. Chatterjee R, Mukhopadhyay D, Chakraborty RN, Mitra RB. Evaluation of argyrophilic nucleolar organizer regions (AgNORs) in oral carcinomas in relation to human papillomavirus infection and cytogenetics. *J Oral Pathol Med* 1997; 26: 310–314.

How to cite this article: Girish KL, Sathyan P. Quantitative evaluation of argyrophilic nucleolar organizer regions in different histopathological grades of oral squamous cell carcinoma. *Int J Health Sci Res.* 2018; 8(8):115-120.

\*\*\*\*\*