

Original Research Article

Clinicopathological Correlation in Granulomatous Lymphadenopathy With Emphasis on AFB Negative Cases- Role of FNAC as A Diagnostic Tool in A Tertiary Care Hospital in Industrial Belt of Haryana

Dr. Sujata Raychaudhuri¹, Dr. Nimisha Sharma², Dr. Mukta Pujani¹, Dr. Mitasha Singh³, Dr Charu Agarwal²,
Dr. Kanika Singh², Dr Varsha Chauhan², Dr. Aparna Khandelwal⁴

¹Associate Professor, ²Assistant Professor, ⁴Senior Resident,
Dept. of Pathology, ESIC Medical College and Hospital, Faridabad

³Assistant Professor, Dept. of Community Medicine, ESIC Medical College and Hospital, Faridabad

Corresponding Author: Dr. Nimisha Sharma

ABSTRACT

Fine Needle Aspiration cytology (FNAC) is the first line, rapid diagnostic technique for the initial evaluation of superficial palpable swellings. Tuberculosis is the commonest cause of lymphadenopathy in India. Cytomorphology along with positive acid fast staining plays an important role in diagnosing these cases as tuberculous thus avoiding unnecessary surgeries. The aim is to study the clinicopathological parameters that may be of significance in diagnosing tuberculosis in granulomatous lymphadenopathies which are negative for AFB in Ziehl-Neelsen (ZN) staining in patients and their families who are insured under ESIC scheme in industrial belt of Haryana. This is a retrospective study and a total of 100 patients belonging to all age groups and both sexes, presenting with palpable lymph nodes in our institute over a period of 6 months with diagnosis of granulomatous, suppurative and necrotising lymphadenopathy on FNAC were included in the study. Those cases which were reactive or positive for malignancy were excluded. All the 100 Smears were subjected to Giemsa and Ziehl-Neelsen stain. Cases were categorised as AFB positive and AFB negative with granulomatous and necrotising pathologies and compared with different clinicopathological parameters. Data was entered in excel spread sheet and statistical analysis was done. P value <0.05 was taken to represent significant difference. The study concluded that the patients in 3rd decade with cervical lymphadenopathy having matted nodes or with size greater than 4 cm with blood mixed aspirate over a period of 15 days to 6 months were considered tuberculous although ZN stain for AFB was negative.

Key words: AFB negative, granulomatous, clinicopathological factors, tuberculosis.

INTRODUCTION

Global incidence of TB is 9.4 million and India alone accounts for 1.98 million cases. India contributes to one fifth of TB cases in the world. ^[1] In India TB is the commonest cause of chronic lymph node enlargement comprising of two third of the cases of lymphadenopathy. ^[2,3] The most reliable criterions of demonstrating tuberculosis is by demonstrating AFB by ZN staining, fine needle aspiration cytology(FNAC), polymerase chain reaction

(PCR), or culture from aspirate. As tuberculous lymphadenitis is the most common manifestation of extrapulmonary tuberculosis and in countries like India with high disease burden and with limited resources the presence of epitheloid cell granuloma in FNAC is itself considered as evidence of tuberculous lymphadenitis. ^[4]

FNAC is a simple, sensitive, specific, safe, accurate, repeatable and cost-effective procedure in the diagnosis of lymphadenopathy. ^[5-7] Culture studies are a

gold standard and polymerase chain reaction are very specific, still FNAC plays an important role in the initial diagnosis of TB and institution of therapy in AFB positive cases. [8] It has specificity of 88 to 96 percent [1] for diagnosing TB.

Granulomatous inflammation is not the diagnostic of TB, as many others causes must be ruled out before giving antituberculous treatment (ATT). [9] However, in the clinical scenario in developing countries like India if a patient is diagnosed with granulomatous inflammation, ATT is started at the first point in clinical setup. Granulomas may be confluent or discrete and the degree of necrosis is variable and the cell components may differ. Differential diagnosis based on cytology demands a good interpretation of clinical findings. [10] History and clinical examination are always very helpful. Presence of AFB positivity in granulomatous lymphadenitis confirms the diagnosis of tuberculosis. However, AFB negative cases of granulomatous or necrotising granulomatous lymphadenitis in developing countries are considered as suspected cases of tuberculosis and ATT therapy is instituted.

With this background a descriptive record based study was conducted on 100 patients to study the various cytomorphological pattern of tuberculosis among the insured E.S.I. patients attending the ESIC Medical College and Hospital, Faridabad, Haryana. These were predominantly young patients mainly belonging to the lower socio economic status with poor hygiene and overcrowded dwellings along with low education levels. The analysis was further categorised based on AFB positivity and their cytological features. Further a correlation between clinicopathological parameters and cytomorphological pattern was established.

MATERIALS AND METHODS

Study design: A descriptive record based study was conducted.

Study area: This study was carried out in the Department of Pathology at a tertiary care hospital catering medical services to the industrial population mainly factory workers and their families in Faridabad, Haryana in North India.

Study duration: Records from June through October 2017 (six months) were retrieved.

Study population: 245 cases of benign lymphadenopathy were selected from record of six months. These include all patients presenting with palpable superficial lymphadenopathy or swellings. Out of 245 cases, reactive lymphadenitis was noted in 108 cases, while 37 cases were reported as malignant. The remaining 100 cases included cytological proven cases of granulomatous or necrotising or suppurative lymphadenitis. All the cases which were either positive for AFB on ZN stain morphologically resembling tubercular bacilli or negative for AFB, were included for the study. The records of patients with previous history of Pulmonary Koch's or on anti tubercular treatment or smears with crushed morphology, acellular smears or poorly stained smears were excluded from the study.

Data Collection: Institutional ethical clearance was obtained before the start of this study. Informed consent was taken from the study group before fine needle aspiration procedure. Details such as age, sex, clinical history, duration of symptoms, group of lymph nodes involved, size of the lymph nodes, presence or absence of matting, type of aspirate obtained on FNAC were retrieved from the records. FNAC was performed and reported by trained pathologists and records were sorted and data was retrieved by same group of pathologists.

Data and statistical analysis: Data was entered in Microsoft excel and analysed using Epi info version 7. All the variables were categorical hence presented in form of proportion and numbers. Chi-square was the test of significance applied to test the

difference in proportions. Significance level was set at 5%.

RESULTS

100 cases which were diagnosed as granulomatous lesions, granulomatous lesions with necrosis and only necrosis were subjected to ZN (Ziehl-Neelsen) stain for AFB. Of these 36% was AFB positive. These were cases which were diagnosed as tuberculosis.

AFB negatives cases

The 64% of cases which were AFB negative have been presented using bivariate analysis with various clinical parameters which could be of relevance in diagnosing these lesions as granulomatous

and necrotizing on FNAC. (Table1). Of all the AFB negative cases 85.9% were granulomatous (55/64). Necrosis was observed in 32.8% AFB negative cases (21/64). Necrotizing granulomatous lesions were noted in 44 percent Cases. The age group which showed maximum AFB negative cases with granuloma (27.3%, 15/55) and necrosis (33.3%, 7/21) was the 3rd decade. Majority (90.6%) of males and females (81.3%) with AFB negativity had granulomatous lesion (p=0.47). Necrosis with AFB negativity was observed in relatively lower proportion of males (57.1%) and females (42.9%) as compared to granulomatous lesion (p=0.59).

Table 1: Correlation of clinical parameters in AFB Negative Cases.

AFB Negative	Granuloma		P value	Necrosis		P value
Age	Number	Percentage	0.698	Number	Percentage	0.084
0-10	9/11	81.8		1/11	9.1	
11-20	10/12	83.3		6/12	50	
21-30	15/19	78.9		7/19	36.8	
31-40	10/11	90.9		2/11	18.2	
41-50	9/9	100		3/9	33.3	
51-60	2/2	100		2/2	100	
Sex			0.281			0.424
Male	29/32	90.6		12/32	37.5	
Female	26/32	81.3		9/32	28.1	
Site			0.621			0.158
Cervical	29/35	82.9		11/35	31.4	
supraclavicular	3/3	100		1/3	33.3	
axillary	7/9	77.8		4/9	44.4	
submandibular	8/8	100		0/8	0	
others	8/9	88.9		5/9	55.6	
Size			0.489			0.444
0.5 to 0.5	28/31	90.3		10/31	32.3	
1.6 to 2.5	12/15	80		3/15	20	
>2.6 to 4cm	10/13	76.9		6/13	46.2	
Multiple	4/4	100		2/4	50	
Duration			0.700			0.801
<0.5 month	9/10	90		4/10	40	
0.5 mon to 6 m	27/31	87.1		10/31	32.3	
>6 months	14/16	87.5		4/16	25	
unknown	5/7	71.4		3/7	42.9	
Aspirate			0.261			0.024
Blood mixed	39/43	90.7		11/43	25.6	
Pus	8/10	80		7/10	70	
Clear	8/11	72.7		3/11	27.3	
Symptoms			0.699			0.959
Fever , cough	16/18	88.9		5/18	27.8	
Weight loss, loss of appetite	10/11	90.9		4/11	36.4	
others	3/3	100		1/3	33.3	
swelling	26/32	81.3		11/32	34.4	

All cases with AFB negative supraclavicular and axillary nodes were granulomatous (p=0.61). Half of AFB negative granulomatous lesions were from cervical nodes (50.0%, 27/54). Out of total

AFB negative cases 54.7% (35/64) were from cervical lesions and of these 31.4% (11/35) were necrosed. The 14.1% (9/64) AFB negative cases were from axillary nodes among these 44.4% (4/9) was

necrosed. All multiple and matted LNs which showed AFB negativity presented with granulomas while only 55.6% of these nodes showed necrosis.

All cases with non specific symptoms which were AFB negative presented with granulomas but this was not statistically significant. History of TB contact was observed in 29.7% (19/64) of negative cases and of these 89.5% and 36.8% had granulomatous and necrotic lesions respectively.

AFB positive cases

There were 91.7% (33/36) granulomatous and 72.2% (26/36) necrotic lesions among all positive cases (Table 2). The 3rd decade presented in majority of AFB positive granulomatous lesions (30.3%), while there was an equal

representation from 3rd and 4th decade (23.1% each) in necrotic lesions. Males comprised the majority of positive cases (69.7%). Among the positive cases with majority (58.3%, 21/36) of cervical nodes 85.7% presented with granuloma and 66.7% with necrosis. All the cases with size of nodes greater than 4cm were granulomatous. Majority of cases were necrotic in lymph nodes with size ranging from 2.6 cm to 4cm (87.5%) and 1.6 cm to 2.5 cm (85.7%). Half of the positive cases presented with no complaint or were asymptomatic. (50%). Of these 94.4% (17/18) were granulomatous and 72.2% (13/18) were necrotic. All the aspirates with pus were granulomatous (16/16) while only half (50%, 8/16) were necrotic.

Table 2: Correlation of clinical parameters in AFB Positive Cases.

AFB positive	Granuloma	Percentage	P value	Necrosis	Percentage	P value
Age	Number	Percentage	0.526	Number	Percentage	0.326
0-10	6/8	75%		4/8	50%	
11-20	6/7	85.7%		5/7	71.4%	
21-30	10/10	100%		6/10	60%	
31-40	6/6	100%		6/6	100%	
41-50	2/2	100%		2/2	100%	
51-60	2/2	100%		2/2	100%	
>60	1/1	100%		1/1	100%	
Sex			0.913			0.394
Male	23/25	92%		17/25	68%	
Female	10/11	90.9%		9/11	81.8%	
Site			0.674			0.316
Cervical	18/21	85.7		14/21	66.7%	
supraclavicular	4/4	100		3/4	75%	
axillary	7/7	100		6/7	85.7%	
submandibular	1/1	100		0/1	0	
others	3/3	100		3/3	100%	
Size (cm)			0.301			0.376
0.5 to 0.5	14/17	82.4		10/17	58.8	
1.6 to 2.5	7/7	100		6/7	85.7	
>2.6 to 4cm	8/8	100		7/8	87.5	
multiple	4/4	100		3/4	75%	
Duration			0.772			0.347
<0.5 month	8/8	100		7/8	87.5%	
0.5 mon to 6 m	17/19	89.5		14/19	73.7%	
>6 months	7/8	87.5		4/8	50%	
unknown	1/1	100		1/1	100%	
Aspirate			0.106			0.008
Blood mixed	16/16	100		8/16	50%	
pus	17/20	85		18/20	90%	
Clear fluid	0/0	0		0	0	
Symptoms			0.583			0.901
Fever , cough	12/13	92.3		9/13	69.2	
Weight loss, loss of appetite	4/5	80		4/5	80	
Swelling	17/18	94.4		13/18	72.2	

DISCUSSION

FNAC was first used by Dugeon and Patrick in 1927 to diagnose tuberculous

lymphadenitis. [11] FNAC is used as a diagnostic tool to help in diagnosis of lymph node lesions as it is safe, simple, quick,

inexpensive and reduces the need of surgical biopsy [12] and has relatively no contraindications and side effects.

The causes of lymphadenopathy are diverse ranging from reactive, infections, suppurative pathologies to malignancies which include lymphomas and metastatic carcinomas. [13] Out of 245 cases of benign lymphadenopathies, 100 cases were selected having granulomatous, necrotising granulomatous and suppurative or necrotising pathologies. The majority of rest of the cases was of reactive nature.

In our study there was predominance of males presenting with granulomatous lesion, in both AFB positive (69.4%) and AFB negative (52.7%) cases. This is in accordance with other studies. [5,7,14] The age group effected maximum was the third decade for both the groups (AFB positive and negative) as this age group is the predominant group of young males working in the factories.

The cervical nodes were most commonly affected in both the groups and this also corresponds with other studies. [5,6,13-16] In our study larger and matted lymph nodes showed maximum number of granulomatous cases.

The incidence of tuberculous lymphadenitis from our centre was noted in 36 percent of reported cases which was lower than that noted by Paliwal [17] (55 percent)) and Shweta 56.11%. [18] This could be attributed to the fact that it included mainly the young male factory worker and their families.

Some studies have noted higher incidence of Tuberculosis in enlarged lymph nodes. Jha (63%), Mahajan (54%) etc. [19,20]

Zn stain for AFB positivity was noted in 36 percent cases in our study. Paliwal have reported 71%, [17] Chand et al noted 44.54% cases [21] while Shweta et al noted 21.6% cases [18] and Agarwal et al noted 19.6%. [22] Necrosis was noted in 72.2% (26/36) cases among all AFB positive cases while it was noted in 32.8% of AFB negative cases in our study.

Granulomas without caseation necrosis is also seen in other conditions like leprosy, mycoses and sarcoidosis etc [23] but in India where the incidence of Tuberculosis is very high, finding of epitheloid granuloma is suggestive of tuberculosis unless proved otherwise. [24]

Some eosinophilic structures admixed with necrotic debris in hematoxylin and eosin stained smears of tubercular lymphadenitis were noted by Pandit et al. These on immunoperoxidase staining revealed tubercular antigens. [24] These structures were also present in 25% of cases with epitheloid granulomas and 30% of smears showing necrosis only by Khanna et al although no immunological staining for tuberculosis was done by Khanna. [25] In those cases with only necrosis with no granulomas and no AFB positivity these structures are helpful in diagnosing tuberculosis. [26] This characteristic necrotic background consisting of eosinophilic granular material containing nuclear debris is referred to as tubercular diathesis. Paul et al considered necrotic smears which were negative for AFB with no granulomas as tuberculous based on this tubercular diathesis. [18]

In the present study diagnosis of tubercular lymphadenitis was suggested based on the tubercular diathesis (7.8% per cent of cases) with clinical correlation in smears which were negative for granuloma and AFB. (Figures)

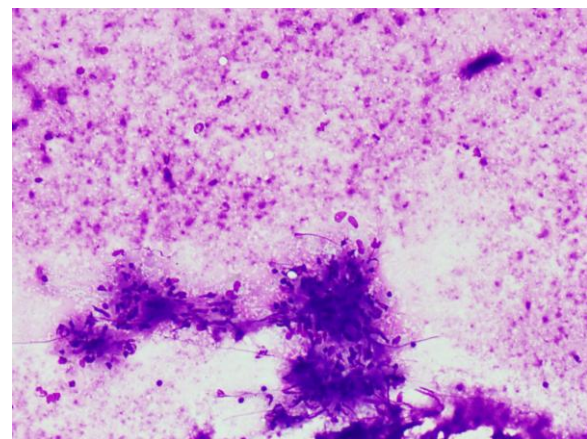


Fig 1 : Photomicrograph showing necrotising granulomatous lymphadenitis MGG 10 X

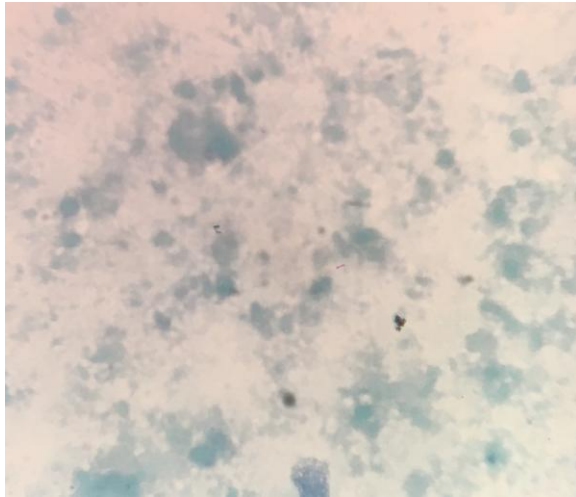


Fig 2: Photomicrograph showing AFB positivity MGG 100X

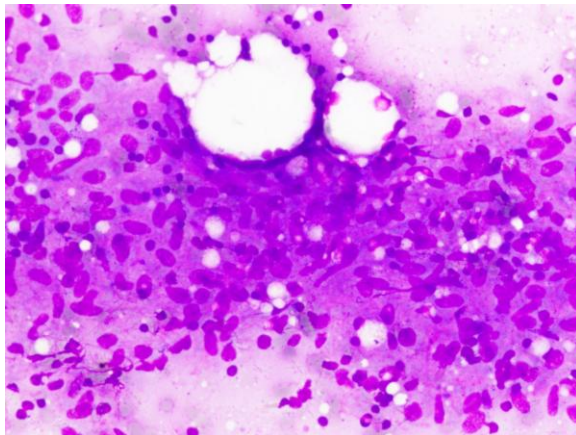


Fig 3: Photomicrograph showing well formed epithelioid granuloma MGG 20 X

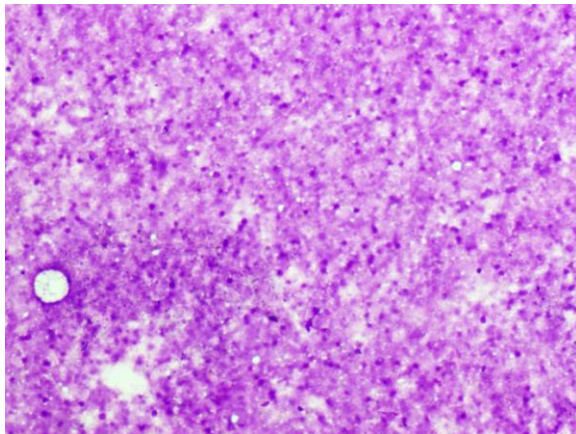


Fig 4: Photomicrograph showing necrosis MGG 10X

Granulomatous pathology accounted for 88% of all cases (Figure 1) and 47% (Figure 2) with necrosis. There were 91.7% granulomatous and 72.2% necrotic lesions among all positive cases. Of all the AFB negative cases 85.9% were granulomatous. It is due to the fact that abundant necrosis is seen in immunocompromised patients

which lead to greater AFB positivity. In patients with good immune response there are more number of granulomas and lesser necrosis and less AFB positivity.

CONCLUSION

The study concluded that although AFB positivity is the criterion to diagnose tuberculosis but AFB negativity in granulomatous lesions with or without necrosis does not rule out tuberculosis. The cases with no granulomas and AFB negativity, the presence of tubercular diathesis plays an important role in diagnosing tuberculosis microscopically. The diagnosis of tuberculosis clinically is aided with certain clinicopathological parameters which help to identify cases as highly suspicion of tuberculosis presenting with granulomatous and necrotising lymphadenitis. The parameters included are patients presenting with swelling in the cervical region over a period of 15 days to 6 months duration with blood mixed aspirate and size greater than 4 cm or more or with matted nodes. The age group with maximum predominance was the third decade. These parameters might be of help in diagnosing tuberculosis in AFB negative cases. This is a pilot study and it can be extended to larger number of patients in all tertiary care and corporate hospitals to highlight the significance of clinical parameters in AFB negative cases of granulomatous or necrotising granulomatous lymphadenitis or lesions.

REFERENCES

1. A Hemalatha, PS Shruti, M Udaya Kumar, and A Bhaskaran. Cytomorphological Patterns of Tubercular Lymphadenitis Revisited. *Ann Med Health Sci Res.* 2014 May-Jun; 4(3): 393–396.
2. Shrivastav A, Shah HA, Shrivastav G, Santwani PM; Utility of acid- fast staining and re- aspiration in tubercular lymphadenopathy- 3 year study at tertiary centre. *Int J Med Sci Public Health*, 2013; 2:875-9.
3. Laishram RS, Devi RKB, Konjengbam R, Devi RKT, Sharma LD; Aspiration cytology for the diagnosis of tuberculous lymphadenitis: A five-year study. *J Indian Acad Clin Med*, 2010;11:31-5.

4. Mohapatra PR, Janmeja AK; Tuberculous lymphadenitis. *J Assoc Physicians India*, 2009;57:585-90.
5. Hirachand S, Lakhey M, Akhter J, Thapa B. Evaluation of fine needle aspiration cytology of lymph nodes in Kathmandu Medical College, Teaching Hospital. *Kathmandu University Medical Journal*. 2007; 7:139-42.
6. Zim SC, Chai SJ, Suh CH. Squamous cell carcinoma arising in mature cystic teratoma of ovary. *Patholog Int Journal*. 1998; 48(10): 834-9.
7. Pandav AB, Patil PP, Lanjewar N. Cervical lymphadenopathy-diagnosis by F.N.A.C., a study of 219 cases. *Asian J Med Res*. 2012; 1(3): 79-83.
8. Corbett EL, Watt CJ, Walker N, Maher D, Williams BG, Raviglione MC, et al. The growing burden of tuberculosis: Global trends and interactions with the HIV epidemic. *Arch Intern Med*. 2003;163: 1009–21.
9. Mudassar et al. Evaluation for Granulomatous Inflammation on Fine Needle Aspiration Cytology Using Special Stains *Pathology Research International*. 2011;1-8
10. Vimal Chander R,P. Jayaganesh P, Reddy T P, Srinivasan C. Spectrum of granulomatous lesions in tertiary care hospital. *Ind J of Path and Onco*, 2016;3(4);611-616
11. Singh JP, Chaturvedi NK, Das A; Role of Fine needle aspiration cytology in the diagnosis of tuberculous lymphadenitis. *Indian J Pathol Microbiol*, 1989;32:100-4.
12. Fatima S, Arshad S, Ahmed Z, Hasan SH; Spectrum of cytological findings in patients with Neck lymphadenopathy- Experience in a tertiary hospital in Pakistan. *Asian Pacific J Cancer Prev*, 2011;12:1873-5.
13. Manas Madan, Puneet Kaur, Mridu Manjari & Manisha Sharma. FNAC as a Diagnostic Tool in the Evaluation of Lymphadenopathy- A Tertiary Hospital Experience. *Global Journal of Medical Research: C Microbiology and Pathology*, 2014 ;14 (7) : 43-47
14. Qasmi SA, Kiani F, Malik AI, Salamatullah J, Farooq MO, Abassi MA. Cervical lymphadenopathy: a common diagnostic dilemma. *Journal of Surgery Pakistan (International)*. 2012; 17(2): 76-80.
15. Satyanarayana S, Kalghatgi AT, Muralidhar A, Prasad RS, Jawed KZ, Trehan A. Fine needle aspiration cytology of lymph nodes in HIV infected patients. 2001;58(1):33-37.
16. Malakar D, Jajoo ILN, Swarup K, Gupta OP, Jain AP, Poflee VW. A Clinical Evaluation of Fine Needle Aspiration Cytology in the Diagnosis of Lymphadenopath. *Ind J Tub*. 1991; 38: 17-19.
17. Paliwal N, Thakur S, Mullick S, Gupta K; FNAC in Tuberculous lymphadenitis: Experience from a Tertiary Level Referral Centre. *Indian J Tuberc*, 2011;58:102-7
18. Rana S, Sharma P, Kalhan S, Singh P, Gill M K, Kumar A. Cytomorphological patterns of tuberculous lymphadenitis: Experience from a tertiary Centre in Rural Haryana. *Sch.J.App.Med.Sci.*,2015;3(3G):1547-1552
19. Jha BC, Dass A, Nagarkar NM, Gupta R, Singhal S; Cervical tuberculous lymphadenopathy: Changing clinical pattern and concepts in management. *Postgrad Med J*, 2001;77(905):185187.
20. Mahajan M, Hirachand S, Kafle PK, Bista M, Shrestha S, Toran KC et al.; Incidence of tuberculosis in enlarged neck nodes, our experience. *Kathmandu University Medical Journal*, 2009;7(1):54-58.
21. Chand P, Dogra R, Chauhan N, Gupta R, Khare P; Cytological pattern of Tubercular lymphadenopathy on FNAC: Analysis of 550 consecutive cases. *JCDR*, 2014;8(9):16-19.
22. Aggarwal P, Wali JP, Singh S, Handa R, Wig N, Biswas A. A clinico bacterial study of Peripheral Tuberculous Lymphadenitis. *J Assoc. Physicians India* 2001;49:808-12.
23. Koss LG, Woyke S, Olszewski W. Aspiration biopsy: Cytologic interpretation and Histologic bases. 2nd ed. New York: Igaku- Shoin; 1992.p.203-30.
24. Pandit AA, Khilnani PH, Prayag AS. Tuberculous lymphadenitis: extended cytomorphologic features. *Diagn Cytopathol*1995;12:23-27
25. Khanna A, Khanna M, Manjari M. Cytomorphological patterns in the diagnosis of tuberculous Lymphadenitis. *Int J Med and Dent Sci* 2013;2(2):182-188.
26. Paul PC, Goswami BK, Chakrabarti S, Giri A, Prannik R. Fine needle aspiration cytology of lymph nodes- An institutional study of 1448 cases over a five year period. *J of Cytology* 2004;21:18790. 34

How to cite this article: Raychaudhuri S, Sharma N, Pujani M et.al. Clinicopathological correlation in Granulomatous lymphadenopathy with emphasis on AFB negative cases- role of FNAC as a diagnostic tool in a tertiary care hospital in industrial belt of Haryana. *Int J Health Sci Res*. 2018; 8(10):44-50.
