

Case Report

# Aggressive Fibromatosis of the Chest Wall Mimicking Low Grade Fibrosarcoma - An Unusual Clinical Presentation

Dr. Nimisha Sharma<sup>1\*</sup>, Dr. Sumanashree Mallappa<sup>2\*\*</sup>,  
Dr. Sujata Raychaudhuri<sup>3\*</sup>, Dr Amit Yadav<sup>3\*\*</sup>, Prof. Dr. A. K. Mandal<sup>4\*\*</sup>

<sup>1</sup>Assistant Professor, <sup>2</sup>Senior Resident, <sup>3</sup>Associate Professor, <sup>4</sup>Director Professor,

<sup>\*</sup>Dept. of Pathology, ESIC Medical College and Hospital, Faridabad

<sup>\*\*</sup>Dept. of Pathology, VMMC and Safdarjung Hospital, New Delhi

Corresponding Author: Dr. Nimisha Sharma

## ABSTRACT

**Background:** Aggressive fibromatosis (AF), also known as desmoid tumour or musculoaponeurotic fibromatosis is a monoclonal fibroblastic proliferative disease. It can present as abdominal and extra-abdominal fibromatosis. Extra abdominal deep fibromatosis represent 3.5% of fibrous tissue tumor and 0.03% of all neoplasms. Anterior chest wall forms 10% of Extra abdominal deep fibromatosis cases.

**Case history:** Patient presented with a progressively increasing large swelling on the chest wall since 2 years. On examination, firm to hard ill defined growth was found. Microscopic examination showed a cellular spindle cell tumour. Strong positivity for VIMENTIN and focal positivity for SMA and DESMIN was seen on Immunohistochemistry. Final Diagnosis of aggressive fibromatosis was made.

**Conclusion:** This case is being presented for its rarity, unusual clinical presentation and overlapping clinical and histopathological features with fibrosarcoma, which is a malignant entity.

**Key Words:** Aggressive fibromatosis (AF), desmoid tumour, fibrosarcoma.

## INTRODUCTION

Aggressive fibromatosis also known as Desmoid tumours are a rare group of locally aggressive, nonmalignant tumours of fibroblastic origin that can lead to significant morbidity due to local invasion and may even result in a fatal outcome when located around vital organ. <sup>[1]</sup> The term desmoids tumor was first used in 1838 by Muller, extracted the word “Desmo”, which means tendon like in Greek <sup>[2]</sup> The tumours are composed of spindle-shaped cells placed in a collagenous matrix without alterations, which is typical of malignancy. AF grows slowly and never metastasises; however, local recurrence and adjacent organ involvement are important causes of morbidity and mortality. <sup>[3]</sup> Its annual incidence is 0.2-0.5/100000, and constitutes

less than 4% of all soft tissue tumors. <sup>[4]</sup> The histopathologic differentiation between aggressive fibromatosis and other closely related spindle cell lesions like fibrosarcoma, neurofibroma, nodular fasciitis, fibrous histiocytoma and infantile myofibromatosis are a challenge to the pathologists as it requires expertise to differentiate the finer details. But the major challenge in dealing with the lesions of fibromatosis is to avoid an over diagnosis of fibrosarcoma and an under diagnosis of reactive fibrosis.

## CASE PRESENTATION

We present the case of a 29-year-old male presented with a progressively increasing large swelling measuring 6cmx4cm on the chest wall since 2 years.

Physical examination revealed ill defined growth which is firm to hard in consistency. X-ray and CT showed an infiltrative soft tissue tumour with areas of calcification. Clinical diagnosis of soft tissue sarcoma was made. Gross Examination revealed poorly defined margins with cut surface showing glistening white, poorly circumscribed, fasciculated appearance. Microscopic examination showed a cellular spindle cell tumour. The spindle cells showed mild to moderate pleomorphism, reduced cytoplasm merging with surrounding collagen. Nucleus shows well defined nuclear membrane with opened up chromatin. Few giant cells were seen. Mitotic activity was low (1-2/10 hpf) in the tumour. Thin walled, non branching vessels are seen. The tumour was seen infiltrating into skeletal muscle. No evidence of necrosis was seen. No well defined capsule or border was seen.

**Immunohistochemistry:** Strong positivity for Vimentin was observed. Focal positivity for SMA and Desmin was seen. The streptavidin biotin peroxidase complex immunohistochemical technique was used. Based on the above findings final diagnosis of aggressive fibromatosis was made.

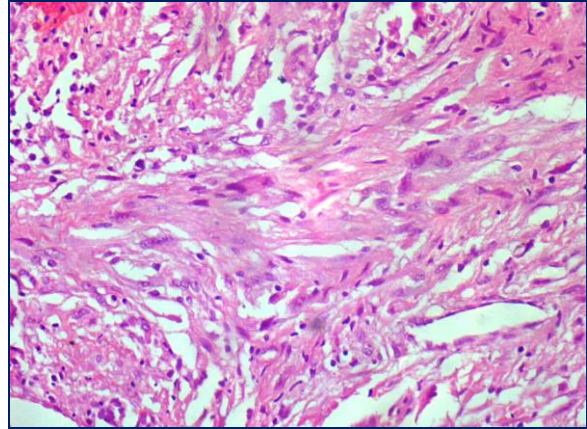


Figure 2: Cells are spindled or stellate in shape and have bland nuclear features. Extensive keloid-like collagen deposition

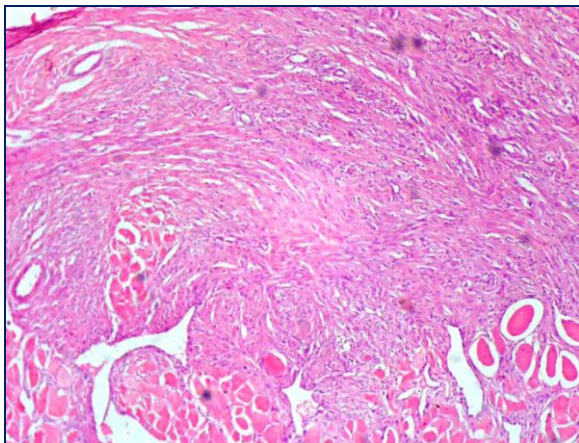


Figure 1: Cellular proliferation of bland spindled cells arranged into ill defined long fascicles. Irregular infiltration into skeletal muscle.

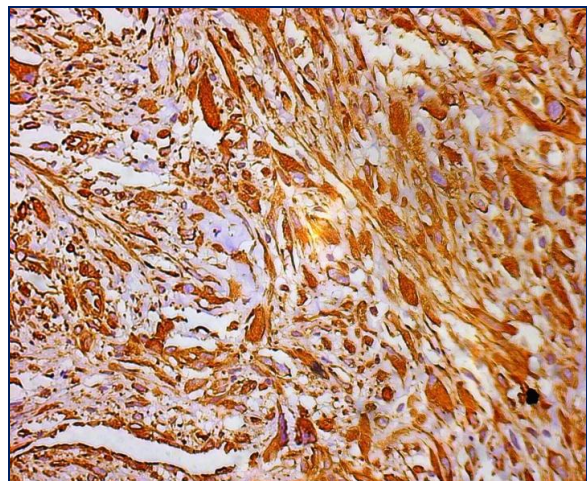


Figure 3: Cells strongly express VIMENTIN

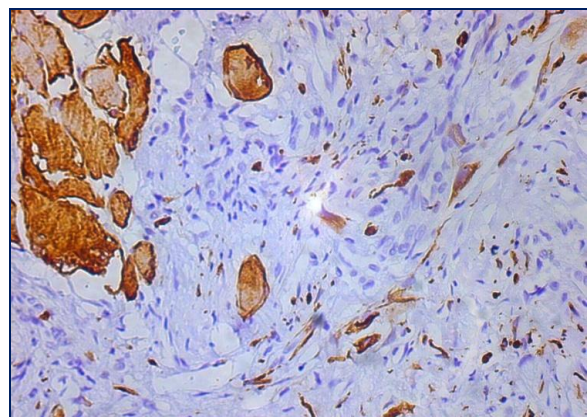
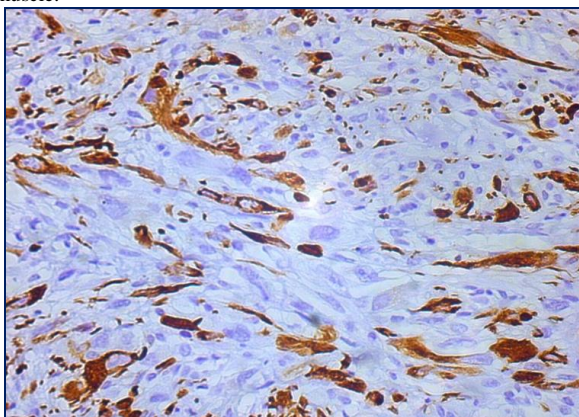


Figure 4,5: SMA & DESMIN shows focal positivity



## DISCUSSION

Aggressive fibromatosis is also known as musculoaponeurotic fibromatosis or desmoid tumour. Deep fibromatosis are rarer than their superficial counterparts. Extra abdominal Deep fibromatosis represent 3.5% of fibrous tissue tumor and 0.03% of all neoplasms. [5] Common extra abdominal sites are shoulder, chest wall, back, thigh and head and neck. Anterior chest wall forms 10% of Extra abdominal deep fibromatosis cases. It arises as a deep-seated, firm, poorly circumscribed mass, grows insidiously and causes little or no pain. [6,7,13] Aggressive fibromatosis is characterised by slow progression, local invasion and post op recurrence but no metastasis is seen. [8,13]

Differential diagnosis is low grade fibrosarcoma, nodular fasciitis, myxofibrosarcoma, neurofibroma,

schwannoma. Fibromatoses are non-metastasizing but may exhibit both rapid growth and visceral involvement. Spontaneous regression has been described but rare tumors mimic a malignancy in their tendency to occur locally. [9] Pathologically, fibromatosis has a deceptively bland appearance. It is however associated with an infiltrative growth pattern that results in difficulty in complete excision and propensity for recurrence. [10] Clinical differentiation of desmoids from malignant tumors may be difficult in view of the local invasive growth of the former. This case is being presented to make pathologists aware of this comparatively rare entity which may mimic low grade fibrosarcoma. Points of differentiation between aggressive fibromatosis and low grade fibrosarcoma are: [11,12]

EXTRA ABDOMINAL FIBROMATOSIS	LOW GRADE FIBROSARCOMA
Mild to moderate cellularity, rarely necrotic	Usually more cellular, frequent necrosis
Small, pale-staining nuclei with 1 to 3 minute nucleoli and clumped chromatin	Larger more hyperchromatic nuclei showing fine chromatin
Rarely >5 mitotic figures/hpf	>5 mitotic figure/hpf

Fibromatosis has a more uniform growth pattern, more mature cells and a paucity of mitosis compared with fibrosarcoma. The grade I fibrosarcoma is usually discernable from fibromatosis by the presence of occasional larger nuclei with ominous chromatin clumping, greater cellularity, greater mitotic activity and thin rather than thick collagen bundles. Mitotic figures are rare and the finding of more than one mitotic figure per high power field or atypical mitotic figures should raise the suspicion of fibrosarcoma. [11] Immunohistochemistry is of little help in differential diagnosis because positive immunostaining against vimentin can be observed in all fibrous connective tissue tumors. [12]

## CONCLUSION

This case is being presented for its rarity, unusual clinical presentation and overlapping clinical and histopathological

features with fibrosarcoma, which is a malignant entity.

## REFERENCES

1. MacFarlane J. Clinical reports on the surgical practice of Glasgow Royal Infirmary. Glasgow: D. Robertson. 1832. pp. 63-66.
2. Kallam AR, Ramakrishna BV, Roy GK, Karthik KRV. Desmoid tumours: our experience of six cases and review of literature. J ClinDiag Res 2014;8: NE01-NE04
3. Bonvalot S et al (2012) The treatment of desmoids tumors: a stepwise clinical approach Ann Oncol 23 (Suppl 10) 158–66 DOI: 10.1093/annonc/mds298
4. Mitchell G, Thomas JM, Harmer CL. Aggressive fibromatosis: evidence for a stable phase. Sarcoma 1998;2:149-154.
5. Ibrahim M, Sandogji H, Allam A. Huge intrathoracic desmoids tumor. Ann Thorac Med 2009;4:146-8.
6. Lewis JJ, Boland PJ, Leung DH, Woodruff JM, Brennan MF. The

- enigma of desmoid tumours. *Ann Surg.* 1999;229:866-72.
7. Bruce JM, Bradley EL 3rd, Satchidanand SK. A desmoid tumour of the pancreas. Sporadic intra-abdominal desmoids revisited. *Int J Pancreatol.* 1996;19:197-203.
  8. El-Haddad M1, El-Sebaie M, Ahmad R, Khalil E, Shahin M, Pant R, Memon M, Al-Hebshi A, Khafaga Y, Al-Shabanah M, Allam A. Treatment of aggressive fibromatosis: the experience of a single institution. *Clin Oncol (R Coll Radiol)* 2009;21:775-80
  9. Baerg J, Murphy JJ, Magee JF. Fibromatosis: Clinical and pathological features suggestive of recurrence. *J Pediatr Surg.* 1999;34:1112-44.
  10. Tse GM, Chan KF, Ahuja AT, King AD, Pang PCW, To EWH. Fibromatosis of the head and neck region. *Otolaryngol Head Neck Surg.* 2001;125:516-9
  11. Vally IM, Altini M. Fibromatosis of the oral and paraoral soft tissue and jaws- Review of literature and report of 12 new cases. *Oral Surg Oral Med Oral Pathol.* 1990;69:191-8.
  12. Seper L, Burger H, Vormoor J, Joos U, Kleinheinz J. Aggressive fibromatosis involving the mandible - Case Report and review of literature. *Oral Surg Oral Med Oral Pathol Oral Radiol Endod.* 2005;99:30-
  13. Enzinger FM, Weiss SW. Soft tissue tumors. 2nd ed. New Delhi: B.I Publication Pvt. Ltd; 1988. Malignant fibrous Histiocytic Tumors; pp. 357-9.

How to cite this article: Sharma N, Mallappa S, Raychaudhuri S et al. Aggressive fibromatosis of the chest wall mimicking low grade fibrosarcoma - an unusual clinical presentation. *Int J Health Sci Res.* 2017; 7(8):499-502.

\*\*\*\*\*