
Case Report

Cyodiagnosis of Idiopathic Calcinosis Cutis - A Rare Diagnosis in Three Cases with Review of Literature

Dr. Rachana Binayke¹, Dr. R.V.Taksande²

¹Assistant Professor, ²Associate Professor,
Grant Government Medical College, Mumbai- 400008

Corresponding Author: Dr. Rachana Binayke

ABSTRACT

Calcinosis cutis is a rare soft tissue lesion characterized by the deposition of calcium salts. There are varied clinical settings attributed to calcium deposition and these can be subjected to fine-needle aspiration (FNA). Since cutaneous calcific deposits may clinically mimic a tumor, it is advisable to diagnose them by FNA cytology (FNAC) which is a rapid, reliable and simple procedure. We reported three cases of idiopathic calcinosis cutis by FNA. Cytological finding of amorphous granular material consistent with calcium salts and the appropriate clinical background led to the cyodiagnosis of idiopathic calcinosis cutis further confirmed by special stains on cytosmears in all the three cases. Points of concern for a correct interpretation of the cytological findings along with review of literature are also discussed.

Key words: Calcinosis cutis, idiopathic, fine needle aspiration cytology

INTRODUCTION

Calcinosis cutis, initially described by Virchow in 1855 refers to a group of disorders characterized by deposition of calcium salts in the skin. Calcinosis cutis is classified into four major types according to etiology - dystrophic, metastatic, iatrogenic, and idiopathic. [1] Family history, history of trauma or injection, tropical or subtropical residence, number and location of calcium deposits, serum calcium and phosphate level, and autoimmune screening are to be evaluated for the appropriate classification of a case. [2]

Idiopathic calcification occurs without any underlying tissue damage or metabolic disorder. [1] We present a case study including three cases of idiopathic calcinosis cutis diagnosed on fine needle aspiration (FNA) cytology. All patients

presented with a painless hard swelling. Cytological finding of amorphous granular material consistent with calcium salts and the appropriate clinical background led to the cyodiagnosis of idiopathic calcinosis cutis in all three cases further confirmed by special stains on cytosmears in an otherwise healthy patient. This study is aimed to raise doctors' awareness of the presentation, etiopathogenesis, and the course of the relatively rare iatrogenic calcinosis cutis and possible confirmation of diagnosis by fine needle aspiration cytology. This study also highlights the points of caution for a correct interpretation of the cytological findings.

CASE SUMMARY

Case 1: A 45-year-old female presented with a solitary painless slowly growing hard swelling in right lumbar region for the last

three years. The nodule was located subcutaneously and measured 3.5x1 cm with chalky white granular discharge through the punctum. (Fig 1 and 2)It was hard to palpate with no connection with the underlying bone. Radiological survey showed a calcified mass in the subcutaneous plain not attached to the underlying bone. (Fig 3)

Case 2; A 28-year old female presented with a swelling over the posterior aspect of right thigh since one year. Ultrasonography showed a 2.5x2 cm calcific lesion in the subcutaneous tissue.

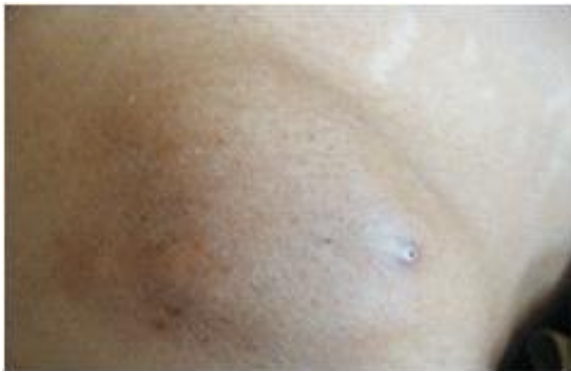

Fig 1: Case 1 showing a hard swelling in right lumbar region located subcutaneously and measured 3.5x1 cm .

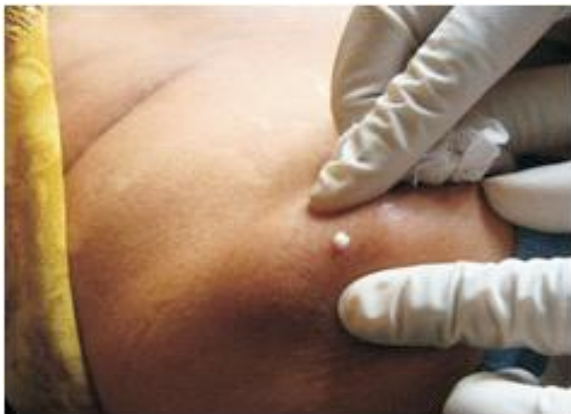

Fig 2: Case 1 showing chalky white granular discharge through the punctum

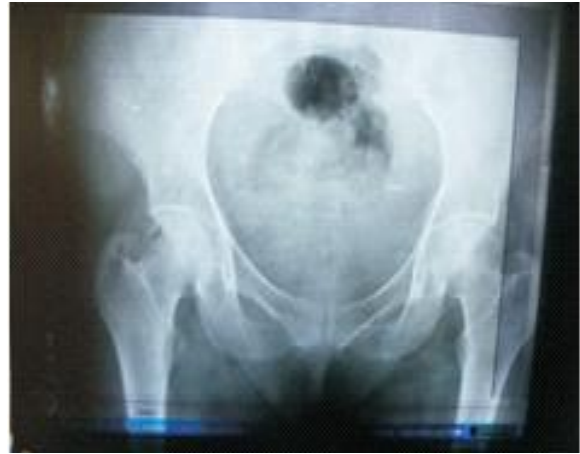

Fig 3: Case 1 X-Ray showed a calcified mass in the subcutaneous plain not attached to the underlying bone.

Case 3:25 year old female came with a swelling over the left gluteal region since one year. On examination a 1x1 cm firm, mobile, non tender swelling was palpable.

In all the above cases there was no history of trauma or parenteral therapy or family history of similar lesions. The patients had no other swelling or cutaneous lesions. Clinically, there was no evidence of any inherited or connective tissue disorder. All biochemical and hematological investigations including serum calcium and phosphorus were within normal limits. Fine needle aspiration of all the three swellings was performed and yielded chalky white granular material. (Fig 4) Hematoxylin and Eosin stained cytosmears showed paucicellularity and crystalloid pinkish granular background (Fig 5).Giemsa stain showed bluish amorphous granular material (Fig 6) and Papanicolaou stained smears (Fig 7) revealed amorphous granular material staining bluish confirming the presence of calcium deposits. Based on these cytological findings, a diagnosis of calcinosis cutis was provided.



Fig 4: FNA yielded chalky white granular material.

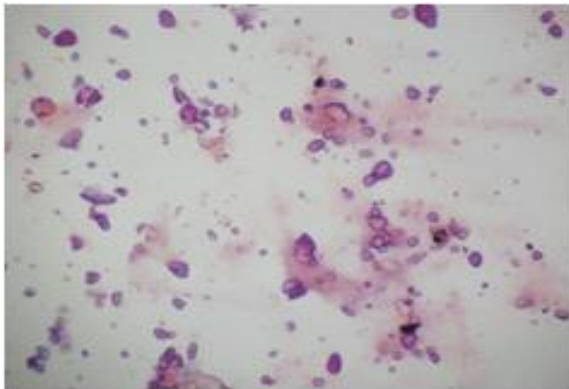


Fig 5: cytospin smears showed paucicellularity and crystalloid pinkish granular background. (H & E X100).

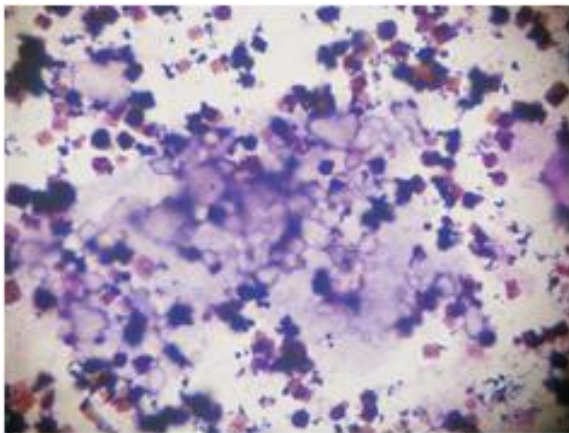


Fig 6: Giemsa stain showed bluish amorphous granular material (X100)

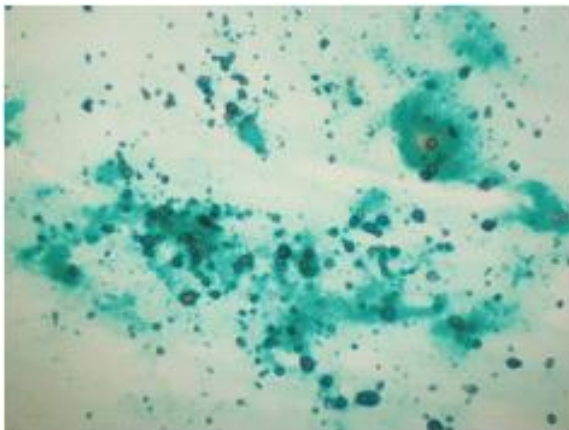


Fig 7: Papanicolaou stained smears revealed amorphous granular material staining Bluish (X100)

DISCUSSION

Calcinosis cutis is a cutaneous condition characterized by localized and organized deposition of calcium in the skin first described by Virchow in 1855. Depending upon the etiopathogenesis various types of calcinosis cutis have been described such as dystrophic, metastatic, iatrogenic, idiopathic and calciphylaxis. [3] It is very important to identify the exact type of calcinosis so that an accurate treatment can be started for the effective management of the disease. Most lesions of calcinosis cutis that develop gradually are asymptomatic.

However, the history and evolution of the lesions depend on the etiology of the calcification. The patients with dystrophic calcification may provide a history of an underlying disease, a preexisting dermal nodule (which represents a tumor), or an inciting traumatic event. The patients with metastatic calcification most frequently have a history of chronic renal failure. Serum calcium and phosphate levels remain normal in dystrophic calcification whereas it is abnormal in metastatic calcification. The cases of idiopathic calcinosis cutis are usually not associated with previous trauma or disease. Those who develop iatrogenic calcinosis cutis generally have a history of recent hospitalization. [4] Calciphylaxis is associated with small vessel calcification in the dermis and subcutaneous fat causing infarction and there may be associated hyperparathyroidism and disturbances in the phosphate and calcium metabolism. [1] Deshpande *et al.* diagnosed a case of calcinosis cutis in a 20-year-old male who presented with a solitary subcutaneous nodule near the ankle, as found on the lateral malleolus by FNA. [5]

Shivkumar *et al.* studied the cytological features of idiopathic scrotal calcinosis and noted the presence of intense, basophilic, amorphous, and granular deposits surrounded by lymphocytes, histiocytes, and foreign body giant cells

without any evidence of epithelial cells in the smears.^[6] The idiopathic calcinosis term is used in the absence of any identifiable cause of tissue calcification. In the present cases, a negative history of trauma and parenteral therapy or any preceding pathological lesion at the site, along with normal serum calcium and phosphorus levels clearly excluded the possibility of dystrophic, iatrogenic and metastatic causes.

The exact pathogenesis of idiopathic calcinosis cutis is still unknown. The final step of calcification is the formation of crystalline and insoluble calcium phosphate mineral, in the form of hydroxyapatite. In the present case, all the investigations to evaluate abnormal calcium metabolism (serum calcium, serum phosphorus, and serum alkaline phosphatase) revealed results within normal limits and we made the diagnosis of calcinosis cutis on fine needle aspiration cytology based on similar cytological findings.

FNA samples yielding abundant calcium require careful consideration of certain entities that include calcified fibrous pseudo tumor, calcified epidermal cyst, sarcoidosis, tuberculosis, lymphoepithelial lesion, pilomatricoma, osteitis fibrosa cystica, and extra skeletal osteosarcoma in the differential diagnosis.^[7] A calcified fibrous pseudo tumor shows abundant hyalinised collagen, fat, and neurovascular bundles along with calcification^[8] Calcified tuberculosis and sarcoidosis show a granulomatous reaction,^[9] whereas calcified epidermal cyst shows anucleate and nucleate squames. Pilomatricoma shows basaloid cells, ghost cells, and multinucleated giant cells in addition to calcification.^[10] Lymphoepithelial lesions show a polymorphous population of lymphoid cells along with histiocytes and calcification.^[11] Absence of any tumor cells rule out extra skeletal osteosarcoma. The clinical evaluation helps in the exclusion of osteitis fibrosa cystica. Reiter et al reviewed various conditions that may lead to skin calcification and provided information regarding laboratory tests required to

differentiate various types of calcinosis cutis.^[1]

The treatment for small calcified deposits and large localized lesions is surgical excision which is curative and also allows histopathological examination that is required for confirmation of the diagnosis, whereas systemic therapy is required for disseminated and extended calcinosis. Various reported treatment modalities with beneficial effects include warfarin, bisphosphonates, minocycline, ceftriaxone, diltiazem, aluminum hydroxide, probenecid, intralesional corticosteroids, intravenous immunoglobulins, curettage, carbon dioxide laser, and extracorporeal shock wave lithotripsy.^[12] Till date, there are very few case reports on FNA cytology of idiopathic calcinosis cutis^[13-15] which if properly interpreted can lead to correct cytodiagnosis of this disorder. The technique is of great diagnostic importance in determining cases requiring medical rather than surgical treatment.

CONCLUSION

The fine needle aspiration procedure is a simple, rapid and reliable technique especially in soft tissue lesions such as calcinosis cutis and if performed and diagnosed with accuracy can eliminate the need for more complicated invasive procedures since clinically it can mimic malignancy.

Financial support and sponsorship - Nil.

Conflicts of interest - There are no conflicts of interest.

REFERENCES

1. Reiter N, El-Shabrawi L, Leinweber B, Berghold A, Aberer E. Calcinosis cutis: Part I. Diagnostic pathway. *J Am Acad Dermatol.* 2011;65:1-14
2. Datta C, Bandyopadhyay D, Bhattacharyya S, Ghosh S. Tumoral calcinosis. *Indian J Dermatol Venereol Leprol* 2005;71:293-4.
3. Valdatta L, Buoro M, Thione A, Mortarino C, Tuinder S, Fidanza C, Dainese E. Idiopathic circumscripta

- calcinosis cutis of the knee. *Dermatol Surg.* 2003;29:1222-4.
4. Sawke GK, Rai T, Sawke N. Iatrogenic calcinosis cutis: A rare cytological diagnosis. *J Cytol*2016;33:166-8
 5. Deshpande A, Munshi M. Calcinosis cutis: Diagnosis by aspiration cytology - A case report *Diagn Cytopathol* 1999; 21:200-2.
 6. Shivkumar VB, Gangane N, Kishore S, Sharma S. Cytological features of idiopathic scrotalcalcinosis. *ActaCytol* 2003;47:110-1.
 7. Monisha Choudhury, KiranAgarwal, Smitasingh et al. Cytodiagnosis of Idiopathic Calcinosis Cutis: A Case Report. *Turkish Journal Of Pathology* 2015;31(2):145-147
 8. Fetsch JF, Montgomery EA, Meis JM. Calcifying fibrous pseudotumor. *Am J Surg Pathol.*1993;17:502-8.
 9. Pérez-Guillermo M, Sola Perez J, Espinosa Parra FJ. Asteroid bodies and calcium oxalate crystals: Two infrequent findings in fine-needle aspirates of parotid sarcoidosis. *Diagn Cytopathol.* 1992;8:248-52.
 10. Unger P, Watson C, Phelps RG, Danque P, Bernard P. Fine needle aspiration cytology of pilomatrixoma (calcifying epithelioma of Malherbe): Report of a case. *ActaCytol.* PAGE 10 1990;34:847-50.
 11. Gunhan O, Celasun B, Dogan N, Onder T, Pabuscu Y, Finci R. Fine needle aspiration cytologic findings in a benign lymphoepithelial lesion with microcalcifications: A case report. *ActaCytol.* 1992;36:744-7.
 12. Reiter N, El-Shabrawi L, Leinweber B, Berghold A, Aberer E. Calcinosis cutis: Part II. Treatment options. *J Am AcadDermatol.* 2011;65:15-24
 13. Das S, Kalyani R, Harendra Kumar ML. Cytodiagnosis of tumoralcalcinosis. *Journal of Cytology.* 2008;25:160-1.
 14. Gupta RK, Naran S, Cheung YK. Fine-needle aspiration cytology of soft-tissue calcinosis presenting as an enlarging mass in the chest wall. *Diagn Cytopathol.* 1998;19:465-7.
 15. Agrawal P, Banik T, Dey P. Calcinosis cutis: Diagnosis by fine needle aspiration cytology-A rare case report. *Diagn Cytopathol.* 2011;39:917-918

How to cite this article: Binayke R, Taksande RV. Cytodiagnosis of idiopathic calcinosis cutis -a rare diagnosis in three cases with review of literature. *Int J Health Sci Res.* 2017; 7(4):486-490.
