

Case Report

Pharmacotherapy for Recurrent Amoebic Liver Abscess: A Case Report

Dr. Ethar Imam

Pharmaceutical Care, Department Security Forces Hospital, Makkah, Saudi Arabia

ABSTRACT

Infection by *Entamoeba histolytica* infection occurs through ingestion of cyst stage in contaminated food or water. It is a fairly common infection which occurs in 10-20% of the world population. ^[1] Invasion of tissues by *E histolytica* is usually determined by strain virulence and by host susceptibility. It is recognized that invasive amoebiasis can involve the colon, liver, peritoneum, lungs. Brain, skin and genitalia Recurrence of invasive amoebiasis is usually attributed to reinfection from environment sources or autoinfection in cyst carriers. ^[2] This case report describes good response to high dose of oral metronidazole for recurrent invasive amoebiasis in a young male patient.

Key words: Metronidazole, *Entamoeba histolytica*, Liver abscess

INTRODUCTION

Entamoeba histolytica is the most cosmopolitan protozoal infection of man which attacks 10-20% of the world population. ^[1] It is causing 40000-100000 deaths annually. Tissue invasion by *E histolytica* is usually determined by strain virulence as well as by host susceptibility.

Invasive amoebiasis is known to involve the colon, liver, peritoneum, lungs. Brain, skin and genitalia Amoebiasis rarely, but potentially may evolve into formation of amoeboma which closely resembles colorectal carcinoma. Recurrence of invasive amoebiasis is usually attributed to reinfection from environment sources or autoinfection in cyst carriers. ^[2]

In this communication we describe a case of recurrent invasive amoebiasis with good response to high dose of oral metronidazole in a young male patient.

CASE REPORT

A 15 years old male complained of abdominal pain and fever with rigors for five days. One year ago, he was admitted to

hospital with appendicular mass and had laparotomy. Later he developed 3 similar but milder attacks of abdominal pain. Physical examination at current admission showed an ill febrile patient. Temperature 38 degrees C, Pulse 110/minute Chest: dullness & diminished air entry at right lung base. Heart: Normal. Abdomen: tenderness on right lumbar region.

Investigations Hb: 11.4 gm/dcl. WBC 11500/cmm Platelets 453000 Glucose: 5.6 mmol/L. AST: 30 U/L .ALT: 80 U/L. AlkPhosphatase: 238 U/L. Na: 133. Ka4. Blood culture: No growth. Stool analysis: Negative for parasites .Serology for amoebiasis 1: 64 (IHA). Brucella, Salmonella, HBsAg, and HCV: All negative.

Chest X – Ray showed raised right side of diaphragm, The Figure .U/S & CT showed evolving liver abscess involving segment III of right liver lobe about 6.5 X 4 cm, and deformed proximal ascending colon with irregular tissue.

The patient was diagnosed as amoebic liver abscess with. He was given

IV fluids and started on oral metronidazole at a dose of 750 mg 3 times daily for 10 days. The patient showed dramatic improvement and remained afebrile. The patient was maintained on oral metronidazole 750 mg twice daily for two weeks.

Reinfection from environment sources and autoinfection in cyst carriers are recognized causes of recurrent amoebiasis. One animal study concluded that sustained upregulation of T helper 2 cytokine response is a possible explanation for why some hosts progress to invasive amoebiasis and / or carrier states. [3] The etiology of a 25 years latent *E histolytica* amoebiasis in a Japanese prisoner of war remained unexplained. [4]

DISCUSSION & CONCLUSIONS

In the present case, clinical, laboratory, and radiology evidence were diagnostic of amoebic liver abscess. Despite the presence of significant anti - *E histolytica* antibody response, it apparently did not protect this patient from reinfection. Reinfection from environment sources cannot be excluded in our patient. Future studies are needed to clarify the role of the environment as source of recurrence of amoebiasis.

In conclusion, metronidazole in high a high dose of 750 mg 3 times daily had proved to be effective in our patient. We suggest that amoebic liver abscess patients who show good response to high doses of metronidazole should be maintained on lower doses for 2-3 weeks.

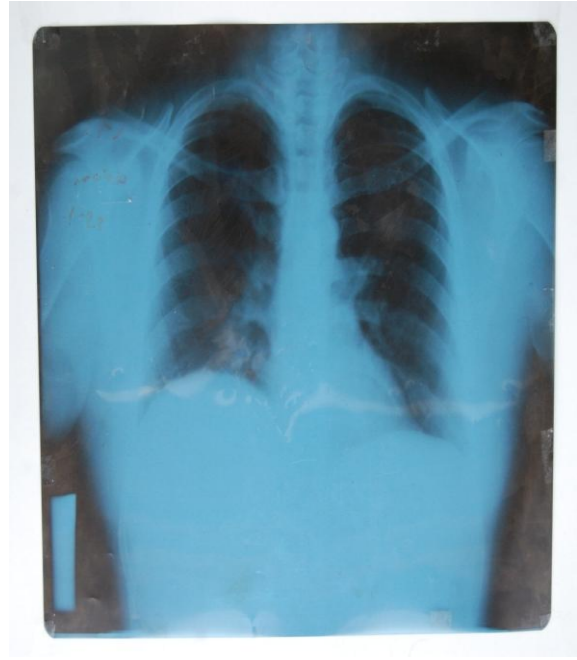


Figure 1: Chest X-Ray showing right side of diaphragm pushed up by the enlarged liver due to amoebic abscess

REFERENCES

1. Abdelbagi M, Kasha AK. Gastrointestinal parasite infestation. *EurRadiol*, 2004; 14:116-131.
2. Moran F, Smith JH, Kantam OP. Defective production of reactive oxygen intermediates in a patient with recurrent amoebic liver abscess. *Am J Trop Med Hyg*, 2002; 67(6):632-635.
3. Guo X, Lian Z. Persistence of *Entamoeba histolytica* infection in CBA mice owes to intestinal IL-4 production and inhibition of protective INF-gamma . *Mucosal Immunol* 2008; 1 (2):139-146.
4. Takenaka H, Jushi B, Suzuka Y, Xio A. A case of amoebiasis as latent infection. *KansenshogakuZasshi (Japan)*, 1996; 70 (3): 247-250.

How to cite this article: Imam E. Pharmacotherapy for recurrent amoebic liver abscess: a case report. *Int J Health Sci Res.* 2017; 7(12):328-329.
