

Case Report

## **Combined Vitello-intestinal Duct Anomalies with Intestinal Obstruction - A Case Report**

Sathvika. T<sup>1</sup>, Thermalingem. S. A<sup>2</sup>

<sup>1</sup>Senior Lecturer, Department of Anatomy, JKKN Dental College, KPM, Tamilnadu.

<sup>2</sup>General Surgery Consultant, Karunya Hospital, Bhavani.

Corresponding Author: Sathvika. T

Received: 20/07/2016

Revised: 09/08/2016

Accepted: 12/08/2016

### **ABSTRACT**

The Vitello-intestinal duct remnant is one of the rare congenital anomalies associated with the primitive yolk stalk. Most Vitello-intestinal duct remnants tend to be Meckel's diverticulum; however, the occurrence of a Vitello-intestinal cyst is very rare. Vitello-intestinal duct remnants are present in 2% of the population. This report describes a case of Vitello-intestinal cyst with fibrous Meckel's band causing intestinal obstruction in a 13yr old male patient. The patient presented to opd with signs of intestinal obstruction, ultrasound was suggestive of Urachal cyst. Laparotomy was done, a cystic swelling of about 5cm x 4cm was seen beneath umbilicus and a fibrous band was connecting the cyst with ileum near mesenteric border. The cyst along with band was resected and the rent in the ileum was closed. Histopathology of the specimen was done which confirmed the tissue as remnant of Vitello-intestinal duct.

**Key words:** Primitive yolk stalk, Meckel's cyst, Urachal cyst

### **INTRODUCTION**

The Vitello-intestinal duct remnant is one of the rare congenital anomalies associated with the primitive yolk stalk. The Vitello-intestinal duct appears at the beginning of embryonic life as a long, tubular structure that connects the midgut to the yolk sac. The Vitello-intestinal duct normally regresses during the 5<sup>th</sup>-9<sup>th</sup> weeks of fetal development, leaving a solid cord that runs from the ileum to the umbilicus. [1] In newborns and infants the anomalies of Vitello-intestinal duct manifest as a mass, prolapsing ileal loop or discharge over the umbilicus and needs urgent surgical intervention. [2] Most Vitello-intestinal duct remnants tend to be Meckel's diverticulum; however, the occurrence of a Vitello-intestinal cyst is very rare.

### **CASE REPORT**

The report describes a case of Vitello-intestinal cyst with fibrous Meckel's band causing intestinal obstruction in a 13yr old male patient. The patient presented to outpatient department with signs of intestinal obstruction, no past history suggestive of intestinal obstruction. The ultrasound was suggestive of Urachal cyst [Fig (1)]. Laparotomy was done after obtaining the informed consent from the parents of the patient.

#### **Intra operative findings**

Laparotomy was done by using a lower midline incision, a cyst was found underneath the umbilicus measuring 5x4 cm and a fibrous band was seen connecting the cyst to the ileum about 15 cm from ileocecal junction close to mesenteric border. The cyst with band was removed and the rent in

the ileum was closed. [Fig (2)] Histopathology of the cyst and the band was done, which confirmed the tissue as Vitello-intestinal duct derivative. [Fig (3)]

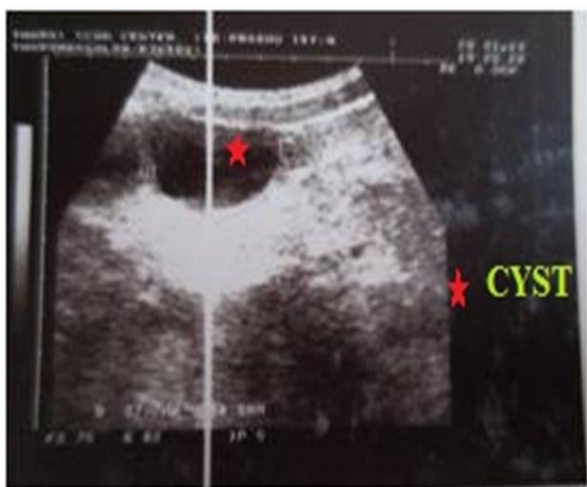


Figure (1) : Ultrasound picture of the cyst

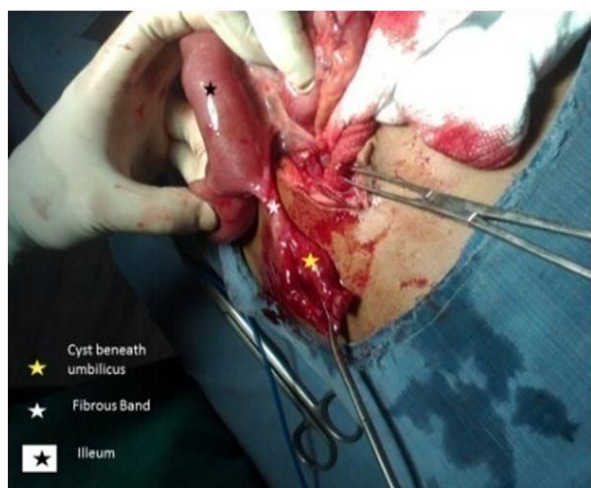

Figure (2): Intraoperative picture showing the fibrous band and cyst.

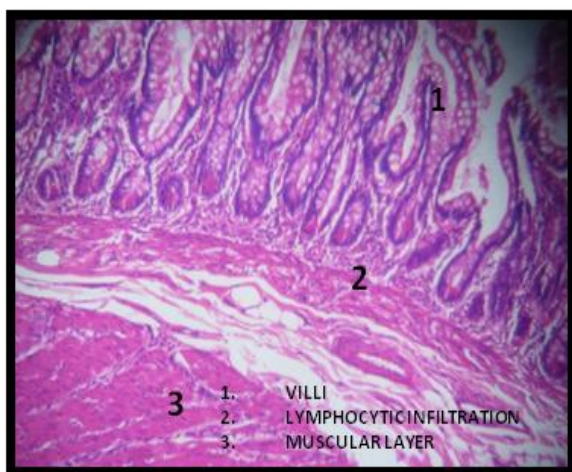


Figure (3): Histopathology of the cyst

## DISCUSSION

The Vitello-intestinal duct provides nutrition to the early developing embryo. The duct provides a communication between the primitive yolk sac on the ventral side of the embryo and the midgut loop through the umbilical coelom. [2] Umbilical anomalies usually present in infancy and other features in late childhood. A study of 217 children with Vitello-intestinal duct anomalies demonstrated that approximately 40% of these lesions were symptomatic, and among these, 80% presented in first 2 years of life. [3] In another retrospective study, 59 children presenting with a symptomatic Vitello-intestinal duct remnant during a 17-year period at a tertiary pediatric surgery unit were reviewed. [4] Of the 59 children, 36% presented with gastrointestinal tract obstruction, 31% with acute abdomen, 29% with umbilical abnormalities, and 5% with rectal bleeding. [4] Okada H et al in 1992 described Vitello-intestinal cyst in a 16 month old female child. They collected 11 cases of Vitello-intestinal cyst reported in Japan including the present case. [5] Mahato NK in 2010 reported Obliterated, fibrous omphalomesenteric duct in an adult without Meckel's diverticulum or vitelline cyst. [6] The present case is a 13 year old boy presented with features of intestinal obstruction. Usually the Vitello-intestinal remnants present early in life but this is the case presenting at late childhood. Also the Meckel's band was seen close to mesenteric border in this case as against the usual situation which is near the anti- mesenteric border. This report will be a useful guide for clinicians to think about the Vitello-intestinal duct anomalies in late childhood. Patent urachus and Vitello-intestinal duct remnants should be thought of early and relevant investigations should be ordered in case of children presenting with umbilicus swelling and features of intestinal obstruction. This should include ultrasound and Meckel's scan. Ultrasound is the first-line investigation to detect congenital anomalies affecting the umbilicus, [7] and it

can guide further management.

#### REFERENCES

1. Moore TC. Omphalomesenteric duct malformations. *Semin. Pediatr. Surg.* 1996 May; 5(2):116-23.
2. N. J. Khati, E. G. Enquist, and M. C. Javitt, "Imaging of the umbilicus and periumbilical region," *Radiographics*, vol. 18, no. 2, pp. 413-431, 1998.
3. Vane DW et al. Vitelline duct anomalies. Experience with 217 childhood cases. *Arch. Surg. Chic. Ill* 1960. 1987 May; 122(5):542.
4. C. U. Durakbasa, H. Okur, H. M. Mutus et al, "Symptomatic omphalomesenteric duct remnants in children," *Pediatrics International*, vol. 52, no. 3, pp. 480-484, 2010.
5. Okada H, Samma S, Momose H, Tsujimoto S, Nagayoshi J, Iwai A, Hirao Y, Okajima E. A case of vitello intestinal cyst. 1992 Jan; 38(1):81-4
6. Mahato NK. Obliterated, fibrous omphalo-mesenteric duct in an adult without Meckel's diverticulum or vitelline cyst. *Rom J Morphol Embryol.* 2010; 51(1):195-7.
7. E. Boothroyd and R. E. Cudmore, "Ultrasound of the discharging umbilicus," *Pediatric Radiology*, vol. 26, no. 5, pp. 362-364, 1996.

How to cite this article: Sathvika T, Tharmalingem SA. Combined vitello-intestinal duct anomalies with intestinal obstruction - a case report. *Int J Health Sci Res.* 2016; 6(9):497-499.

\*\*\*\*\*