

Case Report

A Rare Case of Epidermal Cyst of the Submandibular Gland

Nanda Patil¹, Dhiraj Shukla², Rashmi Sonawane³¹Professor, ²Assistant Professor, ³Tutor,
Krishna Institute of Medical Sciences Karad, Maharashtra.

Corresponding Author: Rashmi Sonawane

Received: 03/04/2016

Revised: 14/05/2016

Accepted: 22/05/2016

ABSTRACT

Background: Epidermal cysts are common skin lesions. However, epidermal cyst is rarely seen in the salivary gland and is likely to be mistaken for a salivary gland abscess, neoplasm or mucocele. Histopathological examination is necessary for the diagnosis.

Case History: We report a rare case of epidermal cyst occurring in the submandibular salivary gland. A 60 year old female patient presented with a swelling over left submandibular region since 1 year. Histopathological examination revealed epidermal cyst in submandibular gland.

Conclusion: Epidermal cyst is rare in submandibular gland and can be clinically misdiagnosed as sialoadenitis, neoplastic process. Clinicians should be aware of this possible diagnosis. Excisional biopsy for histopathological examination is essential to make the diagnosis.

Key word: Epidermal cyst, Submandibular Gland.

INTRODUCTION

Epidermal cysts are common skin lesions. However epidermal cysts are rarely seen in the salivary gland [1] and are likely to be mistaken for a salivary gland abscess, neoplasm or mucocele. Histopathological examination is necessary for the diagnosis. We report a rare case of epidermal cyst in submandibular salivary gland which was diagnosed clinically as malignant tumour.

CASE HISTORY

A 60 year old female patient presented with 2x2 cm, painless swelling over left submandibular region since 1 year which was diagnosed clinically as malignant tumour of salivary gland. There was no history of fever or cough. The swelling was excised and sent for histopathological examination.

Gross

Received a specimen of salivary gland with attached globoid soft mass measuring 2x2x1.5 cm with a small lymph node adjacent to it measuring 0.8x0.4x0.2 cm. Cut section revealed a cystic mass arising in a salivary gland filled with pultaceous material. Adjacent lymph node was unremarkable Fig 1.

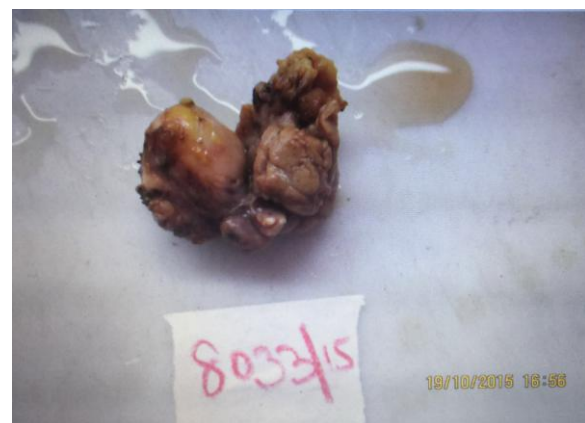

Fig 1: Gross specimen of salivary gland with attached globoid mass

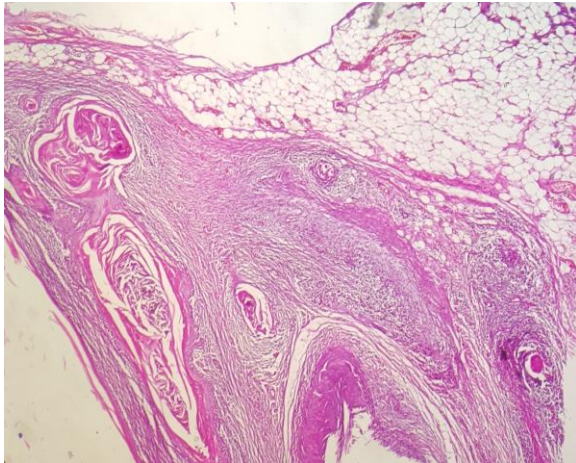


Fig 2: Photomicrograph showing cystic lesion lined by keratinised stratified squamous epithelium with adjacent salivary gland (H &E 40X)

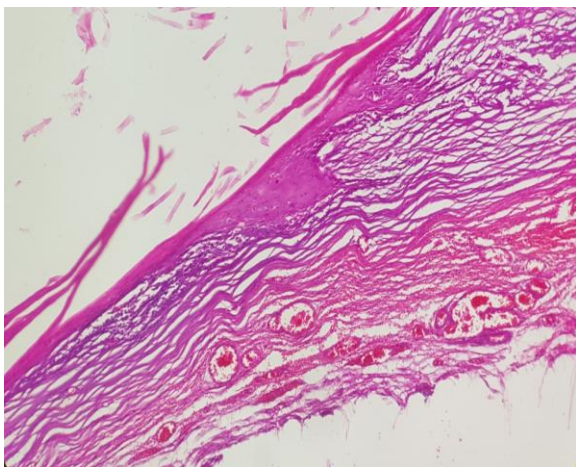


Fig 3: Cyst wall composed of keratinised stratified squamous epithelium (H &E 100X)

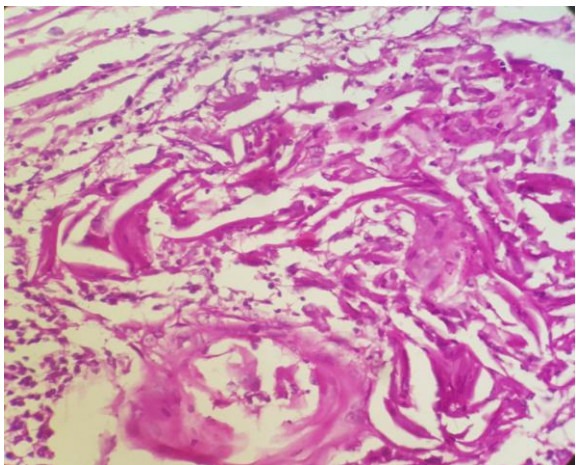


Fig 4: Foreign body giant cell reaction to keratin material (H &E 400X)

Microscopy

Microscopy from a lesion revealed a cyst wall composed of flattened stratified squamous epithelium with keratinous debris inside. Adjacent lymph node revealed reactive hyperplasia. Surrounding tissue

revealed foreign body giant cell reaction to keratin Fig 2, 3 & 4.

DISCUSSION

Epidermal cyst is a common lesion of the skin, the wall of which is composed of keratinised squamous epithelium without adnexa and cyst is filled with semisolid epithelial debris. These are developmental cysts seen in head and neck area with an incidence that ranges from 1.6 to 6.9%. [2]

An epidermal cyst in salivary gland is a rare entity. It is essential to have preoperative diagnosis for workup of patient. [1] Epidermal cyst can occur at any age from birth to 72 years. They present as a soft cystic swelling with dough like feel on palpation. Our case presented as submandibular painless swelling at the age 60 year. Epidermal cyst of sublingual gland can present as dysphagia, dyspnoea or dysphonia. [3] A clinical and radiological characteristic of these lesions can be ambiguous. The diagnosis is challenging due to difficulty of determining their benign versus malignant nature. Malignancy is suspected when the swelling is rapidly developing and associated with lymphadenopathy or facial nerve paresis. In our case also swelling was diagnosed clinically as malignant because of associated lymphadenopathy. [1]

Differential Diagnosis

Epidermal cyst in submandibular gland can be mistaken for salivary gland abscess, neoplasm, tuberculous lymphadenitis, metastatic lymph node and other cysts. [4-6] It is essential to make a preoperative diagnosis for further management of the patient. Fine needle aspiration cytology can help to make a preoperative diagnosis and the definitive diagnosis is done with excision of the lesion.

Treatment and Prognosis

Surgical management is complete excision of cyst without any rupture because spillage of the cystic content in the adjacent fibrovascular tissue can cause post operative inflammation. Recurrence rate is very rare

after excision. [7] Six month follow up of our patient is uneventful.

CONCLUSION

Epidermal cyst of submandibular salivary gland is a rare entity which can be mistaken for a wide variety of lesions.

Excisional biopsy for histopathological examination is helpful for the definitive diagnosis and is also a curative procedure.

REFERENCES

1. Hegde PN, Prasad HLK, Kumar SY, Sajitha K, Roy PS, Raju M et al. A case of epidermoid cyst in the parotid gland - which was diagnosed by Fine Needle Aspiration Cytology. *J Clin Diagn Res.*2013; 7(3):550-552.
2. Sanglee C, Kaun Kin H. Iatrogenic epidermoid cyst in the parotid gland - A case report. *J Korean Association Oral Maxillofacial Surg.* 2011; 37:237-40.
3. Janarthanam J and Mahadevan S. Epidermoid cyst of submandibular region. *J Oral Maxillofac Pathol.* 2012; 16(3):435-437.
4. Dutt, S.N., et al. (2000) Epidermoid Cyst of the Submandibular Gland. *Indian Journal of Otolaryngology and Head and Neck Surgery*, 52,378-379.
5. Back, G.W., Fahmy, F. And Hosni A. Submandibular Salivary Duct Cyst Mimicking an External Laryngocele. *Journal of Laryngology and Otology*, 2000, 114,305-307.
6. N Prepageran, FRCS, O Rahmat, MS, S Kuljit, MS. Epidermal cyst of Submandibular Gland. *Med J Malaysia*, 2005, 60 (4), 483-484.
7. Kar R, Thorawade V, Jagade M, Attakkil A, Kedar S, Rohe D et al. An Unusal Case of Epidermal Cyst in Submandibular Space. *International Journal of Otolaryngology and Head and Neck Surgery*, 2014, 3, 213-215.

How to cite this article: Patil N, Shukla D, Sonawane R. A rare case of epidermal cyst of the submandibular gland. *Int J Health Sci Res.* 2016; 6(6):434-436.
