

Case Report

## Retroperitoneal Malignant Peripheral Nerve Sheath Tumor

Datta Prasad M<sup>1</sup>, B Ananda Rama Rao<sup>2</sup><sup>1</sup>Resident in Surgery, Dept. of General Surgery, SVS Medical College, Mahabubnagar, India.<sup>2</sup>Dean and Professor of Surgery, SVS Medical College, Mahabubnagar, India.

Corresponding Author: B Ananda Rama Rao

Received: 04/05/2016

Revised: 14/05/2016

Accepted: 16/05/2016

### ABSTRACT

Malignant peripheral nerve sheath tumors are rare tumors with an incidence of 0.001% in general population and they account for <10 % of all soft tissue sarcomas and that of only one percent are retroperitoneal. A rare case of retroperitoneal MPNST in a 40 year old male is presented with mass abdomen. There was a diagnostic dilemma of leiomyosarcoma. USG and CT abdomen could not locate the origin of the tumor. The tumor was fixed to the aorta, pancreas and showed a suspicious secondary in the liver. There is a secondary deposit in the ileum which is a rare finding. Diagnosis was confirmed by immunohistochemistry with S-100 protein.

**Key words:** MPNST Retroperitoneal tumour S-100 protein.

### INTRODUCTION

One of the rare aggressive soft tissue sarcoma is malignant peripheral nerve sheath tumor (MPNST) occurs rarely in general population, but associated with neurofibromatosis type 1, which is caused by heterozygous mutations of NF1 gene. The life time incidence of MPNST in NF1 patients is 8 to 13%. Malignant peripheral nerve sheath tumors (MPNST) are rare spindle-cell sarcomas derived from Schwann cells or pluripotent cells of the neural crest. [1] Among all soft tissue sarcomas MPNST account for >10%. MPNSTs most commonly affect patients aged 20 to 50 years, but have also been reported in children. [2-4] The histological variants are melanotic, epithelioid and a divergent variant with epithelial, glandular and mesenchymal differentiation. Among the variants the cellular variant is considered benign. [5] Its location in the retroperitoneum in a patient without

neurofibromatosis is an exceedingly rare occurrence. [6]

### MATERIALS AND METHODS

A male patient of 40 years presented with rapidly increasing mass in epigastric region of one year duration. It was associated with dragging pain and low grade fever. History of significant loss of weight (10 kgs in 3 months) was present. No history of jaundice and diabetes. On examination revealed pallor. A retroperitoneal mass of 20 x 10 cm noted in epigastric and left hypochondriac region extending on to the right hypochondrium and umbilical regions. It was not moving with respiration. It was variable in consistency, irregular shape. Liver was enlarged (2cm below the costal margin in mid clavicular line. There was no ascites (Fig-. 1).

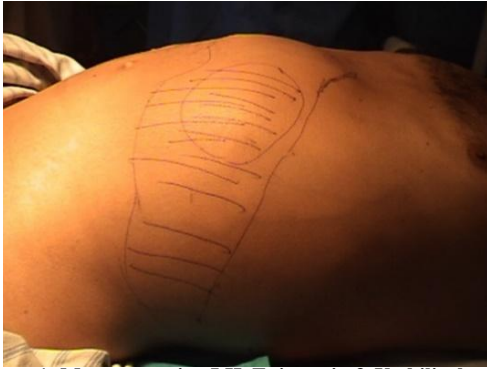

Figure 1: Mass occupying LH, Epigastric & Umbilical regions

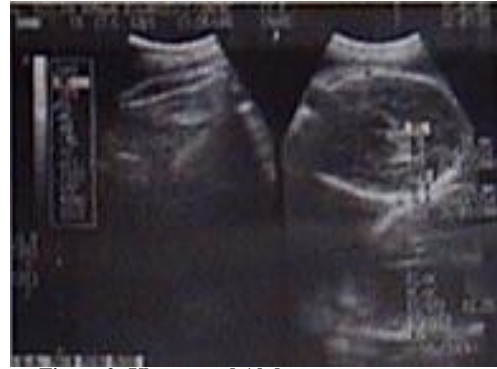

Figure 2: Ultra sound Abdomen

**On investigation patient is anemic, LFT is in within normal limits, Ultra sound abdomen (Fig-2):** a well defined rounded cystic lesion measuring 9.5x9cms in posterosuperior aspect of right lobe of liver with double layered wall. Large echogenic lesion noted measuring 19x13 cms in the left hypochondriac and lumbar regions with multiple cystic spaces of variable sizes causing superior displacement of spleen and inferior displacement of left kidney suggestive of cystic tumor from body and tail of pancreas. USG guided FNAC revealed extensive necrotic debris with few mononuclear cells. Hence opinion not possible.

**CT ABDOMEN (Fig 3, 4):** Large mass lesion having solid & cystic components with multiple septations within & measuring 16x16x17 cms noted in anterior to and tail of pancreas and anterior to splenic hilum. Hepatomegaly, non-enhancing large low attenuating lesion in Right lobe of Liver 8x8x10 cms? Necrotic secondary? Abscess/ Leiomyo sarcoma At laparotomy (Fig-5&6) large mass found posterior to, and free from stomach. Mass fixed to the aorta, posterior peritoneum and pancreas. Kidney and spleen are pushed aside debulking done.

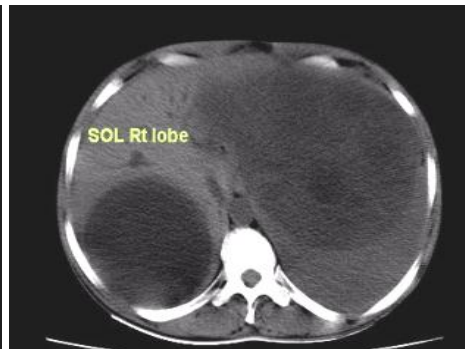
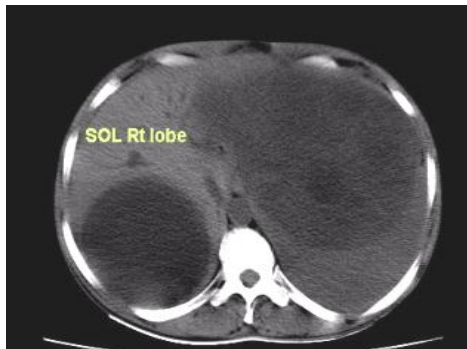
Fig-3&4: CT Scan-Septate tumour & SOL Rt lobe liver

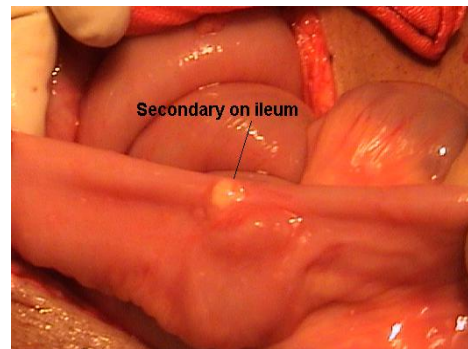
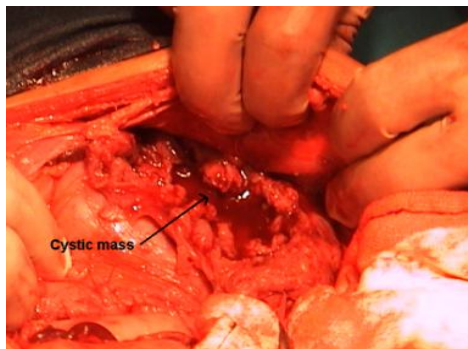


Figure 5&6:

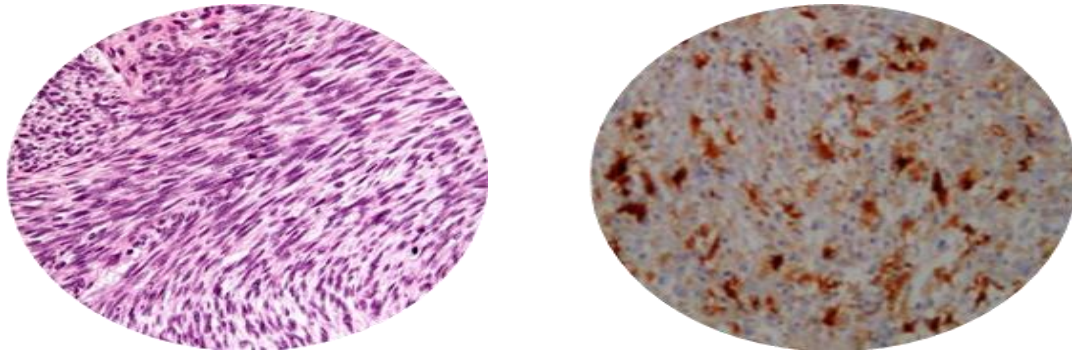


Figure 6&7:

**Histopathology:** (Fig 6&7) Cellular & mucinous areas with Short fascicles of spindle cells, Small clusters with intra cytoplasmic vacuolation. Cytoplasm is abundant & bright. Organoid pattern is evident. Cytological evidence of Malignancy with moderate pleomorphism. 2 to 3 mitosis/HPF. On immunohistochemistry for S-100 is positive.

**Diagnosis:** Malignant Nerve sheath tumour.

## DISCUSSION

Malignant peripheral nerve sheath tumors are rare tumors with an incidence of 0.001% in general population. [7] They account for <10% of all soft tissue sarcomas. [1] These tumors may arise de novo in adult patients. 10 to 60% of MPNST tend to have associated with multiple NF1. [1] They are commonly seen in head and neck, upper extremities. Only one percent of MPNST is abdominal and are retroperitoneal. [8] In this case neither USG nor CT abdomen could give a definitive diagnosis, except to say it is from retroperitoneum. Though the tumor was adherent to aorta and pancreas and surprisingly a small secondary was noted on ileum. This is not reported anywhere in literature. Liver showed a cystic mass but lungs are spared.

Dasgupta et al observed that the origin of the tumor most of the times could not be ascertained since these tumors arise from unnamed small nerves. [9] Nambisan et al also could not arrive at nerve of origin in 60% of their cases. [10] Gross and microscopic findings may give a diagnosis

but immunohistochemistry with S-100 protein in immunoreactivity give a diagnosis of MPNST. [11] The immunoreactivity of S-100 is detected in about 50 to 60 % of MPNST, because this protein is also seen in other tissues and tumor types. [12,13] Treatment of MPNST has been combined modality that includes aggressive surgery with wide margin of clearance or mass debulking. Several cycles of adjuvant chemotherapy with cyclophosphamide / doxorubicin have been advocated [14] In spite of aggressive combined radiation and systemic chemotherapy, the 5-year survival rates for MPNSTs range from 35% to 50%. [11,15]

## REFERENCES

1. Hrehorovich PA, Franke HR, Maximin S, Caracta P (2003) Malignant peripheral nerve sheath tumor. *Radiographics* 23:790-4.
2. M. Pilavaki, D. Chourmouzi, A. Kiziridou, A. Skordalaki, T. Zarampoukas, and A. Drevelengas (2004) "Imaging of peripheral nerve sheath tumors with pathologic correlation: pictorial review," *European Journal of Radiology*, vol. 52, no. 3, pp. 229-239, 2004.
3. J. M. Meis, F. M. Enzinger, K. L. Martz, and J. A. Neal (1992), "Malignant peripheral nerve sheath tumors (malignant schwannomas) in children," *American Journal of Surgical Pathology*, vol. 16, no. 7, pp. 694-707, 1992.
4. P. Oguzkurt, F. Kayas, S. Ucelcuk, I. S. Arda, O. Barutcu, I. Tuncer, S. Oz (2001) "Anterior abdominal wall

- malignant peripheral nerve sheath tumor in an infant," *Journal of Pediatric Surgery*, vol. 36, no. 12, pp. 1866-1868, 2001.
5. White W, Shiu MH, Rosenblum MK, Erlandson RA, Woodruff JM. (1990) Cellular schwannoma: A clinicopathological study of 57 patients and 58 tumors. *Cancer* 1990; 86:1266-75.
  6. Amin MU, Shafique M (2007) Isolated malignant peripheral nerve sheath tumor of retro peritoneum. *J Coll Physicians Surg Pak* 17:226-7.
  7. Chhabra A, Soldatos T, Durand DJ, Carrino JA, McCarthy EF, Belzberg AJ(2011). The role of magnetic resonance imaging in the diagnostic evaluation of malignant peripheral nerve sheath tumors. *Indian J Cancer*.2011; 48:328-334.
  8. Meng ZH, Yang YS, Cheng KL, Chen GQ, Wang LP, Li W. (2013) A huge malignant peripheral nerve sheath tumour with hepatic metastasis arising from retroperitoneal ganglioneuroma. *Oncol Lett*. 2013; 5:123-6.
  9. Dasgupta TK, Brasfield RD (1970) Solitary malignant schwannoma. *Ann Surg* 1970; 171:419-28.
  10. Ambisan RN, Rao U, Moore R, Karakousis CP. (1970) malignant soft tissue tumors of nerve sheath origin. *J Surg Oncol* 1984; 25: 268- 72.
  11. Ducatman SB, Bernd WS, David GP, Herbert MR, Duane MI (1986) malignant peripheral nerve sheath tumors. A clinicopathologic study of 120 cases. *Cancer* 57: 2006-21.
  12. Gonzalez-Martinez T, Perez-Pinera P, Diaz-Esnal B, Vega JA: (2003) S-100 proteins in the human peripheral nervous system. *Microsc Res Tech* 2003, 60: 633-638.
  13. Klijanienko J, Caillaud JM, Lagace R, Vielh P. (2002): Cytohistologic correlations of 24 malignant peripheral nerve sheath tumor (MPNST) in 17 patients: the Institute Curie experience. *Diagn Cytopathol* 2002, 27:103-108.
  14. Cameron RB, Loehrer PJ, Thomas Jr CR. (2001) Neoplasms of the mediastinum. In: DeVita Jr VT, Hellman S, Rosenberg SA, editors. *Cancer Principles and practice of Oncology* 6th ed, 2001. Lippincott Williams and Wilkins, USA 1031-2.
  15. Carli M, Ferrari A, Mattke A, Zanetti I, Casanova M, Bisogno G, Cecchetto G, Alaggio R, De Sio L, Koscielniak E, et al: Pediatric malignant peripheral nerve sheath tumor: the Italian and German soft tissue sarcoma cooperative group. *J Clin Oncol* 2005, 23:8422-8430.

How to cite this article: Prasad D, Rao BAR. Retroperitoneal malignant peripheral nerve tumour. *Int J Health Sci Res*. 2016; 6(6):410-413.

\*\*\*\*\*