

Case Report

Neuropsychological and Multilingual Rehabilitation in Cognitive Communication Disorder (CCD): A Case Study

Pinki Singh¹, Apoorva Pauranik²

¹Master of Audiology & Speech Language Pathology, All India Institute of Medical Sciences, MP, Bhopal.

²DM, Neurophysician and Associate Professor, MGM Medical College, MP, Indore.

Corresponding Author: Pinki Singh

Received: 29/01/2016

Revised: 18/02/2016

Accepted: 23/02/2016

ABSTRACT

Background: Cognitive-communication disorders (CCD) encompass difficulty with any aspects of communication that is affected by disruption of cognition. Rehabilitation of such cases with exposure of multilingualism gives challenges with respect to selection of language and approaches for treatment.

Objectives: To incorporate impairment based neuropsychological rehabilitation techniques and multilingual behaviours rehabilitation approach such as code-switching, to maximize treatment efficacy in CCD following traumatic brain injury TBI.

Materials and methods: These approaches were used for six hours per week over a period of one year for BG, 23 years multilingual, right handed female diagnosed as a CCD following TBI.

Results: After twelve months of therapy, her performances improved significantly with prominent skills of self monitoring and self correction.

Discussion: Treatment approaches have shown its impact of better performance on functional communication and standard test batteries as well.

Conclusion: Therapy outcome was good probably due to young age, intensive training, high motivation, family support and being multilingual.

Key words: Neuropsychological rehabilitation, Multilingual, Code switching.

INTRODUCTION

Cognitive-communication disorders (CCD) encompass difficulty with any aspects of communication that is affected by disruption of cognition. Communication includes listening, speaking, gesturing, reading, and writing in all domains of language. Cognition includes cognitive processes and systems (e.g. attention, memory, organization, executive functions). Areas of function affected by cognitive impairments include behavioural self regulation, social interaction, activities of daily living, learning and academic performance and vocational performance. [1]

Rehabilitation of multilingual individual with CCD is a challenge with respect to selection of language and approaches for treatment. We have incorporated impairment based neuropsychological rehabilitation techniques aiming at the best cognitive, neurobiological and social re-adaptation and natural multilingual behaviours, such as code-switching, to maximize treatment efficacy and to achieve highest level of communicative participation in everyday living.

Aims:

1. To replicate case study with neuropsychological and multilingual behaviour rehabilitation approach.
2. To establish the efficacy of our approach in an individual with CCD accompanied by Traumatic brain injury (TBI).

MATERIALS AND METHODS

BG, 23 years multilingual (Hindi, English and Marathi) right handed female had a Road traffic accident, eleven month before our evaluation. She had haemorrhagic cerebral contusions and edema of Left frontal- temporal -parietal regions. She had undergone craniotomy (Fig.1 & 2).

During assessment of cognitive, communication, speech and language domains by utilising test batteries, qualitatively it was found that she had Effortful & very limited speech at word level, Inability to phoneme- grapheme conversion & vice versa ,Severe word retrieval difficulties, Impaired recent and immediate memory, discourse abilities (spontaneous, procedural, narrative tasks), organization skills & impaired abstract reasoning and problem solving abilities. She was diagnosed as a CCD following TBI with acquired dyslexia and dysgraphia. She started speech and language therapy after 11 months of her accident with very limited verbal output, minimal- mild hemiparesis and hemianopsia in right side.

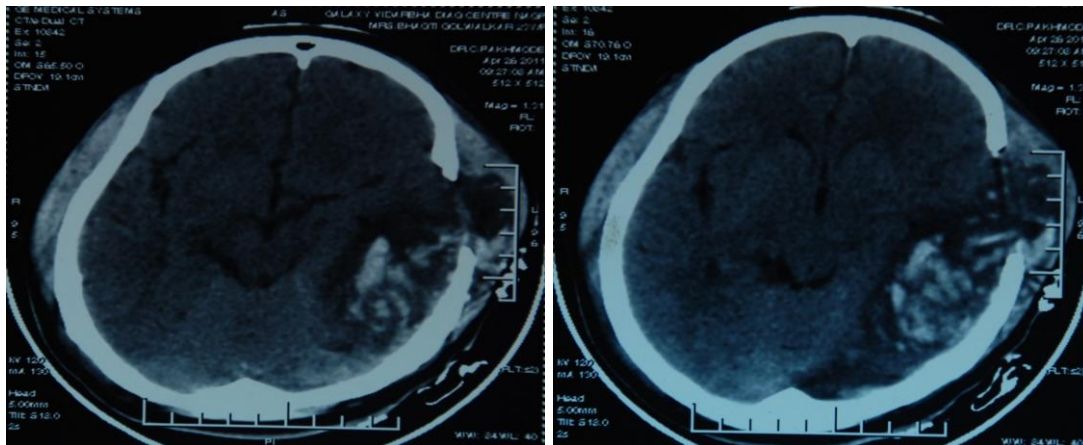


Figure 1: CT study reveals large intra parenchymal haemorrhagic contusion in the left temporo-parietal & adjacent occipital lobe with overlying subarachnoid haemorrhages. Mild to moderate pericontusional edematous changes seen

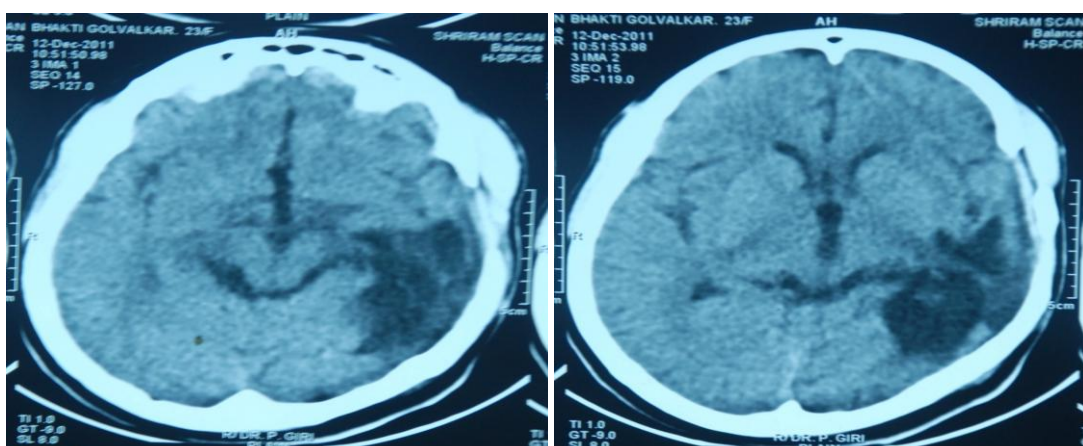


Figure 2: Follow up CT scan shows the large area of volume loss in the left temporo-parietal & adjacent occipital as well as frontal lobe with marked exvacuo dilation of ipsilateral occipital horn region.

To enhance effective verbal communication, neuropsychological rehabilitation techniques and natural

multilingual behaviours were used for six hours per week over a period of one year.

Rehabilitation of neuropsychological deficits usually consists of diverse interventions, thus it has been tailored with introducing goals related to self awareness and self regulation of memory, learning, and problem solving with usage of internal or external compensatory strategies, errorless learning, metacognitive and Multimodal feedback strategies were employed

RESULTS

After twelve month of therapy, her performances on Western Aphasia Battery-R (WAB-R; Kertsz, 2006); Ross Information Processing Assessment-2(RIPA-2; Ross,1996);Rancho Los Amigos levels of Cognitive Functioning Scale-R(Malkmus et al.1974) (table 1) has improved drastically with prominent skills of self monitoring and self correction. She could describe picture/events/daily activities/logical answering with almost meaningful, relevant sentences by using key/content words with fair grammatical competence and mild to moderate word finding difficulty.

Table 1: Performance on the Western Aphasia Battery-R (WAB-R; Kertsz, 2006); Ross Information Processing Assessment-2(RIPA-2; Ross, 1996); The Rancho Los Amigos levels of Cognitive Functioning Scale-R (Malkmus et al.1974).

<i>Test details</i>	<i>Pre therapy</i>	<i>Post therapy</i>
Western Aphasia Battery		
<i>Aphasia Quotient</i>	32.3	71
<i>Fluency</i>	9	13
<i>Auditory Comprehension</i>	4.15	9
<i>Naming</i>	3	7
<i>Repetition</i>	2	6.5
Ross Information Processing Assessment		
<i>Standard score (ratings)</i>	9 (marked)	13(moderate)
The Rancho Los Amigos levels of Cognitive Functioning Scale-R		
	<i>Stage VIII</i>	<i>Stage IX</i>

DISCUSSION

To maintain the efficacy of neuropsychological rehabilitation approach, it is important that learning objectives should be clearly stated. Individual with CCD should provide models and carefully fade prompts and cues to facilitate errorless acquisition, consistent feedback (e.g. immediately model the correct response after the client makes a mistake), sufficient, cumulative review (i.e. integrate new with old material). It has been found that

cognitive exercises prominently focussing on targeting and suppression may limit cross language interference or pathological switching. [2] It also helps individual with CCD in identifying conditions, situations, tasks, and activities through active self-monitoring and facilitates strategy decisions, metacognition, self regulations and executive functions. [3]

Furthermore, there is requirement to develop simple, consistent instructional wording and scripts to reduce confusion and focus learner on relevant content. These instructional wordings and script may include mixed language for better understanding, execution and strengthening recovery-related changes at the neural level. It has been found that multilingual Spanish –English client with aphasia activate perilesional left-hemisphere regions for their more proficient language and a broader network, including right-hemisphere regions, for less proficient language. [4] It may also suggest that the circumstances including relative language proficiency and language similarities, under which intervention in one language benefits the untreated languages. [5]

Along with language, sociolinguistic and interpersonal skills should also be a legitimate concern to generalize treatment effects to modify communication behaviours of others in the aphasic individual's environment. [6]

The therapy outcome in this case was good probably due to young age, intensive training, high motivation and family support and being multilingual.

CONCLUSION

Instead of depending on language oriented treatment solely, cognitive neuropsychological based approaches are more facilitating approach in terms of metacognition, self learning through self monitoring and self correction. These skills automatically maximize functional communication of individuals with cognitive communication disorder (CCD) secondary to traumatic brain injury (TBI).

On the other hand, decision about selection of only native language for instruction during treatment must be discarded. Incorporation of natural multilingual behaviours, such as code-switching must be encouraged, to maximize treatment efficacy. Intervention in one language also benefits the untreated languages due to overlapping of neural system of different languages.

REFERENCES

1. American speech and hearing association (ASHA), (2004).
2. Penn C, Frankel T, Watermeyer J, Russell N. Executive function and conversational strategies in bilingual aphasia. *Aphasiology*. 2010; 24: 288-308.
3. Kennedy MR, Coelho C. Self – regulation after traumatic brain injury: A framework for intervention of memory and problem solving. *Seminars in speech and language*. 2005; 26(4):242-55.
4. Sebastian R, Kiran S, & Sandberg C. Semantic processing in Spanish-English bilingual with aphasia. *Journal of neurolinguistics*; 2012; 25(4):240-262.
5. Kiran S, Goral M. One disorder, multiple languages. *The ASHA leader*. 2012 June 5.
6. Holland AL. Cognitive neuropsychological theory and treatment for aphasia: Exploring the strengths and limitations. *Clinical aphasiology*. 1994; 22:275-82.

How to cite this article: Singh P, Pauranik A. Neuropsychological and multilingual rehabilitation in cognitive communication disorder (CCD): a case study. *Int J Health Sci Res*. 2016; 6(3):336-339.
