



Case Report

A Case of McKusick-Kaufman Syndrome with Urogenital Sinus

Varun Hathiramani, Vinod Raj, Swathi C, Rajeev Redkar

Lilavati Hospital and Research Centre, Mumbai, India.

Corresponding Author: Varun Hathiramani

Received: 14/07/2015

Revised: 29/07/2015

Accepted: 30/07/2015

ABSTRACT

McKusick Kaufman syndrome is a rare autosomal recessive disorder which presents with multiple congenital abnormalities affecting cardiovascular, genitourinary systems with limb anomalies. It is essential to differentiate this syndrome from Bardet-Biedl syndrome which has similar clinical presentation but poorer outcomes.

Key Words: Polydactyl, Hydrometrocolpos, McKusick- Kaufman syndrome, Bardet-Biedl syndrome

BACKGROUND

McKusick Kaufman syndrome (MKKS) is an autosomal recessive genetic disease which presents in the neonatal age group with polydactyly, congenital heart defects and genito-urinary abnormalities. ⁽¹⁾

INTRODUCTION

A 5 day female Presented to us with abdominal distension, massive lower limb oedema and extra digits on all four limbs. On investigating, the child had a large fluid filled vagina causing pressure effects on the renal system and lower limbs due to a urogenital sinus. A vaginosotomy and partial urogenital mobilization was done.

CASE REPORT

A second born female child presented to us on day 5 of life with abdominal distension, oedematous dusky lower limbs and post axial polydactyly of all limbs. She was born of a pre-term emergency caesarean

section in view of rupture of membranes. At birth the child weighed 2.16kg, did not cry immediately, required bag and mask resuscitation and oxygen support. The child was passing urine and stools.

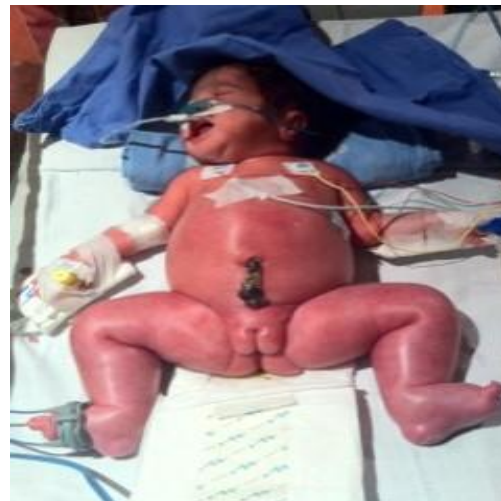

Figure no 1: Clinical picture

On admission the child had tachypnea and minimal subcostal

retractions. The abdomen was distended with abdominal wall erythema and an ill-defined diffuse, firm swelling around 5cm x 5cm in dimension was palpable in the peri-umbilical region. The perineal area could not be clearly examined due to the gross vulval oedema.

Infective parameters were elevated. 2D Echo showed a small ASD with a left to right shunt.

The ultrasound scan of abdomen and pelvis showed the uterus to be pushed upwards by two large cystic masses of either vaginal or ovarian origin along with bilateral hydronephrosis. The child was started on intra venous antibiotics and supported with intra-venous fluids and oxygen.

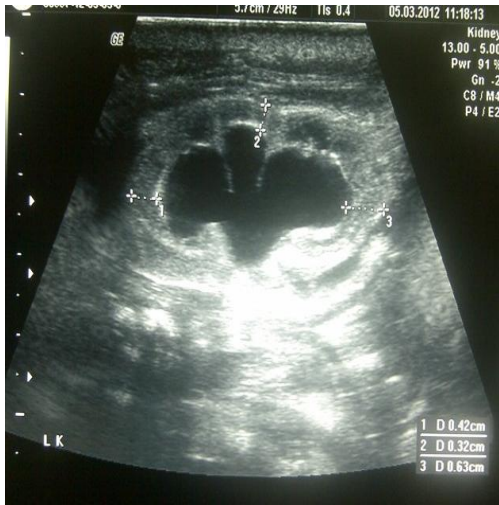

Figure no 2: USG showing hydronephrosis

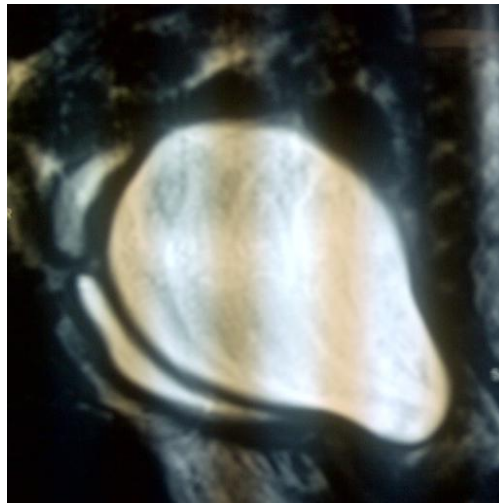


Figure no 3: MRI abdomen showing fluid filled vagina compressing the bladder anteriorly.

MRI abdomen showed a fluid filled vagina (7*5*5cm) with peripheral hypointense walls. The uterus was seen separately with minimal endometrial fluid. The ovaries could not be visualized separately. The bladder was partly distended and appeared compressed by the lesion with gross bilateral hydronephrosis.

A fluid filled vagina was causing pressure effects and hence the child was taken up for an emergency exploratory laparotomy and vaginostomy. The abdomen was explored through an infra-umbilical incision. After retracting the bladder a large capacious distended vagina was seen. On aspirating the vagina turbid, white fluid was obtained (culture-sensitivity showed no growth). A few bowel loops were adherent to the dilated vagina. The ovaries could not

be visualized due to surrounding inflammation. An 8 French Foley catheter was placed in the vagina and brought out on the abdomen as a vaginostomy.

Post-operatively per-urethral and vaginostomy catheters were both draining urine. The oedema gradually began to subside. The serum creatinine showed a rising trend (0.8mg/dl → 1-1mg/dl). A Renal Doppler showed moderate-severe bilateral hydronephrosis with thinning of cortical parenchyma and dilated tortuous ureters. The cortical perfusions of both kidneys were normal. The serum creatinine gradually normalised to a level of 0.7mg/dl. Once the oedema completely subsided the introitus showed a single opening. A genitogram and micturating cystourethrogram was done

which showed a urogenital sinus with a common channel.

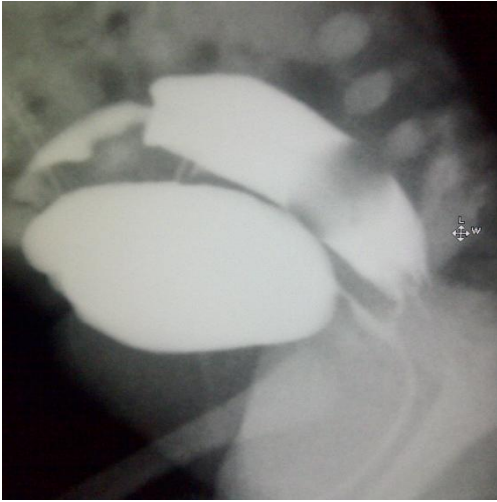


Figure no 4: Genitogram showing uro-genital sinus: common channel with contrast in bladder, vagina and uterus

The child was discharged with the vaginostomy tube in situ and is being followed up regularly with a clinical diagnosis of MKKS.

At the age of 4 months a decision for a definitive repair of the urogenital sinus and amputation of the extra digits was taken. Cysto-vaginoscopy done under anaesthesia

confirmed a common urogenital sinus of 3cm. The vaginal opening narrowed at the junction with the common channel. A 3 French Fogarty catheter was introduced through the scope into the vagina and the balloon was inflated in the vagina. A perineal inverted U- shaped incision enabled access to the vagina beyond the common channel. Using traction on the Fogarty catheter, a horizontal incision was made on the posterior vaginal wall and subsequently the vagina was separated all around from the common channel. The urogenital sinus was closed and the vaginal opening was mobilized and externalized using the external skin flaps.

Postoperatively an 8 French Foley urinary catheter was kept for 10 days and a 10 French Foley catheter was kept in the neo-vagina for 3 weeks.

At follow up at 4 months clinically the child has no abdominal lump or urinary infections. The child is emptying the bladder well and has no abnormalities on a check ultrasound scan of the abdomen.

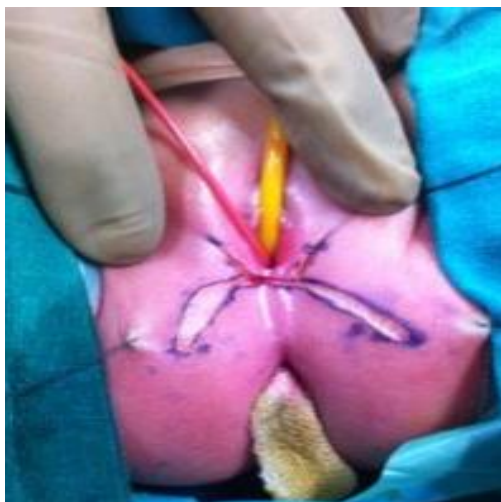

Figure no 5: Intra-operative picture with Foleys catheter in urethra, Fogarty catheter in vagina and curvilinear incision

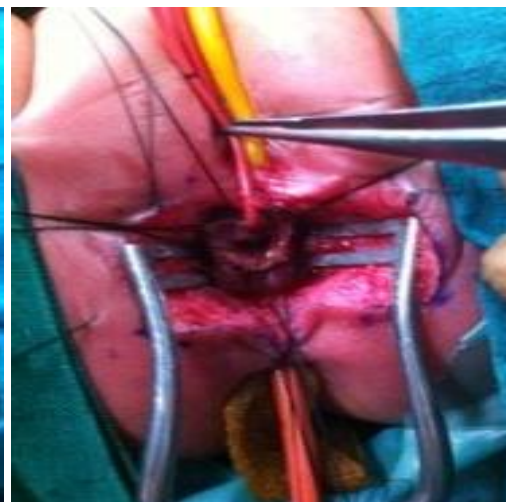


Figure no 6: Vaginal mobilization

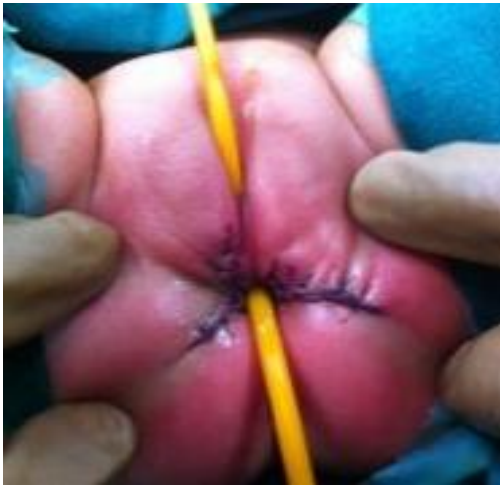

Figure no 7: Separation of urethral and vaginal openings

DISCUSSION

MKKS is an autosomal recessive disorder and was first described in the Amish population, where it affects an estimated 1 in 10,000 people. The incidence of MKKS in non-Amish populations is unknown. ⁽¹⁾ There are about a hundred cases of this syndrome reported in literature so far.

MKKS is a rare syndrome comprised of multiple congenital abnormalities affecting both males and females but is more common in the latter group. It is a condition that affects the development of the hands and feet, heart, and reproductive system. ⁽²⁾ It is characterized by postaxial polydactyly, congenital heart disease and hydrometrocolpos in females and genital malformations like hypospadias, cryptorchidism or chordee in males.

Most females with MKKS are born with a genital abnormality called hydrometrocolpos presenting as a large cystic abdominal mass arising out of the pelvis, due to accumulation of cervical secretions from maternal oestrogen stimulation. ⁽³⁾ This fluid filled mass can cause pressure effects on surrounding structures of the urinary system, the major abdominal vessels giving rise to

hydroureteronephrosis, vascular compression leading to reduced venous return from the lower limbs and oedema.

Two mutations in the MKKS gene have been identified. Each of these mutations changes a single amino acid in the MKKS protein. One mutation replaces the amino acid histidine with tyrosine at protein position 84. The other mutation replaces the amino acid alanine with serine at protein position 242. These mutations alter the structure of the MKKS protein that disrupts the development of several parts of the body before birth. The structure of this protein suggests that it may act as a chaperone, which is a protein that helps fold other proteins. It is however unclear how MKKS mutations lead to the specific features of this disorder. ^(2,3)

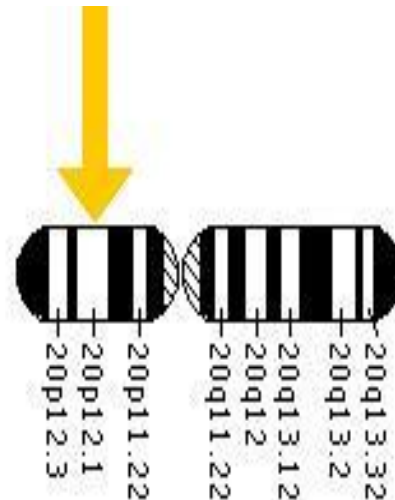


Figure no 8: The MKKS gene is located on the short (p) arm of chromosome 20 at position 12.

Signs and symptoms of MKKS overlap significantly with those of another genetic disorder, called Bardet-Biedl syndrome (BBS). Children diagnosed with BBS, require close follow up for the development of retinal dystrophy, obesity and learning difficulties which are the main clinical features of Bardet-Biedl syndrome. ^(1,4) Despite the similarity of the two

syndromes, especially in early childhood, it is important to distinguish them and avoid premature misdiagnosis. MKKS has a favourable prognosis than BBS. (5)

A surgical management option for urogenital sinus depends on the level of the confluence of the sinus. Low confluences can be managed by Partial urogenital mobilization (PUM) where of the mobilization is carried out until the pubo-urethral ligament. In high confluence sinus; total urogenital mobilization (TUM), Pull through vaginoplasty, vaginal replacement with colon/ileum could be the surgical options.

CONCLUSION

MKKS is rare autosomal recessive disorder which presents with polydactyly, congenital heart defects and genito-urinary abnormalities.

Treatment of the genito-urinary abnormalities could be carried out primarily or as staged procedures. In this case a primary vaginostomy was done to relieve vascular and renal compression. A secondary repair of the urogenital sinus by a perineal approach with an inverted U-shaped incision can be done. A Fogarty catheter introduced through the common channel can

aid in identifying the dilated proximal vagina to separate it from the urogenital sinus and transpose it posteriorly.

Conflict Of Interest: None.

REFERENCES

1. David A, Bitoun P, Lacombe D. Hydrometrocolpos and polydactyl: a common neonatal presentation of Bardet-Biedl syndrome and McKusick-Kaufman Syndromes. *J Med Genetics*. 1999; 36:599-603.
2. Chitayat D, Hahm SYE, Marion RW. Further delineation of the McKusick-Kaufman hydrometrocolpos- polydactyl syndrome. *American J Dis Child*. 1987; 141:1133-6.
3. Slavotinek AM, Pagon RA, Bird TD, Dolan CR, Stephens K, Adam MP. *Gene Reviews- McKusick-Kaufman Syndrome*. 2010.
4. Slavotinek AM, Biesecker LG. Phenotypic overlap of McKusick-Kaufman Syndrome with Bardet-Biedl syndrome: a literature review. *American J Med genetics*. 2000; 95:208-15.
5. Ross Allison, PL Beales, J Hill. The Clinical, Molecular and Functional Genetics of Bardet-Biedl Syndrome. *Genetics of Obesity Syndromes (Oxford University Press)*.2008:153-4.

How to cite this article: Hathiramani V, Raj V, Swathi C et. al. A case of McKusick-Kaufman syndrome with urogenital sinus . *Int J Health Sci Res*. 2015; 5(8):635-639.
