

*Case Report*

## Unilateral Triple Renal Veins with Anomalous Drainage of Right Testicular Vein: A Rare Case Report

Anita S. Fating

Associate Professor, Dept. of Anatomy, Padmashree Dr. Vithalrao Vikhe Patil Foundations's Medical College, Vadgaon Gupta, Ahmednagar, M.H. (India)

*Received: 06/07/2015**Revised: 21/07/2015**Accepted: 22/07/2015*

### ABSTRACT

Routine dissection of a 69 year old male cadaver revealed complex anatomical renal venous variation. Presence of triple right renal veins, nominated as SRRV (superior right renal vein), MRRV (middle right renal vein) & IRRV (inferior right renal vein). Also there was common opening of IRRV & RTV (right testicular vein) into IVC (inferior vena cava). Related literatures were reviewed & their implications during renal surgeries were discussed.

Misdiagnosis of venous anomalies can have disastrous consequences. Preoperative planning is must before any surgical interventions such as renal transplants, conservative or radical renal surgery, vascular reconstructions for congenital and acquired lesions, nephrectomies and trauma management to avoid pre and post operative complications. Knowledge of such variation is thus important for surgeons, radiologists & urologists.

**Key words:** Triple right renal veins, Renal transplants, Vascular reconstructions, Nephrectomies

### INTRODUCTION

The venous drainage of each kidney is through single renal vein, which drains the blood from the kidney into the inferior vena cava at right angle. The renal vein is formed near the hilum in front of the renal artery. The right renal vein is shorter (2-4 cm) than the left (6-10 cm). It receives blood only from the right kidney, whereas the left renal vein receives blood not only from the left kidney but also from left adrenal and left testis. The most common spinal level for renal veins is between the first and second lumbar vertebra.

Renal vessels, especially arteries, exhibit a high degree of variations (8.7%-

75.7%) <sup>[1]</sup> as compared to the renal veins (incidence - 0.8 to 6%). <sup>[2]</sup>

The objective of the case report and review of literature is to bring awareness to clinicians about the variations in the renal vasculature especially those who are performing invasive procedures and renal vascular surgeries.

### CASE REPORT

While carrying out routine dissection of the retroperitoneal region of a 69 years old male cadaver for MBBS, we came across renal venous anomalies. The right kidney was drained by three renal veins, nominated as SRRV (superior right renal vein), MRRV (middle right renal vein) &

IRRV (inferior right renal vein) as shown in figure. All veins emerged from hilum of right kidney & drained separately into inferior vena cava.

The SRRV emerged from upper part of hilum of right kidney, crosses MRVV anteriorly, courses superomedially, crossing right renal artery anteriorly and drained into the inferior vena cava at an acute angle at the same level as that of the left renal vein. The MRRV emerged from middle part of hilum of right kidney, posterior to SRRV, courses horizontally behind segmental artery. It drained into the inferior vena 1.5 cm below that of SRRV.

The IRRV, largest in caliber, emerged from lower part of hilum of right kidney, crossing uretero-pelvic junction, courses superomedially & drained into the IVC (inferior vena cava) along with RTV (right testicular vein), 0.5 cm below that of MRRV.

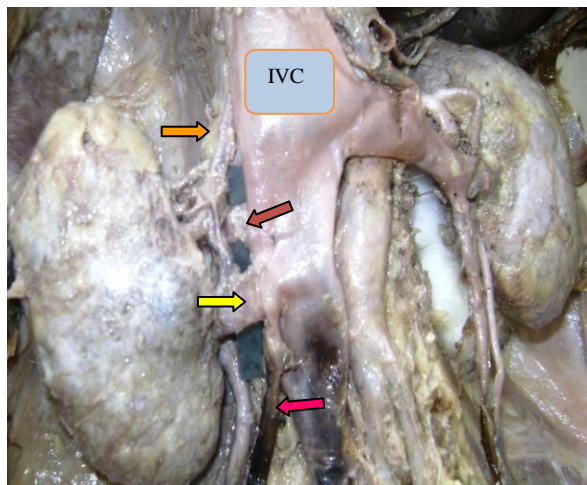


Figure showing SRRV (Superior right renal vein) →. MRRV (Middle right renal vein) ←. IRRV (Inferior right renal vein) →. RTV (Right testicular vein) ←. IVC-Inferior vena cava

## DISCUSSION

The right renal vein is usually a single vessel, formed near the hilum in front of the renal artery. It describes a horizontal

course toward the inferior vena cava, in which it drains.

For most part of the body, variations or anomalies of veins are far more frequent than those of arteries, but this is not true of the vascular pedicle of kidney. Supernumerary veins are present in 14.4% and supernumerary arteries are present in 32.25% of the kidneys. [3] Bergman et al. pointed that, the renal veins show less variation than do the renal arteries. [4]

Presence of multiple renal veins (more than 2 veins) has been found to be more common on right side. [3,5,6,7] Presence of multiple right renal veins was found in about 8.0% to 9.7% of cases. [8] Pick & Anson reported 27.8% additional veins on right side. [3] Pollak et al [6] also observed that additional renal veins and other venous variations are more common on the right side.

Kaneko et al. from their study of 170 cases, found that multiple renal veins were present in 22 cadavers (12.9%), and bilateral multiple veins were observed in 1 cadaver (0.6%). [9]

**Presences of additional renal veins are more common on right side as compared to left side:**

Author	Right renal veins	Left renal veins
Bergman [4]	28%	1%
Sampio [10]	3.3%	2.6%
Janschek [5]	23%	6.7%
Satyapal [11]	26%	2.6%

Presence of double right renal veins has been reported by many. [12,13,14,15]

Presence of triple right renal veins has been reported by many. [8,14,16,17]

Sudeshna Majumdar et al reported presence of bilateral double renal veins in a 70 year old male cadaver. The right testicular vein drained into the inferior vena cava at an acute angle at the point of entry of the right renal vein into the inferior vena cava. [18] In present case instead of double, there were triple right renal veins and the

drainage of RTV was at the point of entry of the IRRV into inferior vena cava.

Vijisha Phalgunan et al reported presence of additional right renal veins (triple-5%, double-5%), further they quoted drainage of right testicular veins into right renal vein (10%) after studying 20 cadavers. [14]

Ross et al [19] emphasized the importance of such variations. Surgeon should be aware with the anatomical variants of cadaver kidneys procured for renal transplantations. They commented that incidence of additional renal vein may contribute to the criteria adopted to select a donor kidney suitable for transplantation. Additional renal veins are capable of providing an alternative route of venous drainage due to rich, free intra-renal anastomoses.

Sharmishta Biswas reported an additional right renal vein in which RTV drains in one out of twenty cadavers(10%). [15] The right testicular vein is a tributary of the inferior vena cava. Variations of the right testicular vein are very rare. Variations of gonadal veins were more frequent on the left side, as observed by Asala et al. [20] they found only 2 cases of right gonadal vein draining into right renal vein out of 150 cadavers dissected.

The testes are important organs whose veins and arteries play major role in their thermo-regulation that is essential for efficient functioning of the organs. Thus variations of testicular venous drainage are very significant while performing surgery or radiology. During endo-urological procedures, anatomical variations of renal and gonadal veins have got immense significance, as lesions in them may cause severe back bleeding during and after surgery.

A significant finding in the present case is drainage of RTV & IRRV into IVC through single opening.

**Embryological explanation:** On either side of bilaterally symmetrical cardinal venous system, two renal veins are arranged on ventral & dorsal plane around 8th week. With further development, the bilateral cardinal venous system becomes unilateral right sided inferior vena cava; meanwhile there occurs confluence of the two tributaries to form a single vein. Failure of this process results into formation of additional right renal veins as might have occurred in the present case. Presence of any additional left renal veins is discouraged by venous shift. Due to this additional renal veins are more common on right side.

Gonadal veins develops from caudal part of sub-cardinal veins & drains into supra-subcardinal anastomosis, which incorporated into formation of inferior vena cava only on right side, so right gonadal vein drains into inferior vena cava . But in present study, supra-subcardinal anastomosis might have contributed in formation of both, terminal part of IRRV as well as IVC, resulting into common drainage of IRRV & RTV into IVC.

The anatomical knowledge of the renal veins and its variations are of extremely valuable for the surgeon that approaches the retroperitoneal region, mainly in face of the current frequency of the renal transplant surgeries, vascular reconstructions and various surgical and radiological techniques as well as, this anatomical variations should be kept in mind by clinicians and academics that may manipulate this anatomical area. It also facilitates a safe approach to the kidneys in trauma management. [9]

As far as renal vein variations are concerned, most of them remain unnoticed until discovered during venography, operation or autopsy as they are clinically silent. However, to a transplant surgeon, morphology acquires special significance, since variations influence technical

feasibility of the operation. In addition to other variations, the level of entry of renal veins into the IVC is also important as these findings are clinically important for the angiographer, catheter design, and planning porto-renal shunt procedures. During such procedures, cases similar to the one reported here (triple renal veins, opening into IVC at different points & common entrance of RTV & IRRV into IVC) also must be kept in mind.

Presence of triple right renal vein & drainage of RTV into right renal vein has been reported by many authors but the common entrance of IRRV & RTV into the inferior vena cava has been rarely reported till date as far as my knowledge. Thus, offering unique feature to this case report. Such a rare variation should be kept in mind by clinicians. It is pertinent to surgeons & clinicians should be kept in mind by clinicians. It is pertinent to surgeons & clinicians to have in-depth knowledge of renal vascular anatomy so as to avoid damage & bleeding during surgical procedures.

## REFERENCES

1. Edman G. Accessory vessels of the kidney and their diagnosis in hydronephrosis. *Acta Radiol Stockh.* 1954; 42: 26-32.
2. Campbell MF. Anomalies of kidney. In: Campbell MF, Harrison JS, eds. *Urology.* 3rd ed. Vol. 2. W.B. Saunders: Philadelphia; 1970. p. 1416-86.
3. Pick JW, Anson BJ. The renal vascular pedicle. An anatomical study of 430 bodyhalves. *J Urol.* 1940; 44: 411-434.
4. Bergman RA, Thompson SA, Afifi AK & Saadeh FA. *Compendium of Human Anatomic variation: catalog, Atlas and World Literature.* 2nd ed. Urban and Schwazenberg, Baltimore and Munich, 1988; 81-82
5. Janschek Ec, Rothe Au, Holzenbein Tj, Langer F, Brugger Pc, Pokorny H,

- Domenig Cm, Rasoulrockenschaub S, Muhlbacher F, Anatomic basis of right renal vein extension for cadaveric kidney transplantation, *Urology,* 2004; 63(4):660-664.
6. Pollack, R, Prusak BF and Mozes MF. Anatomic abnormalities of cadaver kidneys procured for purpose of transplantation. *Am. Surgeon.* 1986; 52:233-235.
7. Nayak BS. Multiple variations of the right renal vessels. *Singapore Med J.* 2008; 49:153- 155.
8. Baptista - Silva, J.C., Verissimo, M.J. & Castro, M.J., Camara, A.L. & Pestana, J.O. Anatomical study of the renal veins observed during 342 living -donor nephrectomies. *Rev. Paul. Med.* 1997; 115 (3): 1456-1459.
9. Kaneko N, Kobayashi Y, Okada Y. Anatomic variations of the renal vessels pertinent to transperitoneal vascular control in the management of trauma. *Surgery.* 2008; 143: 616-622.
10. Sampio FJ, Passos MA. Renal arteries: anatomic study for surgical and radiological practice. *Surg Radiol Anat.* 1992; 14:113-117.
11. Satyapal KS, Rambiritch V, Pillai G. Additional renal veins: incidence and morphometry. *Clin Anat.* 1995; 8: 51-55.
12. Vanita Gupta, Sheetal Kotgirwar, Soumitra Trivedi and et al. Bilateral variations in renal vasculature. *International Journal of Anatomical Variations.* 2010; 3: 53-55
13. Narendiran Krishnasamy, Mohardan Rao KG and et al: An unusual case of unilateral additional right renal artery and vein. *International Journal of Anatomical variations,* 2010; 3: 9-11.
14. Vijisha Phalgunan, N Mugunthan and et al. A study of renal and gonadal vein variations. *National Journal of Clinical Anatomy.* 2012;1(3): 125-128
15. Sharmistha B, Chattopadhyay JC, Panicker H and et al. Variations in renal and testicular veins-a case report. *J Anat Soc India.* 2006;55(2):69-71

16. Fernandes, R.M.P., Conte, F.H.P., Favorito, L.A., Abidu - Figueiredo, M - & Babinski, M.A. Triple right renal vein: An uncommon variation. Int .J. Morphol 2005;23(3):231-233.
17. Gyan Prakash Mishra, Shobha Bhatnagar, Brijendra Singh. Unilateral triple renal veins and bilateral double renal arteries- A unique case report. Int J Anat Res 2014; Vol 2(1):239-41
18. Sudeshna Majumdar, Sibani Mazumder, Hironmoy Roy and et al. A case of bilateral double renal veins. International Journal of Anatomical Variations. 2013; 6: 61-63
19. Ross JA, Samuel E and Miller DR. Variations in the renal vascular pedicle (an anatomical and radiological study with particular reference to renal transplant). Br.J.Urol.1961;33:478-485
20. Asala S, Chaudhary SC, Masumbuko-Kahamba N, Bidmos M. Anatomical variations in the human testicular blood vessels. Ann Anat 2001; 183:545-9.

How to cite this article: Fating AS. Unilateral triple renal veins with anomalous drainage of right testicular vein: a rare case report. Int J Health Sci Res. 2015; 5(8):622-626.

\*\*\*\*\*

#### **International Journal of Health Sciences & Research (IJHSR)**

#### **Publish your work in this journal**

The International Journal of Health Sciences & Research is a multidisciplinary indexed open access double-blind peer-reviewed international journal that publishes original research articles from all areas of health sciences and allied branches. This monthly journal is characterised by rapid publication of reviews, original research and case reports across all the fields of health sciences. The details of journal are available on its official website ([www.ijhsr.org](http://www.ijhsr.org)).

Submit your manuscript by email: [editor.ijhsr@gmail.com](mailto:editor.ijhsr@gmail.com) OR [editor.ijhsr@yahoo.com](mailto:editor.ijhsr@yahoo.com)