



Short Communication

## Prevalence of Ossified Superior Transverse Scapular Ligament in South Indian Population

Moula Akbar Basha<sup>1\*</sup>, Raju Sugavasi<sup>1\*\*</sup>

<sup>1</sup>Assistant Professor,

<sup>\*</sup>Department of Anatomy, Viswabharathi Medical College, R.T Nagar, Penchikapadu, Kurnool A.P. India.

<sup>\*\*</sup>Department of Anatomy, Fathima Institute of Medical sciences, Kadapa A.P. India.

Corresponding Author: Moula Akbar Basha

Received: 16/06/2015

Revised: 09/07/2015

Accepted: 14/07/2015

### ABSTRACT

**Aim:** Objectives of the selected study is to make out the Prevalence of the ossification of superior transverse scapular ligament in dry scapulas in south Indian population.

**Materials & Methods:** Total number of 200 adult scapulas was selected for this study to find out the ossified superior transverse scapular ligament. Results: Complete ossified superior scapular ligament of scapulas were found 3 out of 200 scapulas and prevalence is 1.5%.

**Conclusion:** occasionally this abnormal ossification may entrap the supra scapular nerve may produce related symptoms.

**Keywords:** Superior transverse scapular ligament, ossification, scapula.

### INTRODUCTION

Superior transverse scapular ligament bridges over the supra scapular notch of scapula, so it transformed into a supra scapular foramen through which the supra scapular nerve passing through it. Superior transverse scapular ligament which is attached laterally to the root of the coracoids process and medially to the limit of the notch, this ligament is occasionally ossified. <sup>[1]</sup> Complete ossification of Superior transverse scapular ligament may generate entrapment of supra scapular nerve, which consequences pain in the shoulder region, wasting and weakness of the scapular muscles especially supra and infra spinatus. <sup>[2]</sup>

### MATERIALS & METHODS

The present study was conducted on 200 adult, unknown sexes, dried human scapulas. Scapulas were collected from various medical institutions in south Indian region from Departments of Anatomy, Viswa Bharathi Medical College, Kurnool, Fathima Institute of Medical sciences (FIMS), Kadapa and Rajiv Gandhi Institute of Medical sciences (RIMS), Kadapa, Andhra Pradesh, India. Collected scapulas were carefully observed for ossified superior transverse scapular ligament.

### RESULTS

Present study found that, ossified superior transverse scapular ligaments

completely in 3 Scapulas among 200 specimens. 2 scapula right side (FIG: 01, 02) and 1 scapula left side (FIG: 03) showed complete ossification. Study shows the prevalence of ossified superior transverse scapular ligaments is 1.5% in south Indian population.

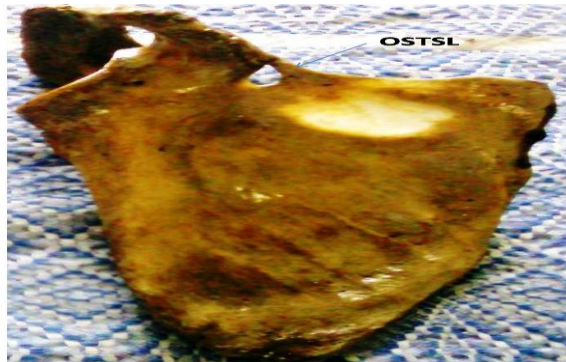

FIG: 01: Shows Right side (OSTSL) Ossified Superior Transverse Scapular ligament.

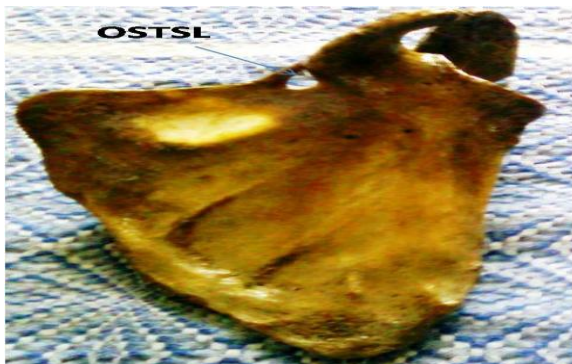

FIG: 02: Shows Right side (OSTSL) Ossified Superior Transverse Scapular ligament

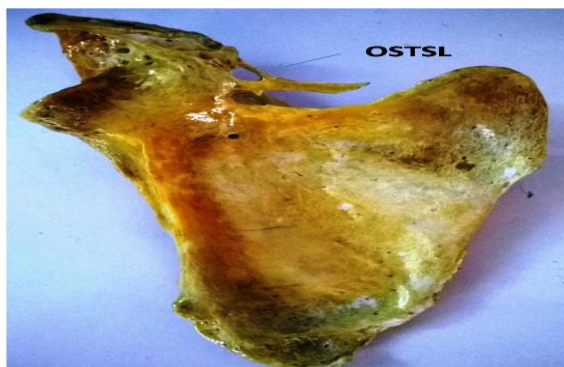


FIG: 03: Shows Left side (OSTSL) Ossified Superior Transverse Scapular ligament

## DISCUSSION

The incidences of ossified superior transverse scapular ligaments in various populations were showed in previous literatures. According to Ticker et al (1998) prevalence in American population was 5%,<sup>[3]</sup> Urgudin et al (2004) in Turkish 6%,<sup>[4]</sup> Silva et al (2007) in Brazilian 30.6%,<sup>[5]</sup> Sinkeet et al (2010) in Kenyan 3%,<sup>[5]</sup> Wang et al (2011) in Chinese 4.08%,<sup>[6]</sup> Polugj et al (2011) in Polish 7%,<sup>[8]</sup> Zahid A et al (2014) in Pakistani 1.96%.<sup>[9]</sup> According to Jadhav et al (2012)<sup>[10]</sup> Prevalence in Indian population was 10.57%. Khan, M.A (2006)<sup>[11]</sup> observed, Ossification of the Superior Transverse Scapular Ligament Completely in an Adult Male Indian.

Srijit Das et al (2007)<sup>[12]</sup> found the present variation in one scapula in India.

## CONCLUSION

Complete ossified superior transverse scapular ligament constructs, the bony foramina is the most familiar contributing factor for the compression of supra scapular nerve at the supra scapular notch which develops suprascapular nerve entrapment syndrome. The present study indicates that complete ossification of Superior transverse scapular ligament can arise in south Indian population is 1.5% and further studies are required to determine its prevalence in India.

## REFERENCES

1. Standring S, Ellis H, Healy J, Johnson D, Williams A. Pectoral girdle, shoulder region and axilla. In: Standring S, ed. Gray s Anatomy – The Anatomical Basis of Clinical Practice. Elsevier Churchill Livingstone: NewYork; 2005: P p. 796.
2. Tubbs RS, Nechtman C, D Antoni AV, Shoja MM, Mortazavi MM, Loukas M, Rozzelle CJ, Spinner RJ. Ossification of the suprascapular ligament: A risk factor for supra scapular nerve compression. Int J Shoulder Surg. 2013; 7 (1): 19-22.

3. Ticker JB, Djurasovic M, Strauch RJ, April EW, Pollock RG, Flatow EL, Bigliani LU. The incidence of ganglion cysts and other variations in anatomy along the course of the supra scapular nerve. *J Shoulder Elbow Surg.* 1998; 7: 472-478.
4. Urguden M, Ozdemir H, Donmez B, Bilbasar H, Oguz N. Is there any effect of supra scapular notch type in iatrogenic suprascapular nerve lesions. An anatomical study. *Knee Surg Sports Traumatol Arthrosc.* 2004; 12: 241–5.
5. Silva JG, Abidu-Figueiredo M, Fernandes RMP, Aureliano- Rafael F, Sgrott EA, Silva SF, Babinski MA. High incidence of complete ossification of the superior transverse scapular ligament in Brazilians and its clinical implications. *Int. J. Morpho.* 2007; vol. 25, No. 4: pp. 855–859.
6. Sinkeet SR, Awori KO, Odula PO, Ogeng'o JA, Mwachaka PM. The suprascapular notch: its morphology and distance from the glenoid cavity in a kenyan population. *Folia Morphologica,* 2010; 69 (4): 241–245.
7. Wang HJ, Chen C, Wu LP, Pan CQ, Zhang WJ, Li YK. Variable morphology of the supra scapular notch: an investigation and quantitative measurements in Chinese population. *Clin Anat.* 2011; 24 (1): 47–55.
8. Polguy M, Jędrzejewski K, Podgórski M, Topol M. Morphometric study of the suprascapular notch: proposal of classification. *Surg Radiol Anat.* 2011 Nov; 33 (9): 781-7.
9. Zahid A, Khan M.W, Khan B. Ossified superior transverse scapular ligament: a morphological study on dried pakistani scapulae. *Biomedica.* 2014; 30(3). 1- 4.
10. Jadhav SD, Patil RJ, Roy PP, Ambali MP, Doshi MA, Desai RR. Supra-scapular foramen in Indian dry scapulae. *NJCA.* 2012; 1 (3): 133-135.
11. Khan, M. A. Complete Ossification of the Superior Transverse Scapular Ligament in an Indian Male Adult. *Int. J. Morphol.* 2006; 24(2):195-196.
12. Srijit Das, Rajesh Suri and Vijay Kapur. Ossification of Superior Transverse Scapular Ligament and its Clinical Implications. *Sultan Qaboos University Medical Journal.* 2007; 7 (2): 157-160.

How to cite this article: Basha MA, Sugavasi R. Prevalence of ossified superior transverse scapular ligament in south Indian population- research article. *Int J Health Sci Res.* 2015; 5(8):534-536.

\*\*\*\*\*