



Case Report

Diagnosis of Toxoplasma Lymphadenitis with Demonstration of Toxoplasma Bradycyst on FNA Cytology: A Rare Finding

Kanthilatha Pai¹, Swati Sharma¹, Tanvi Shetty²

¹Department of Pathology, Kasturba Medical College, Manipal University, Manipal

²Department of Pathology, Melaka Manipal Medical College, Manipal University, Manipal

Corresponding Author: Swati Sharma

Received: 28/01/2015

Revised: 21/02/2015

Accepted: 24/02/2015

ABSTRACT

Diagnosis of toxoplasma lymphadenitis with demonstration of toxoplasma bradycyst is a feature rarely described in literature. We report a case of toxoplasma lymphadenitis in a 36 year old female who presented with cervical lymphadenopathy and fever, in whom FNA cytology revealed toxoplasma bradycyst, suggesting a diagnosis of toxoplasma lymphadenitis. This was confirmed by positive toxoplasma serology.

Key words: Toxoplasma, lymphadenitis, bradycyst

INTRODUCTION

The diagnosis of toxoplasmosis can be made on fine needle aspiration cytology or tissue biopsy and serological assays detecting antibodies against the parasite. Serology may be negative in immunocompromised patients. There are only few reports of toxoplasma lymphadenitis diagnosed by FNAC, with serology in literature.

CASE REPORT

A 36 year old female presented with enlarged lower cervical lymph nodes since 2 months. There was occasional history of low grade fever since 2 weeks. No history of cough or other systemic symptoms were

present. On clinical examination, there was left cervical lymphadenopathy, which were multiple, mobile, nontender and largest measuring 1.5cm × 2.0 cms. Clinical suspicion of tuberculosis was made and FNA was performed. The smears were stained with Papanicolaou stain. The smears were cellular and showed polymorphous population of lymphoid cells in varying stages of maturation with numerous tingible body macrophages, few clusters of plump macrophages and epithelioid cells. (Fig 1a, and 1b)

A single large round bradycyst containing numerous crescentic bradyzoites was seen on Papanicolaou stained smear. (Fig 2a and 2b)

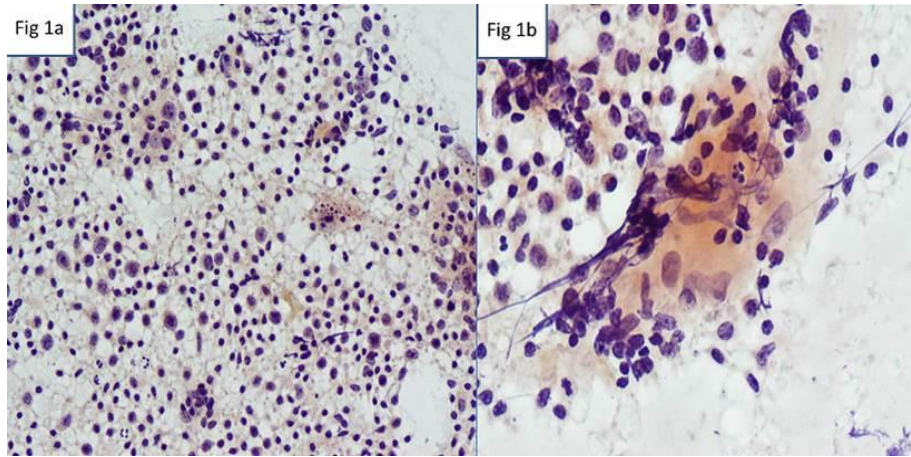


Figure 1a- Polymorphous population of lymphoid cells with tingible body macrophages PAP X100
 Figure 1b- Clusters of macrophages and epithelioid cells PAP X400

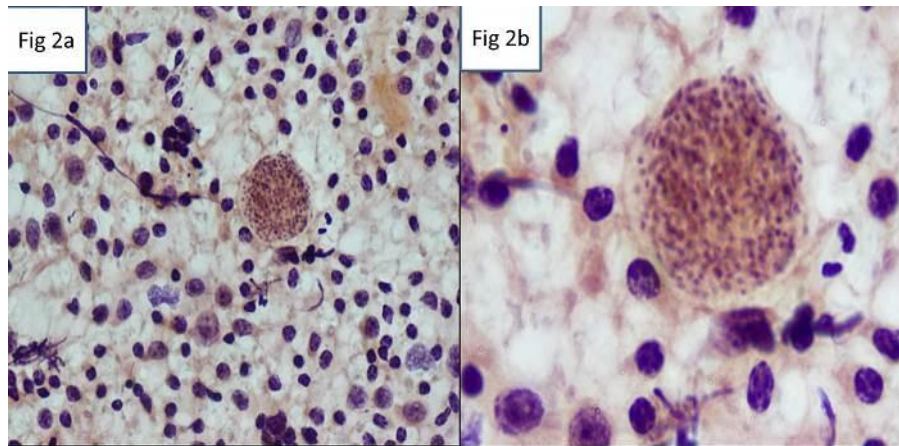


Figure 2a- Round bradycyst containing numerous crescentic bradyzoites PAP X200
 Figure 2b- Round bradycyst containing numerous crescentic bradyzoites PAP X1000

There was no evidence of necrosis, suppuration or giant cell reaction in the background. A diagnosis of *Toxoplasma* lymphadenitis was made, and serological confirmation was requested. *Toxoplasma* specific IgM and IgG levels were performed by ELISA method. The serological test revealed IgG – specific antibody to *T. gondii* at a level was 300 IU/ mL (normal < 10 IU/mL) and IgM specific antibody at a level of 0.90 IU/ mL (normal < 0.56 IU/mL), confirming the diagnosis of *Toxoplasma* lymphadenitis.

DISCUSSION

Toxoplasmosis is caused by *Toxoplasma gondii*, a ubiquitous protozoan

that can infect animals and humans. It exists in three forms: Ova, tachzoites and tissue cyst, the ova are shed in cat feces and are infective. This infection is particularly common in regions with warm and humid climates. Humans acquire *Toxoplasma gondii* infection by ingesting food and water contaminated with oocysts shed in feces of infected cats or by ingesting tissue cysts in undercooked infected meat. The clinical presentation of toxoplasmosis ranges from being asymptomatic to fever and lymphadenopathy to diffuse organ system involvement depending on the immunity of the host. In immunocompetent hosts, toxoplasmosis most often presents as asymptomatic cervical lymphadenopathy.

Cytological features of Toxoplasma lymphadenitis include high cellularity with polymorphous population of reactive lymphoid cells, tingible body macrophages, clusters of epithelioid cells, focal aggregates of monocytoïd cells with or without necrosis. [1] Different diagnostic approaches have been put forward for giving a definitive diagnosis of toxoplasmosis. [2] Microgranulomas composed of few pale histiocytes accompanied by lymphocytes are suggested to be pathognomonic. [3] Presence of reactive hyperplasia with intracytoplasmic organism (crescentic, rounded, cup shaped organisms and somewhat cystic in nature) in histiocytes is considered to be highly indicative of Toxoplasmosis. However, it is reported that tissue cyst is very rarely seen on tissue sections (<1%) and even more rarely in cytology smears. [4,5] Serological confirmation is mandatory in doubtful cases. It is important to differentiate the tissue cyst of *Toxoplasma gondii* from other cysts which appear similar in size and appearance like sarcocystis, isospora, microsporidia, leishmania and pneumocystis by clinical correlation and special stains.

CONCLUSION

FNA is a useful tool in the evaluation of lymphadenopathy and in the diagnosis of Toxoplasma lymphadenitis, though demonstration of the tissue cysts has been rarely reported in literature. It can eliminate the need for more invasive lymph node excision in the evaluation of

lymphadenopathy to rule out other serious causes like tuberculosis, lymphoma, metastatic carcinoma etc. Serological studies are useful adjunct in confirming the diagnosis.

REFERENCES

1. Argyle JC, Schumann GB, Kjeldsberg CR, Athense JW. Identification of a toxoplasma cyst by fine-needle aspiration. Am J Clin Pathol. 1983;80:256-8
2. Jayaram N, Ramaprasad AV, Chetan M, Sujay AR. Toxoplasma lymphadenitis: Analysis of cytologic and histopathologic criteria and correlation with serologic test. Acta Cytol. 1997;41:653-8
3. Zaharopoulos P. Demonstration of parasites in toxoplasma lymphadenitis by fine-needle aspiration cytology: report of two cases. Diagn Cytopathol. 2000;22(1):11-5
4. Pathan SK, Francis IM, Das DK, Mallik MK, Sheikh ZA, Hira PR. Fine needle aspiration cytologic diagnosis of toxoplasma lymphadenitis. A case report with detection of a Toxoplasma bradycyst in a Papanicolaou-stained smear. Acta Cytol. 2003;47(2):299-303
5. Viguer JM, Jiménez-Heffernan JA, López-Ferrer P, González-Peramato P, Vicandi B. Fine needle aspiration cytologic diagnosis of toxoplasma lymphadenitis. A case report with detection of a Toxoplasma bradycyst in a Papanicolaou-stained smear. Acta Cytol. 2005;49(2):139-43.

How to cite this article: Pai K, Sharma S, Shetty T. Diagnosis of toxoplasma lymphadenitis with demonstration of toxoplasma bradycyst on FNA cytology: a rare finding. Int J Health Sci Res. 2015; 5(3):437-439.
