

*Case Report*

“Lateral Orbital Rim Osteotomy-Approach” for Management of Blow-in Fracture of Lateral Orbit Wall Causing Visual and Ocular Motility Disturbances: Report of Two Cases

Vinayak Vishnu Raje¹, Kumar Nilesh²¹Associate Professor, Dept. of Neurosurgery, Krishna Institute of Medical Sciences Deemed University, Karad.²Reader, Department of Oral & Maxillofacial Surgery, School of Dental Sciences, KIMSDU, Karad, India.

Corresponding Author: Kumar Nilesh

Received: 27/01/2015

Revised: 20/02/2015

Accepted: 20/02/2015

ABSTRACT

Lateral wall of orbit is formed by orbital process of zygomatic bone anteriorly and the greater wing of the sphenoid posteriorly. It is strongest among other orbital walls and is protected by thick lateral orbital rim. Fracture of the lateral orbital wall is uncommon, and is seen in cases of severe facial trauma, when forceful impact is directed over the orbital skeleton. Blow-in fracture of lateral orbital wall is rare and is commonly associated with zygomatico-malar complex (ZMC) fractures.

We report two cases of blow-in fracture of lateral orbital wall. Both the cases presented with visual and ocular motility disturbance. The cases were surgically accessed by lateral orbital rim osteotomy-approach. The aim of presenting these case reports is its rarity and the different modality used for its successful management.

Key words: Lateral wall, orbit, blow-in fracture, Osteotomy

INTRODUCTION

Fractures of the lateral orbital wall usually occur at the speno-zygomatic suture line. Patients with lateral orbital wall fractures usually present with peri-orbital swelling and ecchymosis along with variable degrees of mid-face deformity. Fortunately, visual disturbance and restriction of ocular movement rarely occur with isolated lateral orbital wall fracture. However, with the increase in the severity and posterior-medial displacement of the lateral orbital wall fracture, the risk of the life-threatening intracranial injuries, injury to the orbital portion of the cranial nerves, and rupture

globe increases. Loss of vision is a rare complication of facial fracture, with reported incidence of 3%.^[1] Visual disturbances may occur due to globe injury or injury to optic nerve. Indirect injury to the intracanalicular portion of the optic is most common mechanism of optic nerve related visual loss.^[2] Retrobulbar hemorrhage, penetrating foreign body and bony fragment impinging on the optic nerve are other causes of optic nerve injury. Medially displaced fractured fragments of the orbital wall can impinge over the extraocular muscles causing mechanical obstruction in ocular movements. Imaging studies with computed

tomography is important in the proper diagnosis and planning of the surgical intervention. Management of these orbital fractures should be undertaken on emergent basis to prevent further damage and early return of function.

This paper reports two cases of blow-in fracture of lateral orbital wall presenting with visual and ocular motility disturbance. Both the cases were successfully managed by removal of impinging bone fragments by lateral orbital rim osteotomy approach.

CASE REPORTS

Case 1

A 34-year-old man was admitted to the neurosurgery department with facial trauma after road traffic accident. After the initial emergency management, the patient was assessed clinically and radiologically for facial and orbital injuries. Soft-tissue swelling, circum-orbital ecchymosis, sub-

conjunctival hemorrhage, and tenderness were present over the left orbit. The patient reported loss of vision with left eye. On ophthalmologic examination, the left globe position was normal and symmetric, with loss of visual acuity and restricted extra-ocular motion on lateral gauge. An afferent papillary defect of left eye was present. Distortion of lateral orbital wall precluded meaningful exophthalmometry reading. Infra-orbital nerve sensation was intact over mid-face region. The right eye examination was within normal limits.

Computed Tomography (CT) of the cranial, orbital and facial skeleton was obtained, which revealed blow-in fracture of left lateral orbital wall with two medially displaced fractured fragments impinging on lateral rectus and globe (Figure 1). No intracranial lesion was seen. There was no evidence of reterobulbar hemorrhage and optic rim involvement.

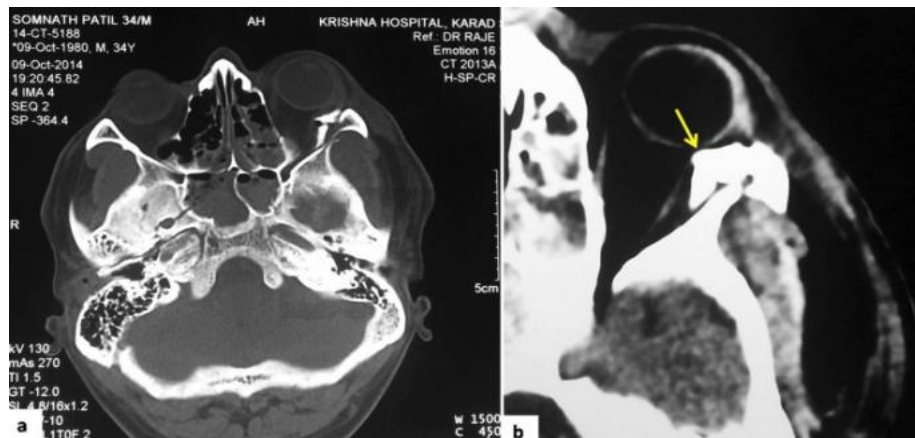


Figure 1: CT (axial cuts) scan (a) showing blow-in fracture of left lateral wall of orbit (b) medially displaced fractured bone fragments impinging on lateral rectus and globe (arrow).

Patient was immediately put on megadose steroid (with a loading dose of 30mg/kg IV methylprednisolone, followed by 15mg/ kg 2 hours later and 15mg/kg every 6 hourly). With no improvement in orbital signs after six doses, removal of the impinging bone fragments was planned under general anesthesia. Extended lateral

eyebrow incision was used for exposure of the surgical site. Lateral orbital rim osteotomy was used to gain access to the lateral orbital wall. The osteotomy cuts were placed at level of fronto-zygomatic suture above and inferior extent of lateral orbital rim below (Figure 2a). The rim was removed and stored in normal saline, while

the impinging bony fragments were removed (Figure 2b). The lateral rim was placed back and fixated with 2mm titanium plate and screws (Figure 2c). The patient

had uneventful post-operative period with complete recovery of vision and ocular movements.

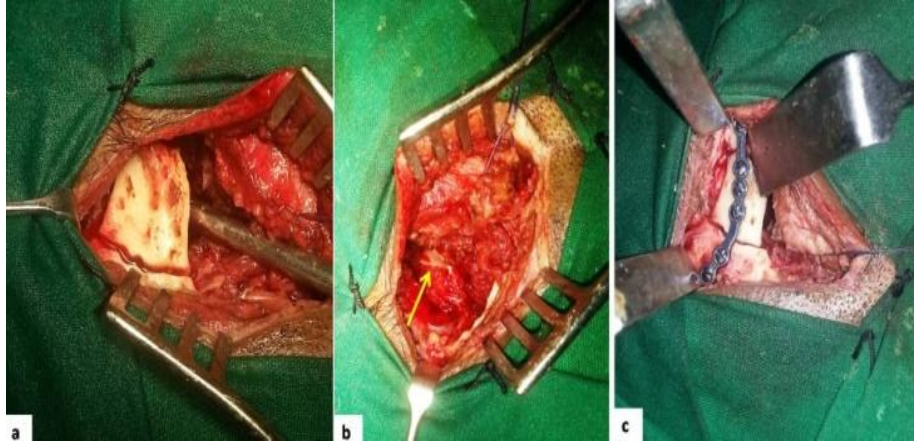


Figure 2: Surgical steps in removal of the impinging bone fragments (a) the ostotomy cuts placed at level of fronto-zygomatic suture above and inferior extent of lateral orbital rim below (b) medially displaced bone piece located and removed (c) lateral orbital rim placed back and fixed using titanium miniplate.

Case 2

A 53 year old female who had survived road traffic accident was referred to our hospital for management of cranio-facial injuries. Once the patient's general condition was stable, a detailed history regarding the type and the severity of the trauma was obtained. Careful clinical and radiological evaluation was done and intracranial trauma was ruled out. Patient complained of blurring of vision and eye pain with right eye. On ophthalmological

evaluation of right eye there was loss of visual acuity and restricted extra-ocular motion on lateral gauge. The pupillary reflex was found to be normal with both eyes.

Computed Tomography (CT) with three dimensional reconstruction of the orbit showed blow-in fracture of right lateral orbital wall with medially displaced fractured fragments impinging on lateral rectus (Figure 3). CT brain showed no intracranial changes.

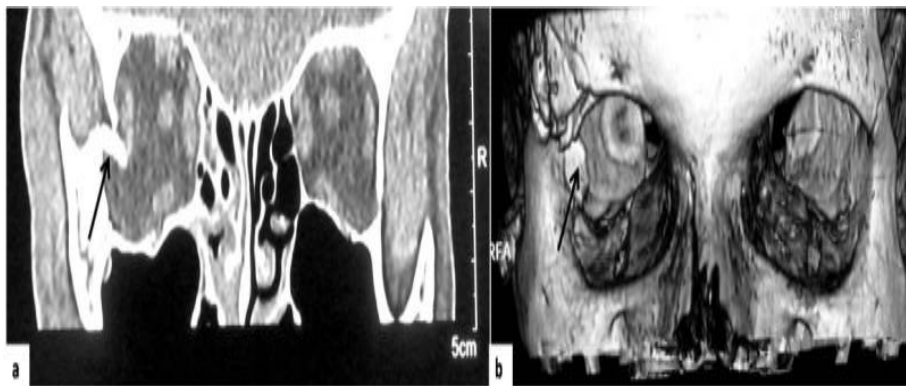

Figure 3: CT (coronal section) scan (a) showing blow-in fracture of right lateral wall of orbit (b) 3D reconstruction of medially displaced fractured bone fragment.

Removal of the impinging bone fragments to relieve the compression over lateral rectus and eye was planned under general anesthesia, after mega-dose steroid therapy failed to resolve the eye symptoms. Lateral orbital rim was exposed using extended lateral eyebrow incision. Lateral orbital rim osteotomy was done, with osteotomy cuts placed at level of fronto-zygomatic suture above and inferior extent

of lateral orbital rim below (Figure 4). The rim was removed and stored in normal saline. The impinging bony fragments were removed. The lateral rim was placed back and fixated with 2mm titanium plate and screws. The patient had uneventful post-operative period. Complete normal visions with all ocular movements were seen by 14th postoperative day.

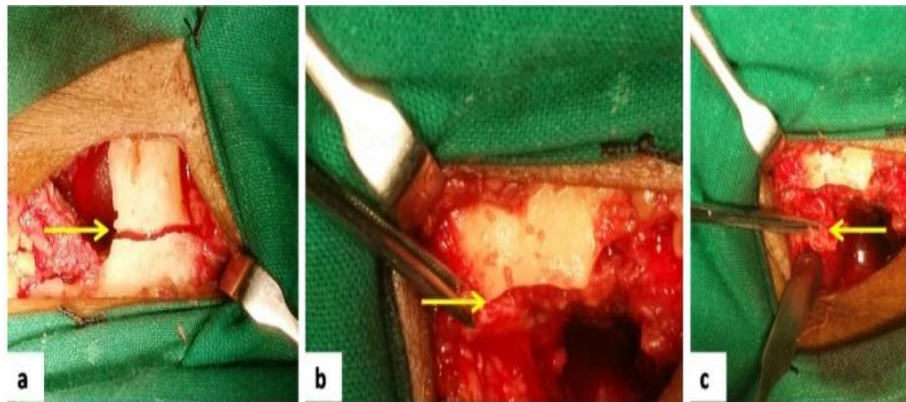


Figure 4: Intra-operative pictures showing (a) lower osteotomy cut (b) upper osteotomy cut placed over lateral orbital rim and (c) removal of impinging bone fragment.

DISCUSSION

Blow-in fracture of lateral orbital wall is rare and is more commonly associated with zygomatico-malar complex (ZMC) fractures. Displacement of the fractured lateral orbital wall varies, depending upon the severity of trauma and direction of impact. Depending on extent of displacement lateral orbital wall fractures have been classified into four types (Unger et al., 1990). [3] In type I fractures, the frontal process of the zygoma is wedged into the orbit between the globe and greater sphenoid wing. In type II fractures, the frontal process of the zygoma is displaced into the temporal fossa, and the orbital plate of the greater wing of the sphenoid bone is fractured free and pushed into the orbit as a “blow-in” fracture. Type III fractures are more severe with the entire greater wing of

the sphenoid bone impacting toward the orbital apex, with possible intrusion into the middle cranial fossa. Type IV fractures extend posteriorly where the greater wing is displaced across the orbital apex, with fracture of the optic canal. The two reported cases were true blow-in fracture of the lateral orbital wall (type II). In both cases the medially displaced fractured bone segments impinged on the lateral rectus muscle and globe causing visual and ocular motility disturbances. The other commonly reported feature of Lateral orbital wall fracture includes; circum-orbital ecchymosis, edema, sub-conjunctival hemorrhage, chemosis, enophthalmus, proptosis, lateral canthal dystopia and altered V₂ sensation. [4] Visual disturbance and blindness following cranio-facial injury is rare with reported incidence varying from

0.67 to 3 %.^[2] Most common cause of visual disturbance following orbital trauma, is compartment syndrome resulting from retro-bulbar hemorrhage.

Visual disturbance in settings of orbital trauma is mostly caused due to direct globe perforation or indirect traumatic optic neuropathy. Other rare causes of blindness from facial fracture include direct injury to optic nerve, fracture of optic canal, penetrating foreign body and fracture impinging on optic nerve.^[4] In our cases the visual disturbance appeared to be due to the fractured segments compressing over the globe and extra-ocular muscles.

Computed tomography is of paramount importance in evaluation of orbital injury. Axial CT-scan cuts provide valuable information about the degree of comminution and displacement of ZMC, the gaps along the zygomatic bone articulations and orbital walls. Beside their importance in assessing the lateral orbital wall and ZMC, coronal orbital CT-scan cuts are quite helpful to assess the orbital floor and roof walls for the presence of fractures and the need to address these fracture during the surgical repair. Three-dimensional CT-scan facilitates evaluation of patients with facial trauma by displaying the spatial orientation of the bone fragments and fracture gaps. It gives a three dimensional picture of the change in bony orbital shape in the traumatized side compared with the normal side which facilitates preoperative planning and intraoperative reduction.^[5] Three-dimensional CT-scan provides an excellent tool to educate residents, patients and family members about the fracture and its management.^[6] CT scan was helpful in our cases to exactly locate and study the displacement of the blow-in fracture segments of lateral orbit wall. The impingement of lateral rectus and globe causing the ophthalmologic signs were evident, which helped to diagnose the

possible cause and plan the surgical treatment.

Management of the lateral orbital wall fracture depends on the degree of displacement and comminution of the fracture. Non-displaced or mildly displaced fracture may be managed conservatively without surgical repair. If the displaced lateral wall fracture causes visual loss, ocular motility disturbance, enophthalmos or flattening of the malar eminence, fracture repair is indicated. Fracture of the great wing of the sphenoid with medial displacement can be reduced after exposure of the lateral wall and reduction of the zygomatic bone.^[7] Free floating bone fragment from the fracture sphenoid bone may be removed if it is not possible to have it reduced in proper anatomical position. Lateral rim osteotomies were done in our two cases to directly access and remove the medially displaced fractured bone pieces. Removal of the impinging bone segments helped to relieve the pressure symptoms and improve the visual and ocular mobility disturbances. Our experience suggests that early surgical intervention using lateral rim osteotomy facilitates direct removal of impinging bone segments and recovery of vision and eye movement.

CONCLUSION

Incidence of blow-in fracture of lateral orbital wall is rare. This paper reports two unusual cases of such fracture causing visual and ocular motility disturbances. Both the cases were successfully managed by removal of the impinging fractured segments using lateral orbital rim osteotomy-approach.

REFERENCES

1. Stanley, Robert B. Jr., Sires, Bryan S., Funk, Gerry F., Nerad, Jeffrey A. Management of displaced lateral orbital wall fractures associated with visual and

- ocular motility disturbances. *Plast. Reconstr. Surg.* 1998; 102: 972–979.
2. Holt G.R., Holt J.E. Incidence of eye injuries in facial fractures: an analysis of 727 cases. *Otolaryngol. Head Neck Surg.* 1983;91,:276–279.
 3. Unger J.M., Gentry L.R., Grossman J.E. Sphenoid fractures: prevalence, sites, and significance. *Radiology.*1990; 175:175–180.
 4. Koo L., Hatton M.P., Rubin P.A. Traumatic blindness after a displaced lateral orbital wall fracture. *J. Trauma.* 2007,62:1288–1289.
 5. Alsuhaibani AH. Orbital Fracture: Significance of lateral wall. *Saudi Journal of Ophthalmology* (2010) 24, 49–55
 6. Tsai H.H., Jeng S.F., Lin T.S. et al. Predictive value of computed tomography in visual outcome in indirect traumatic optic neuropathy complicated with periorbital facial bone fracture. *Clin. Neurol. Neurosurg.* 2005; 107: 200–206.
 7. Zhang Q.B., Dong Y.J., Li Z.B., Zhao J.H. Coronal incision for treating zygomatic complex fractures. *J. Craniomaxillofac.Surg.* 2006; 34: 182–185.

How to cite this article: Raje VV, Nilesh K. “Lateral orbital rim osteotomy-approach” for management of blow-in fracture of lateral orbit wall causing visual and ocular motility disturbances: report of two cases. *Int J Health Sci Res.* 2015; 5(3):408-413.

International Journal of Health Sciences & Research (IJHSR)

Publish your work in this journal

The International Journal of Health Sciences & Research is a multidisciplinary indexed open access double-blind peer-reviewed international journal that publishes original research articles from all areas of health sciences and allied branches. This monthly journal is characterised by rapid publication of reviews, original research and case reports across all the fields of health sciences. The details of journal are available on its official website (www.ijhsr.org).

Submit your manuscript by email: editor.ijhsr@gmail.com OR editor.ijhsr@yahoo.com