



Original Research Article

## Corrosion Casting of Human Kidney Vasculature in South Indian Population

Usha Kothandaraman<sup>1</sup>, Sadhu Lokanadham<sup>2</sup>

<sup>1</sup>Professor and Head, <sup>2</sup>Teaching Faculty,  
Department of Anatomy, ESIC Medical College & PGIMSR, Chennai, Tamilnadu, INDIA.

Corresponding Author: Sadhu Lokanadham

Received: 30/01/2015

Revised: 20/02/2015

Accepted: 28/02/2015

### ABSTRACT

**Background:** The complicated vascular pattern of the kidney show considerable regional specialization and are closely moulded to the geometric organization and functional roles of the renal corpuscles, tubules and collecting ducts.

**Materials and Methods:** A total of 50 pairs (n=100) of adult human kidneys were collected from the post-mortem bodies to study their angioarchitecture by using corrosion casting method.

**Results:** We observed bilateral single renal arteries in 95 specimens out of 100 showing the incidence of 95% which is mere agreement with the literature. The incidence of renal superior aberrant artery in the present study was 6%, the incidence of renal inferior aberrant artery was 9%, renal posterior aberrant artery was 4% and renal middle aberrant artery was 1%. The incidence of 20% aberrant renal vasculature was observed in our study. We observed cortical network of renal vasculature and segmental branches by using vascular corrosion method.

**Conclusion:** The present study acknowledges about renal vascular pattern, aberrant renal arteries by using the vascular corrosion method. High incidence of aberrant arteries is characteristic of early ramification of the renal artery. Before planning a segmental resection or partial nephrectomy, a renal angiogram is the most essential investigation for the surgeon.

**Keywords:** Corrosion, casting, segmental arteries, aberrant arteries

### INTRODUCTION

There was a considerable confusion about the pattern of blood supply to the kidney. Many believed that there was a free collateral circulation of arterial blood within the organ, and as in most other structures, the veins run conjointly with the arteries. Renal arteries (left & Right) are arising laterally from the abdominal aorta to supply the right and left kidneys. The renal artery emerges from the lateral surface of the aorta in most cases. It emerges from the

posterolateral, anterolateral and posterior surfaces with less frequency. <sup>[1,2]</sup> In its extra renal course, each renal artery gives one or more of inferior suprarenal arteries and rami of supply to the perinephric tissue, renal capsule, pelvis and the proximal part of the ureter. Just before reaching the hilum of the kidney, the renal artery on each side divides into an anterior and a posterior division. <sup>[3,4]</sup> The primary branches of the divisions are the segmental arteries which supply the vascular segments of the kidney. It was also

a popular belief that accessory or aberrant arteries which entered the poles of the kidney provided an additional source of arterial blood. [5] Since they were only accessory, they could be sacrificed when warranted, with no consequent reduction in total blood supply. The present study through corrosion casts may throw some additional light on the renal vasculature and serve to promote further work in this exciting field of medicine.

### MATERIALS AND METHODS

Human kidney specimens (n =100 ; 50 - Right ,50 - Left ) were collected with a portion of renal artery from relatively fresh bodies that came for post-mortem at the Forensic Department, Madras Medical College, Chennai. Each specimen thoroughly washed to free it from the blood clots with a canula inserted into the renal arteries through the abdominal aorta, the blood vessels were irrigated till the water returning at the venous end was clear. Subsequently through the same canula, acetone was injected to remove the water which greatly interferes with the chemical reaction. The prepared solution was quickly injected in to the arterial system, since the setting time is short. After injection, the specimen was left for 2 hours to let the injected materials settle. The specimens were carefully removed and placed in a bath of concentrated nitric acid for 24 hours to remove the soft tissues by corrosion. We were also utilized another easily injectable fluid state alternate resin called Epoxy resin for better resin casts. This process takes usually 4 - 8 days then the cast is washed under running tap water, dried and photographed to study morphometry of the renal vasculature and its terminal branches.

### RESULTS

In the present study 100 human kidney specimens (50 - right, 50 - left)

comprised equally of both sexes, the age group ranging from 20-60 years were utilized to study the renal vasculature from their origin to termination and its morphometry by corrosion casting method. We observed the branching pattern of the main trunk of renal artery from its origin to its termination along with cortical network of anastomoses (Figure-1).

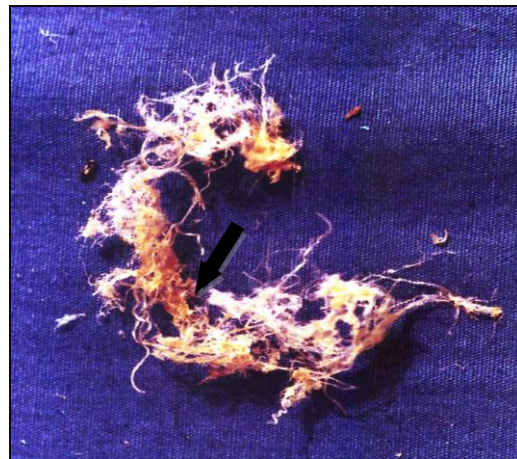

Figure – 1: Corrosion casting showing the cortical network of renal vasculature

We also observed different segmental arteries with their branching pattern (Figure-2&3).In some cases we observed aberrant renal artery with its origin and point of entry.




Figure – 2: Corrosion casting showing the cortical network of renal vasculature and segmental branches of renal artery (ASA: Apical segmental artery; LSA: lower segmental artery; RA: renal artery; PSA: posterior segmental artery)

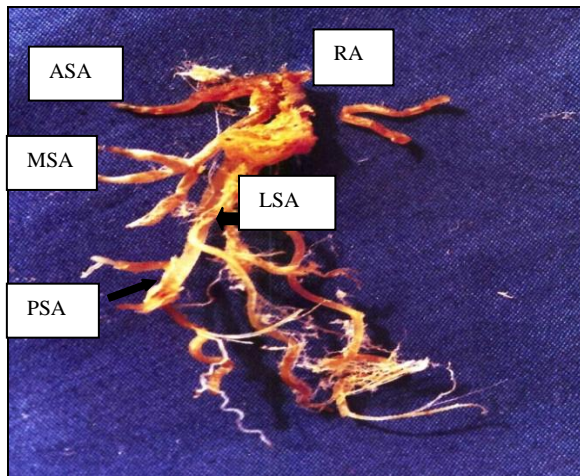


Figure – 3: Corrosion casting showing the renal vasculature segmental branches of renal artery ( RA: main trunk of renal artery; ASA: Apical segmental artery ;LSA: lower segmental artery; PSA: posterior segmental artery)

Out of 100 kidney specimens the renal arteries arises from the abdominal aorta in 50 right kidneys and 45 left kidneys. A number of 5 kidneys do not show a definite renal arterial trunk (Table – I).

Table – I: origin of the renal arteries

Nature of renal trunk origin	Right kidney	Left kidney
Abdominal aorta	50	45
No Definite renal trunk	-	5
Total	50	50

We observed various origins of aberrant renal arteries in 20 out of 100 kidney specimens (Table – II).

Table – II: Incidence of aberrant renal vessels

Nature of Aberrant Renal arteries	Directly from Abdominal aorta	Individual branches from Abdominal aorta
Apical Aberrant artery	5	1
Posterior Aberrant artery	4	-
Middle Aberrant artery	-	1
Lower aberrant artery	8	1

Qualitative statistics were used to analyze and this study is under clearance with human ethical committee, Madras Medical College, Chennai.

## DISCUSSION

Renal irrigation is characterized by presenting great variability, the presence of a single bilateral or unilateral renal artery significantly predominating in most studies. [6-8] Tsikaras et al. believe that acrylic resins together with corrosion techniques are ideal for the production of anatomic molds because of the low cost, availability of materials, ease of manipulating the polymer and resin, fast setting (3 to 9 hours), the resistance of the molds, solubility of the dyes and the good visualization of small-calibre branches. [9] The presence of bilateral single renal arteries had incidence of 75.1%. [10,11] Renal irrigation provided by a single renal artery had high frequency ranging from 82% to 87%. [12-14] In our study we observed bilateral single renal arteries in 95 specimens out of 100 showing the incidence of 95% which is mere agreement with the literature. The incidence of renal superior aberrant artery in the present study was 6%, the incidence of renal inferior aberrant artery was 9%, renal posterior aberrant artery was 4% and renal middle aberrant artery was 1% out of 100 renal specimens. The incidence of 20% aberrant renal vasculature was observed in our study. The incidence of renal superior polar artery ranges from 11.9% -16.6% and the inferior polar renal artery ranges from 3.4% - 8% in Caucasians and Negros. [15-17] In our findings the inferior renal aberrant arteries incidence agreed with the literature and not the superior renal aberrant artery this may be due to less number of specimens utilized for this study.

## CONCLUSION

Renal arterial pattern in both kidneys of the same individual is very variable. Therefore, before planning a segmental resection or partial nephrectomy, a renal angiogram is the most essential investigation for the surgeon.

## ACKNOWLEDGEMENTS

Authors are thankful to Prof. T.S. Ranganathan for his valuable guidance and advice during this work. Authors acknowledge the valuable guidelines received from Prof. Esther Revathy for her valuable suggestions.

**Conflict of Interest:** Nil

## REFERENCES

1. Keen, E. N. Origin of renal arteries from the aorta. *Acta Anat. (Basel)*,110(4): 285-6, 1981.
2. Augustyn, M. Supernumerary segmental branches of the renal artery. *Folia Morphol. Warsaw.*, 41:441-7, 1982.
3. Graves, F. T. The aberrant renal artery. *J. Anat.*, 90: 553-8, 1956.
4. Harrison, L. H.; Flye, M.W. & Slegler H. F. Incidence of anatomical variants in renal vasculature in the presence of normal renal function. *Ann Surg.*, 188:83-9, 1978.
5. Coen, L.D. & Raftery, A.T. Anatomical variation of renal arteries and renal transplantation. *Clin Anat.*, 5:425-32, 1992.
6. Ajmani, M. L.& Ajmani, K. To study the intrarenal vascular segments of human kidney by corrosion cast technique. *AnatAnz.*; 154(4):293-303, 1983.
7. Testut, L. & Jacob, O. *Anatomía topográfica con aplicaciones medicoquirúrgicas*. Salvat, Barcelona, 1979. Tomo II
8. Williams, P. L.; Warwick, R.; Dyson, M. & Bannister, L. H. The kidney. In: Gray's anatomy. 37th Ed. Edinburgh, Churchill Livingstone, 1989.849-855.
9. Tsikaras PD, Hytioglou PM, Lazos LM; 1985.The use of unsaturated polyester resin solutions in preparing casts of renal vessels. *Bull Assoc Anat (Nancy)*;69(204):71-8.
10. Anson, B. J.; Richardson, G. A. & Minear, W. L. Variations in the number and arrangement of the renal vessels. A study of the blood supply of four hundred kidneys. *J. Urol.*; 36:211-9, 1936
11. Cicekcibasi, A. E.; Ziylan, T.; Salbacak, A.; Seker, M.;Buyukmumcum, M. & Tuncer, I. An investigation of the origin, localization and variations of the renal arteries in human fetuses and their clinical relevance. *Ann. Anat.*,187(4): 421-7, 2005.
12. Reis, R. H & Esenther, G. Variations in the pattern of renal vessels and their relation to the type of posterior vena cava in man. *Am. J. Anat.*, 104:295-318, 1959.
13. Ronstrom, G.N. Incidence of single and multiple renal arteries in negroes. *Am. J. Phy. Anthropol.*, 5:485-90, 1947.
14. Wozniak, W.; Kiertz, A. & Warzniak, S. The question of the renal arterial segments. *Anat. Anz.*, 132:332-40, 1972.
15. Sampaio, F. J. & Passos, M. Renal arteries: anatomic study for surgical and radiological practice, *Surg. Radiol. Anat.*14:113-7, 1992.
16. Eisendrath, D. N. The relation of variation in the renal vessels to pielothomy and nephrectomy. *Ann. Surg.*, 71:726-43,1920.
17. Longia, G.S.; Kumar, V. & Gupta C. D. Intrarenal arterial pattern of human kidney--corrosion cast study. *Anat Anz.*, 155(1-5):183-94, 1984.

How to cite this article: Kothandaraman U, Lokanadham S. Corrosion casting of human kidney vasculature in south Indian population. *Int J Health Sci Res.* 2015; 5(3):150-153.

\*\*\*\*\*