



Review Article

Patent Foramen Ovale: A Cadaveric Observational Study

Naveena Swargam¹, Mrudula Chandrupatla²

¹Assistant Professor, ²Associate Professor,
Department of Anatomy, Apollo Institute of Medical Sciences and Research, Hyderabad, Telangana State, India.

Corresponding Author: Naveena Swargam

Received: 01/01/2015

Revised: 21/01/2015

Accepted: 23/01/2015

ABSTRACT

The patent foramen ovale is a congenital defect in the inter-atrial septum, is an accidental finding in the absence of cardio-vascular disorders. A patent foramen ovale results from a failure of closure of foramen ovale following birth and persists in around 25% of adults as reviewed by previous studies. Patent foramen ovale is a potential route for embolic transit of platelet aggregations from systemic circulation to the brain, which accounts for the undetermined cryptogenic stroke. The embryological origins of patent foramen ovale were described and the different diagnostic modalities available were also mentioned before reviewing the current scenario of the prevalence of patent foramen ovale.

The present study aimed at the evaluation of patent foramen ovale incidence by observing the patency of foramen ovale during cadaveric dissection. 30 human hearts were collected and dissected from adult cadavers, for a period of 3 years in the Department of Anatomy at Apollo Institute of Medical Sciences and Research, Jubilee Hills, Hyderabad, Telangana State, India. Out of 30 specimens only 2 were shown to be having patent foramen ovale with a size ranging from 2mm to 5mm. Further studies are necessary to estimate the benefit of early identification of patent foramen ovale to prevent the cryptogenic stroke or relative ischaemic conditions in general population.

Keywords: Patent foramen ovale, Inter-atrial septum, Cryptogenic stroke.

INTRODUCTION

During foetal life, a septum primum grows caudally from the roof of primitive atrium dividing the chamber into right and left primitive atria incompletely. The gap between the lower edge of septum primum and the atrio-ventricular endocardial cushion is known as ostium primum. As the septum primum starts fusing with the endocardial cushion caudally, the cranial part of the septum starts degenerating leaving a perforation called ostium secundum. At this stage, a septum secundum starts developing

onto the right side of septum primum from the roof of primitive right atrium. The septum secundum grows caudally as the septum primum regresses caudally. The persisting ostium secundum between septum primum and septum secundum is now called as foramen ovale. This slit-like opening in the primitive inter-atrial septum is an integral part of normal foetal circulation. It is normally closed during the infancy because of the different pressure gradients within the atria.

Incomplete closure of foramen ovale is called as patent foramen ovale, which is considered a normal anatomic variant and not a pathological finding in the absence of possible paradoxical embolism or other specific clinical conditions. [1] The purpose of this review was to determine the incidence of foramen ovale and to give a broad overview of the role of patent foramen ovale in decompression sickness, migraine and different vascular diseases.

MATERIALS AND METHODS

In the present study 30 heart specimens from adult cadavers were dissected over a period of 3 years irrespective of the sex, in the Department of Anatomy at Apollo Institute of Medical Sciences and Research, Hyderabad, Telangana State, India.

RESULTS

Among the 30 specimens of heart, 2 hearts were found to be having the patent foramen ovale (Figure 1 and Figure 2). The vertical and transverse diameters of the foramen were measured and tabulated (Table 1).

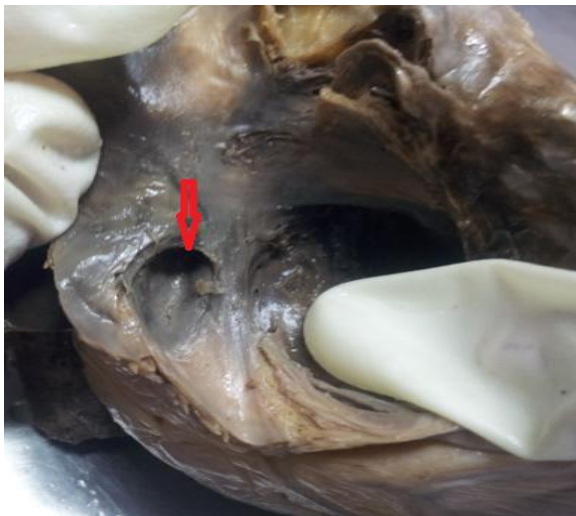


Figure 1: Patent foramen ovale with 5mm vertical diameter
*The arrow showing the patency of foramen ovale

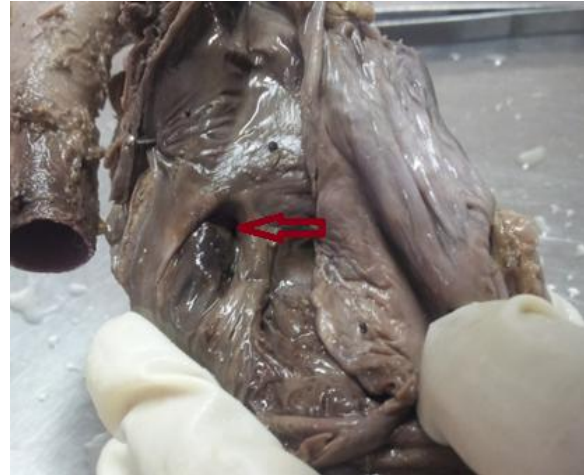

Figure 2: Patent foramen ovale with 2mm vertical diameter
*The arrow showing the patency of foramen ovale

Table 1: Size of Patent foramen ovale

Figure Number	Size
1	5 mm×3mm
2	2 mm×1mm

*The size was measured as vertical diameter × transverse diameter.

DISCUSSION

In the literature the patency range described between 10 and 30% depending on the echocardiography or autopsy studies. [2] Although most of the patients with a patent foramen ovale are asymptomatic, a variety of clinical manifestations like cardio-embolic cerebrovascular accidents and transient ischemic attacks may be associated with it. In approximately 40% of people with acute ischemic stroke the cause remains undefined. [3] In order of magnitude, the amount of right-to-left shunting to cause systemic desaturation is larger than the amount of shunting seen in the general population with a patent foramen ovale.

While the surgical closure of patent foramen ovale the operator may choose to close the foramen using the trans-septal puncture at the base of septum secundum. The size and the type of the device can be determined by the integrity of the atrial septum and the area needed to ensure the defect is fully covered. [4]

The literature was reviewed and the results were tabulated in comparison with the previous study (Table 2). [5]

Table 2: Incidence of Patent foramen ovale

	Incidence (%)
Present study	6.66
Edmund K Kerut et al.	6

*The percentage of incidence was calculated and compared with the previous study.

CONCLUSION

The present study was limited to the cadaveric dissection to percentage the occurrence of patent foramen ovale in adult specimens in view of current scenario of knowledge about the relationship of patent foramen ovale with unidentified blood vascular conditions in general population. Further well-designed studies are necessary to address several unresolved issues related to pathophysiology and complications of patent foramen ovale to prevent the cryptogenic stroke in those patients who would most likely to benefit from the closure of patent foramen ovale.

REFERENCES

1. Shelby Kutty, Partho P. Sengupta, Bijoy K. Khandheria; Patent Foramen Ovale: The Known and the To Be Known; *JACC Vol. 59, No. 19, 2012; May 8, 2012:1665–71*
2. Gianluca Rigatelli, Federico Ronco; Patent Foramen Ovale: A Comprehensive Review for Pulmonologists; *Curr Opin Pulm Med. 2010;16(5):442–447*
3. Shunichi Homma; Ralph L. Sacco; Contemporary Reviews in Cardiovascular Medicine; Patent Foramen Ovale and Stroke; *Circulation. 2005; 112: 1063-1072; doi: 10.1161/CIRCULATIONAHA.104.524-371*
4. Sudhakar George, David Hildick-Smith; Patent foramen ovale: diagnosis indications for closure and complications; *Br j Cardiol 2011;18: 219-22; doi: 10.5837/bjc. 2011.002*
5. Edmund K Kerut; William T Norfleet; Gary D Plotnick; Thomas D Giles; Patent foramen ovale: a review of associated conditions and the impact of physiological size; *J Am Coll Cardiol. 2001;38(3):613-623. doi:10.1016/S0735-1097(01)01427-9*

How to cite this article: Swargam N, Chandrupatla M. Patent foramen ovale: a cadaveric observational study. *Int J Health Sci Res.* 2015; 5(2):387-389.
