



Original Research Article

## Study of MRI Features of Avascular Necrosis of Femoral Head and to Study Association of Bone Marrow Edema and Hip Joint Effusion with Avascular Necrosis

Chaudhari Nilesh H<sup>1</sup>, Murkey Nikhil S<sup>2</sup>, Patel Krutik A<sup>3</sup>

<sup>1</sup>Assistant Professor, <sup>2</sup>Junior Resident (III), <sup>3</sup>Junior Resident (II)

Department of Radio-diagnosis, Dr. Vasantrao Pawar Medical College Hospital & Research Center, Nashik, Maharashtra, India.

Corresponding Author: Chaudhari Nilesh H

Received: 05/01/2015

Revised: 26/01/2015

Accepted: 28/01/2015

### ABSTRACT

**Background:** Avascular necrosis (AVN), also known as osteonecrosis of femoral head is a pathology in which many etiologies play role and cause decreased vascular supply to subchondral bone of femoral head which results in osteocyte death. MRI is the most sensitive modality for detection of AVN.

**Purpose:** Our aim was to study the MRI features of avascular necrosis of femoral head and to study the association of bone marrow edema and joint effusion with it.

**Materials and Methods:** We studied MR images of 30 patients with avascular necrosis of femoral head. All MR imaging examinations were performed on 1.5-T magnet MR system (Siemens magneto Essenza). Imaging was performed using the body coil with the patient in a supine position and both hips examined simultaneously. Both hips were studied with multiplanar T1-weighted, T2-weighted and PD FS sequences.

**Results:** Total 60 femoral heads (bilateral femoral heads of 30 patients) were studied out of which 51 were showing features of AVN, while 9 were normal. Out of 51 femoral heads showing AVN, 21 showed subchondral collapse. Bone marrow edema was seen in 34 femoral heads out of 51 femoral heads with AVN. Joint effusion was observed in 37 femoral heads out of 51 femoral heads with AVN.

**Conclusion:** MRI plays an important role in early diagnosis of AVN of femoral head. There is association of bone marrow edema and hip joint effusion with AVN of femoral head.

**Keywords:** AVN, Femoral head, Marrow edema, Joint effusion,

**Abbreviations:** AVN- avascular necrosis, MRI - magnetic resonance imaging, PD FS - proton density fat saturated.

### INTRODUCTION

Avascular necrosis, also known as osteonecrosis of femoral head is a pathology in which many etiologies like trauma, corticosteroid use, alcoholism, pancreatitis, radiation, sickle cell disease, infiltrative

diseases (e.g. Gaucher's disease), and Caisson disease play role and cause decreased vascular supply to subchondral bone of femoral head which results in osteocyte death.

Osteonecrosis of femoral head can cause severe musculoskeletal disability and thus it creates a major diagnostic and therapeutic challenge. The femoral head is the most frequently involved in this condition. [1,2]

Avascular necrosis of femoral head is a condition that may cause rapid bilateral femoral head collapse in young patients. [3]

Many noninvasive diagnostic modalities are used in detecting avascular necrosis like plain radiography, magnetic resonance imaging (MRI), computed tomography (CT), skeletal scintigraphy, and single photon emission computed tomography (SPECT). MRI is the most sensitive modality for detection of avascular necrosis. [4] Plain film radiography may be helpful in assessing flattening of the femoral head and associated degenerative changes, but it is not much helpful for diagnosing and detecting early changes of avascular necrosis. Plain film cannot detect changes of subtle bone marrow edema in AVN.

#### **Aims and objectives:**

1. To study MRI features of AVN of head of femur.
2. To study association of bone marrow edema with AVN.
3. To study association of hip joint effusion with AVN.

#### **MATERIALS AND METHODS**

We studied 30 patients presented in Department of Radio diagnosis at Dr. Vasantrao Pawar Medical College, Hospital and Research Center, Nashik.

All patients having diagnostic features AVN of the femoral head were studied by MR imaging.

#### **Inclusion criteria:**

Patients showing MRI changes of AVN of femoral head.

#### **Exclusion Criteria:**

- Post traumatic cases.
- Primary osteoarthritic hip.

#### **Methodology:**

The patients who had undergone MR imaging of both hips in our institute and diagnosed cases of avascular necrosis of femoral head are included in our study.

All MR imaging examinations were performed on a 1.5-T magnet MR system (Siemens magnetomEssenza). Imaging was performed using a body coil with the patient in a supine position and both hips examined simultaneously. Both hips were studied with multiplanar T1-weighted, T2-weighted and PD FS sequences.

#### **Interpretation of images [3]**

Characteristic MRI imaging features were used to establish the diagnosis of AVN of femoral head like:

- 1) A band like pattern, a ring like/serpiginous lesion with homogeneous or heterogeneous signal intensity of central area of decreased signal intensity with dark band on T1W and T2W images.
- 2) Crescentic areas of low signal intensity in weight bearing areas of femoral head T1 and T2 W images.
- 3) Bone marrow edema was defined as ill-defined area of low intensity on T1WI and intermediate to high signal intensity on PD FS sequences.
- 4) Joint fluid was seen on T2WI images.

#### **RESULTS**

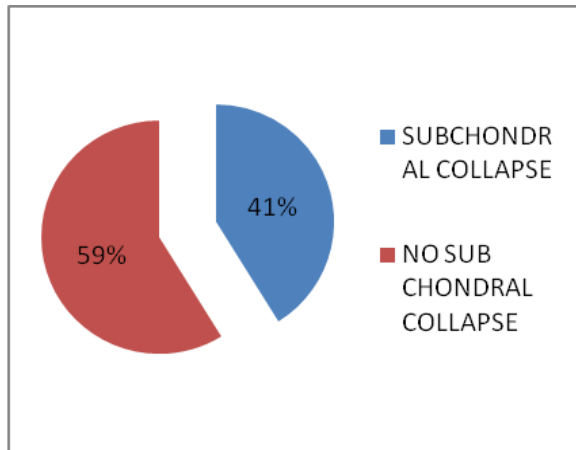
We studied MRI images of 30 patients with avascular necrosis of femoral head.

Diagnosis of avascular necrosis of femoral head was based on typical MRI findings.

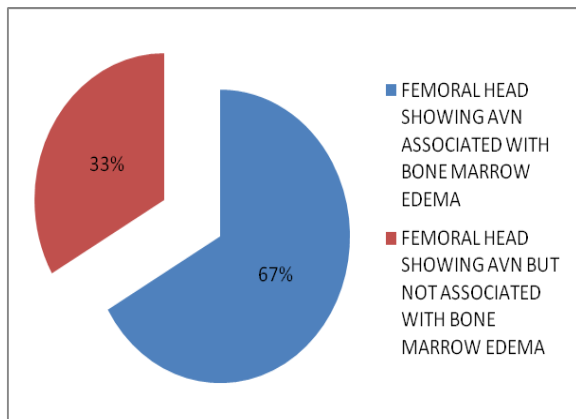
Patient age ranged from 20- 70 years. Out of these 30 patients, 5 (16.67%) patients were females and rest was males i.e. disease appeared 5 times more common in males.

9 patients had unilateral disease; rest of them had bilateral (70%) disease.

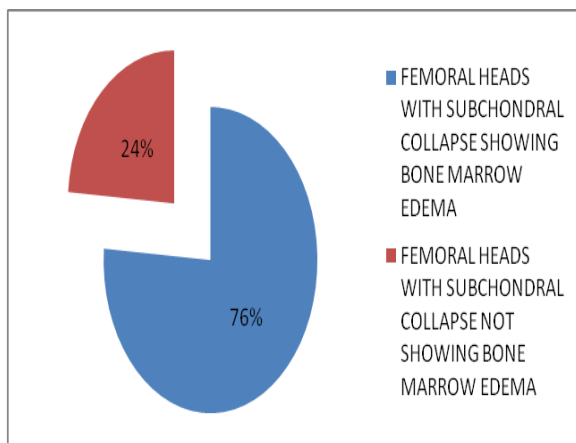
Total 60 femoral heads were studied out of which 51 were showing features of osteonecrosis, while 9 were normal.



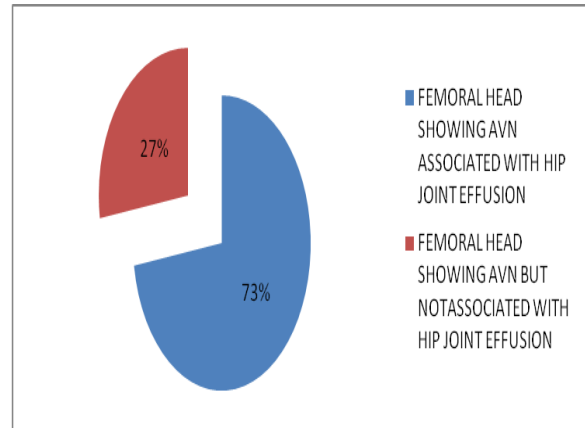
**Graph No. 1:** Subchondral collapse in 21 Out of 51 femoral heads with AVN (41%).



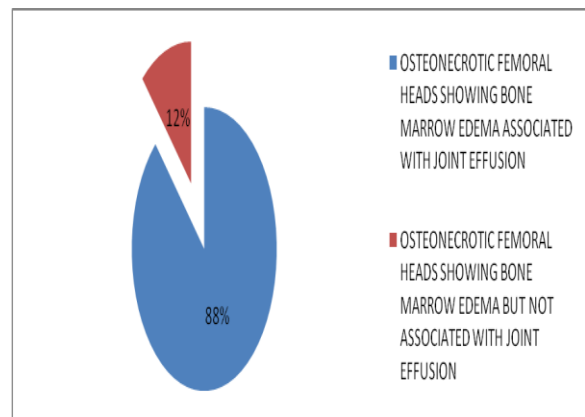
**Graph No. 2:** Bone marrow edema in 34 out of 51 femoral heads with AVN(67%).



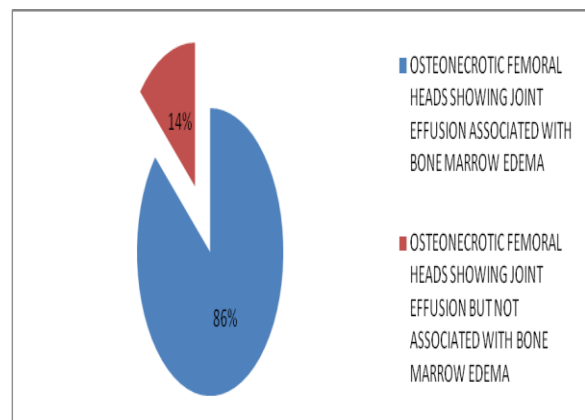
**Graph No.3:** Bone marrow edema in 16 out of 21 femoral heads with subchondral collapse (76%).



**Graph No. 4 :** Joint effusion in 37 out of 51 femoral heads with AVN (73%).



**Graph No. 5 :** Out of 34 femoral heads with bone marrow edema 30 were having associated (88%).



**Graph No. 6:** Out of 37 femoral heads with joint effusion 32 were having associated bone marrow edema (86%).

## DISCUSSION

Avascular necrosis, also known as osteonecrosis of femoral head is a pathological state with multiple possible

etiologies that cause decreased vascular supply to subchondral bone of femoral head, resulting in osteocyte death. [2] AVN of femoral head is an on-going condition in which the balance among tissue death, the body's response and bone strength leads to wide spectrum of clinical and imaging presentation. AVN of femoral head is a potentially disabling disorder, mainly affecting middle aged adults that can lead to early osteoarthritis epiphyseal collapse and joint incongruity. Males are more commonly affected and disease is more commonly bilateral. [5] In our study, disease appeared 5 times more common in males and bilateral involvement was seen in 70% cases. MRI is the most sensitive imaging technique for early detection of avascular necrosis of femoral head. [4]

Hip was one of the first joint to be investigated with MRI. Ability of MRI to directly detect bone marrow renders this technique well suited for the diagnosis of femoral head marrow lesions such as

avascular necrosis/ transient marrow edema. [5]

The use of MRI for evaluation of patients with suspected avascular necrosis will yield earlier detection of disease even when the patient is asymptomatic and thus make the surgical management more likely to be successful. Early surgical intervention can result in preservation of femoral head and not its replacement. [4,6-8]

At present MRI has become the imaging modality of choice, as it is highly sensitive and specific for osteonecrosis. T1 images on MRI typically demonstrate a serpiginous band like lesion with low intensity in anterosuperior femoral head and double line sign can be seen on T2 images. [2] Double line sign is seen on T2 W images as high intensity signal line within the parallel line of low signal intensity, often with serpiginous border. The high intensity inner zone represents the hyperaemic granulation tissue and low intensity outer zone represents the dense sclerotic bone. [9]

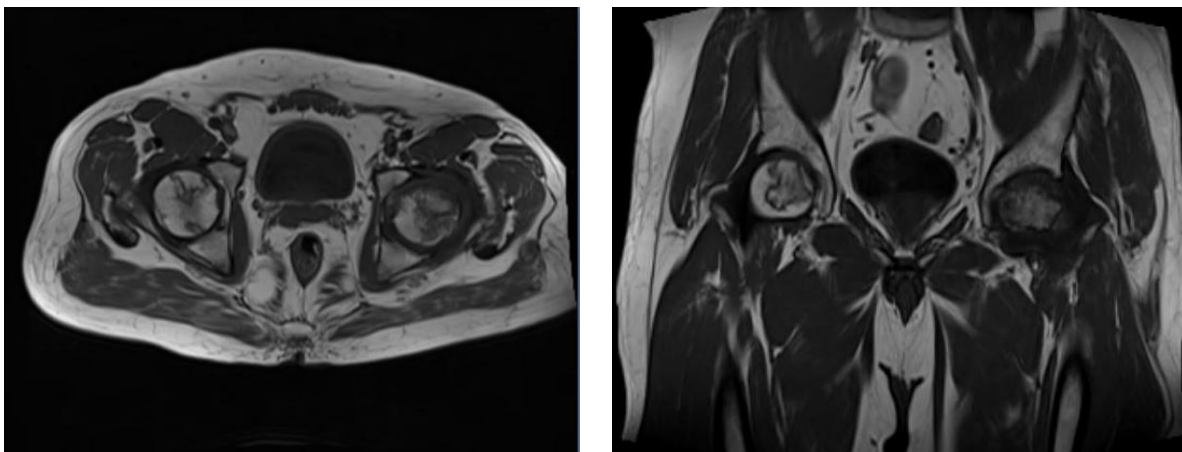


Fig. 1. T1W (axial and coronal) images showing serpiginous areas of osteonecrosis.

Detection of subchondral fractures is very important in the early stages of avascular necrosis of femoral head. Because the necrotic area appears as iso-signal intensity on MR images in the early stages of the disease, an irregular subchondral band of abnormal signal intensity would be easily

detected. MRI is much more sensitive than plain radiography in detecting subchondral fractures. Fracture within the subchondral bone is best seen in T2 images as subchondral band of high signal intensity known as MRI crescent sign. [10,11] According to a study done by Zibis et al,

2007, plain radiographs and MRI together can be used for detection of location of the osteonecrotic lesion, evaluation of the size of the lesion, and detect the presence and degree of collapse of the articular surface. [12] Bone marrow edema is most frequently observed MRI finding in AVN of femoral

head. [10] In our study bone marrow edema was seen in 66.7% of cases with AVN of femoral head. Bone marrow edema is probably a secondary reaction to subchondral fractures resulting from mechanical stress. [3,10,13]

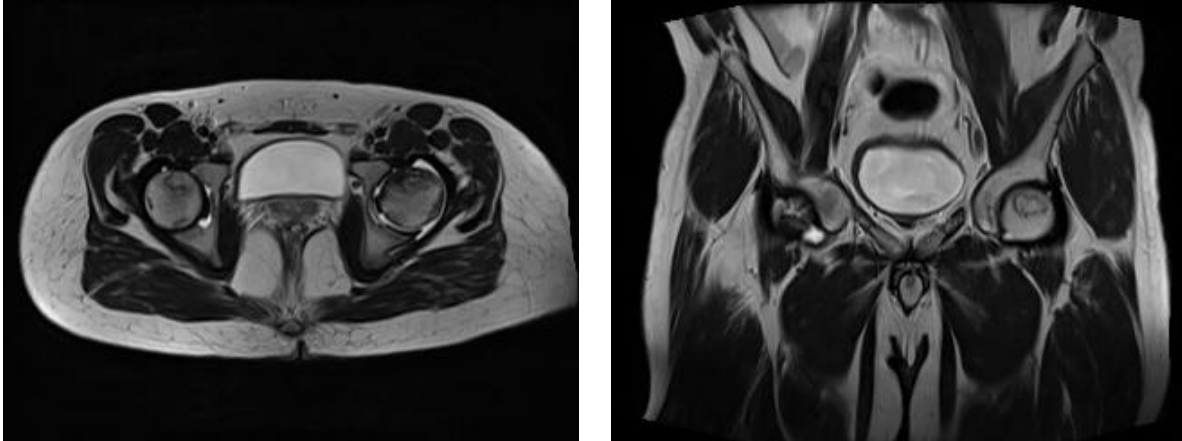


Fig 2: T2 W (axial and coronal) images showing the double line sign at the periphery of a region of osteonecrosis and consists of an inner bright T2 line representing granulation tissue and an outer dark line representing sclerotic bone.

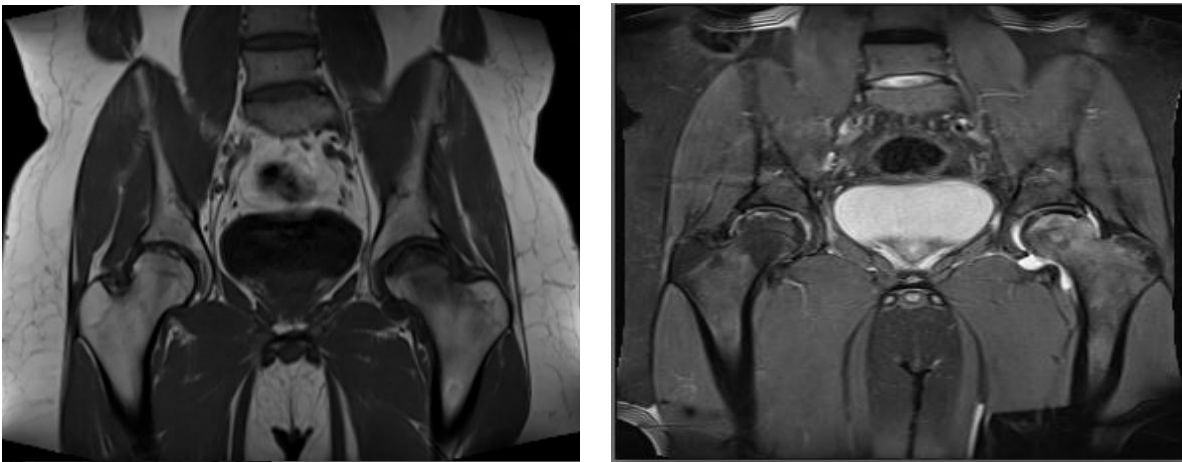


Fig3: Marrow edema seen hypointense on T1WI and hyperintense on PD FS images.

In AVN of femoral head, the initial abnormal finding detected on MR images is a band of abnormal intensity at the junction between the necrotic and the normal area. The bone marrow edema pattern is not observed in early stages of the disease. In AVN of femoral head, the structural damage seems to bring about the marrow edema pattern and pain. Bone marrow edema is

most often found in femoral heads with stage 3 disease. [10]

In avascular necrosis, increased joint fluid may be present before radiographic abnormalities occur, but it is greatest after there is flattening of the femoral head. MRI is a highly sensitive method for detecting fluid in the hip joint. [14] In our study joint effusion was frequently associated with

AVN of femoral head. (73% cases of AVN showed joint effusion).

In a study done by Iida et al, they concluded bone marrow edema as a marker for potential progression to advanced osteonecrosis. Their study was done on patients with steroid induced avascular necrosis and out of 13 hips with bone marrow edema 11 (85%) progressed to collapse of femoral head. [13] In our study, 85% cases with subchondral collapse are associated with bone marrow edema.

In a study done by Huang et al, they indicated that bone marrow edema occurrence was 16 times more likely when the affected osteonecrotic femoral head was associated with joint effusion. [3] In our study, 86% cases with joint effusion were associated bone marrow edema (i.e. bone marrow edema occurrence was 6 times more likely when the affected osteonecrotic femoral head was associated with joint effusion).

## CONCLUSION

MRI plays an important role in early diagnosis of AVN of femoral head. Subtle subchondral collapse of femoral head can be diagnosed with more confidence. Bone marrow edema and hip joint effusion are frequently associated with AVN of femoral head. Bone marrow edema can be very well seen on MRI and early detection of AVN of femoral head can thus be possible, allowing early decompression and help to preserve the joint.

## REFERENCES

1. Yochum T, Rowe L. Essentials of skeletal radiology. 3rd ed. Lippincot: Williams & Wilkins 2005; 114–115.
2. Anjan P Kaushik, Anusuya Das, and Qanjan Cui et al. Osteonecrosis of the femoral head: An update in year 2012. World J Orthop. May 18, 2012; 3(5): 49–57.
3. Guo-Shu Huang, Wing P. Chan, Yue-Cune Chang et al. MR Imaging of Bone Marrow Edema and Joint Effusion in Patients with Osteonecrosis of the Femoral Head: Relationship to Pain. AJR August 2003 vol. 181 no. 2 545-549
4. Mitchell MD, Kundel HL, Steinberg ME, Kressel HY, Alavi A, Axel L. Avascular necrosis of the hip: comparison of MR. CT and scintigraphy. AJR 1986; 147:67-71.
5. Vande Berg BE, Malghem JJ, Labaisse MA, Noel HM, Maldague BE. MR imaging of avascular necrosis and transient marrow edema of the femoral head. Radiographics. 1993 May;13(3):501-20.
6. Lee MS, Chang Yu-Han et-al. Conditions before collapse of the contralateral hip in osteonecrosis of femoral head. Chang Gung Med J 2002;25 : 228-37.
7. Fordyce MJF, Solomon L. Early detection of avascular necrosis of the femoral head by MRI. J Bone Joint Surg [Br] 1993;75-B:365-7.
8. Totty WG, Murphy WA, Ganz WI, Kumar B, Daum WJ, Siegel BA. Magnetic resonance imaging of the normal and ischemic femoral head. AJR 1984; 143:1273-1280.
9. John V. Zurlo. The Double-Line Sign Radiology 1992;12:2, 541-542
10. Kim YM, Oh HC, Kim HJ. The pattern of bone marrow oedema on MRI in osteonecrosis of the femoral head. J Bone Joint Surg Br 2000;82:837–841
11. Mitchell DG, Steinberg ME, Dalinka MK, et al. Magnetic resonance imaging of the ischemic hip: alterations within the osteonecrotic, viable, and reactive zones. Clin Orthop 1989;244:60-77.

12. Zibis AH, Karantanas AH, Roidis NT, et al. The role of MR imaging in staging femoral head osteonecrosis. *Eur J Radiol* 2007 Jul; 63(1):3-9.
13. Iida S, Harada Y, Shimizu K, et al. Correlation between bone marrow edema and collapse of the femoral head in steroid-induced osteonecrosis. *AJR* 2000;174:735–743
14. Mitchell DG, Rao V, Dalinka M, et al. MRI of joint fluid in the normal and ischemic hip. *AJR* 1986; 146: 1215–1218.

How to cite this article: Chaudhari NH, Murkey NS, Patel KA. Study of MRI features of avascular necrosis of femoral head and to study association of bone marrow edema and hip joint effusion with avascular necrosis. *Int J Health Sci Res.* 2015; 5(2):116-122.

\*\*\*\*\*

**International Journal of Health Sciences & Research (IJHSR)**

**Publish your work in this journal**

The International Journal of Health Sciences & Research is a multidisciplinary indexed open access double-blind peer-reviewed international journal that publishes original research articles from all areas of health sciences and allied branches. This monthly journal is characterised by rapid publication of reviews, original research and case reports across all the fields of health sciences. The details of journal are available on its official website ([www.ijhsr.org](http://www.ijhsr.org)).

Submit your manuscript by email: [editor.ijhsr@gmail.com](mailto:editor.ijhsr@gmail.com) OR [editor.ijhsr@yahoo.com](mailto:editor.ijhsr@yahoo.com)