



Case Report

Aneurysmal Bone Cyst of Third Metacarpal: An Unusual Presentation

Ajay P. Surwade¹, K.A.Saindane², Ninad Godghate³, Neha Godghate³¹Third Year Resident, ²Professor, ³Assistant Professor,
Department of Orthopaedics, ACPM Medical College, Dhule, (M.S.), India

Corresponding Author: Ajay P. Surwade

Received: 18/11/2014

Revised: 12/12/2014

Accepted: 18/12/2014

ABSTRACT

Aneurysmal bone cyst is a rare, rapidly growing, and destructive benign bone tumor that rarely involves the bones of the hand (4.7%). Various treatment options for aneurysmal bone cyst have been reported in the literature, but controversy exists regarding optimal treatment. Aneurysmal bone cyst in third metacarpal of child of age 13 year is rare entity and decision making for management poses difficulties. Our experience with curettage and autologous bone grafting was quite satisfactory with excellent clinical result, and we recommend this as one modality of treatment of ABC in metacarpal of child.

Keywords: Aneurysmal Bone cyst; Metacarpal; Child; Autologous bone graft

INTRODUCTION

Aneurysmal bone cyst (ABC) an osteolytic bone neoplasm characterized by several sponge-like blood or serum filled, generally non-endothelialized spaces of various diameters. [1] Aneurysmal Bone cyst (ABC) is a rare tumor and accounts for 1-2% of all primary bone tumors. Jaffe and Lichtenstein in 1942 were the first to give distinct identity and describe it separately from hemangiomas of bone and other tumors of giant cells. [2] Many hypotheses have been proposed to explain the etiology and pathogenesis of ABC, and until very recently the most commonly accepted idea was that aneurysmal bone cyst was the consequence of an increased venous pressure and resultant dilation and rupture of the local vascular network. However, studies by Panoutsakopoulos *et al.* and Oliveira *et*

al. uncovered the clonal neoplastic nature of aneurysmal bone cyst. Primary etiology has been regarded arteriovenous fistula within bone. [3] ABC usually occurs in first two decades of life and has slight female preponderance. It shows predilection [4,5] for long bones and vertebral column; less than 5% of all ABC occurs in long bones of hand. [6] Pathogenesis of ABC is obscure. Lichtenstein suggests that persistent local disturbance in hemodynamics (venous thromboses of arteriovenous aneurysm) causes marked increase in venous pressure and leads to development of dilated engorged vascular bed. Various other theories about origin of ABC make it true neoplasm. [7,8] Various options for treatment of ABC have been reported from time to time, we are sharing our experience with this

ABC in third meta carpal of a child of age thirteen. [9,10]

CASE REPORT

A 13 year old girl presented with a history of pain and mild local swelling over her third metacarpal of 10 months duration. On physical examination, the lesion was stiff and immobile and there was slight tenderness with palpation. Pain was aggravated with movement with weak grip and active range of motion of her third metacarpophalangeal joint was slightly restricted, and there was no history of trauma. Her past medical history revealed no abnormality.

Radiographic examination of the hand showed a ? partially healed enchondroma and ? Aneurysmal Bone Cyst (fig 1).

Operative Procedure: Curettage of cystic lesion done through dorsal longitudinal incision over third metacarpal. Autologous iliac bone graft harvested from right iliac crest ,crushed into small pieces and inserted into bony defect. Hand was immobilized in short arm cast for four weeks. After which physiotherapy started for three weeks,consisting of progressive active and passive exercises.

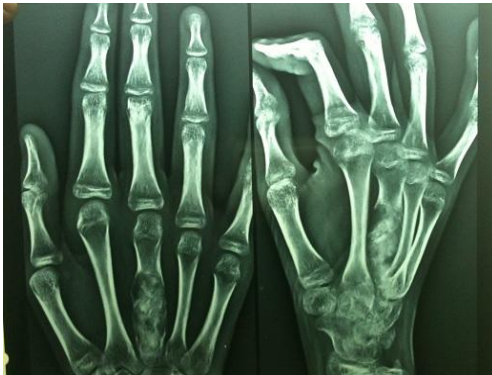

Figure 1 aneurysmal bone cyst of third metacarpal

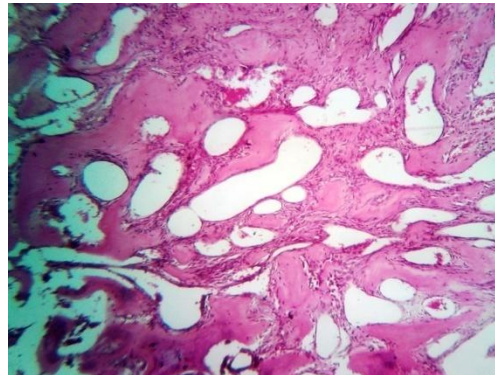


Figure 2 histopathological slide

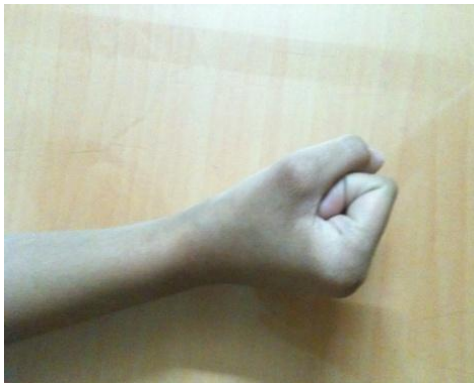

Figure 3

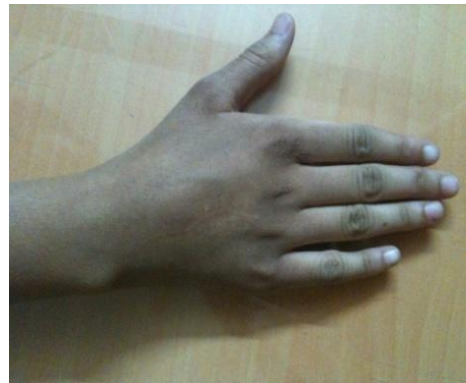

Figure 4

Pathological examination confirmed the diagnosis of aneurysmal bone cyst. Histopathology shows large cystic spaces filled with blood and separated by fibrous septa, alternating with solid areas .Cysts and

septa lined by fibroblasts, myofibroblasts and histiocytes but not endothelium. Clusters of osteoclast-like multinucleated giant cells with loose spindly stroma to cellular stroma, reactive woven bone,

degenerated calcifying fibromyxoid tissue, Variable mitotic figures and hemosiderin (fig 2).No malignant osteoid, no atypia

At final follow up after 3 year postop the patient had gain full range of motion with no pain (fig3,4).The patient was satisfied with functional and cosmetic result (fig3).

DISCUSSION

There are many different modalities of treatment including curettage and bone grafting, grafting with fibular sturt etc. Currently the curettage and bone grafting is most commonly used procedure. Due to the risk of recurrence after curettage and grafting alone various forms of adjunctive therapy have been used to decrease the rate of local recurrence. In some cases cryosurgery ^[11] and sclerotherapy were used as an adjuvant intralesional treatment for aneurysmal bone cyst arising in the hand. These treatments are difficult to use in the small bones of the hand and may damage surrounding intact tissue and cause serious complications such as neuropraxia, postoperative fracture, burn, infection. Low-dose irradiation has also been reported to be an effective method of treatment however it is not used routinely because of potential for malignant transformation and wound necrosis, which may happen more easily in distal lesions. En-block resection and reconstruction with strut grafting is another operative treatment option. Given the aggressive nature of aneurysmal bone cysts with the tendency to develop recurrence, en-block resection seems to be the therapy of choice. No recurrence has been reported after en-block resection in the relevant literature. ^[12] Despite it being a curative method of treatment, its use is limited, particularly in cases where the lesion is close to articular surfaces. Long operation time the need for microsurgical skills, and donor site complications are major problems

associated with these techniques. Otherwise, reconstruction can only be achieved with arthrodesis, which may impair hand function.

In our case, excellent clinical and functional results were obtained with curettage and reconstruction with autologous iliac cancellous bone graft with no recurrence after three year follow-up.

CONCLUSION

The curettage of cystic lesion of metacarpal with bone grafting with autologous iliac cancellous bone graft is a good choice for treatment for Aneurysmal bone cyst of hand bone with good result in our patient. It gives structural construct with full return of functional activity, without any signs of recurrence.

REFERENCES

1. Maroldi, Roberto (2005). Imaging in Treatment Planning for Sinonasal Diseases. Springer. p. 114. ISBN 9783540266310
2. Athanasian EA, McCormack RR. Recurrent aneurysmal bone cyst of the proximal phalanx treated with cryosurgery:a case report. *J Hand Surg Am.* 1999;24(2):205-412.
3. Pediatric Orthopedics in Practice. Springer. 2007. pp. 151–155. ISBN 9783540699644.
4. Basarir K, Saglik Y, Yildiz Y, Tezen E. Aneurysmal bone cyst of the hand: a report of four cases. *Hand Surg.* 2006; 11(1-2):35-41.
5. Braatz F, Popken F, Bertram Ch, Rutt J, Hackenbroch MH. Aneurysmal bone cyst of the fourth of the fourth metacarpal bone- a case report [in German]. *Handchir Mikrochir Plast Chir.* 2002;34(2):128-132.
6. Buraczewski J, Dabska M. Pathogenesis of aneurysmal bone cyst. Relationship between the aneurysmal bone cyst and fibrous dysplasia of bone. *Cancer.* 1971;28(3):597-604.

7. Campanacci M. Aneurysmal bone cyst; In: Campanacci M, ed. Bone and Soft Tissue Tumors. Bologna, Italy: Aulo Gaggi Editore; 1990:725-751.
8. Frassica FJ, Amadio PC, Wold LE, Beabout JW. Aneurysmal bone cyst: clinicopathologic features and treatment of ten cases involving the hand. J Hand Surg Am. 1988;13(5):676-683.
9. Jaffe HL, Lichtenstein L. Solitary unicameral cyst with emphasis on the roentgen picture, the pathologic appearance and the pathogenesis. Arch Surg. 1942; (44): 1004-1025.
10. Koskinen EVS, Visuri TI, Holmstrom T, Roukkula M. ABC Evaluation of resection and of curettage in 20 cases. Clinical ortho 1976,118:136-146.
11. Schreuder HW, Veth RP, Pruszczynski M, Lemmens JA, Koops HS, Molenaar WM. Aneurysmal bone cysts treated by curettage, cryotherapy and bone grafting. J Bone Joint Surg Br. 1997; 79(1):20-5
12. Kotwal PP, Jayaswal A, Singh MK, Dave PK. Aneurysmal bone cyst in the metacarpal of a child a case report. J Hand Surg Br. 1988;13(4): 479-480.

How to cite this article: Surwade AP, Saindane KA, Godghate N et. al. Aneurysmal bone cyst of third metacarpal: an unusual presentation. Int J Health Sci Res. 2015; 5(1):394-397.

International Journal of Health Sciences & Research (IJHSR)

Publish your work in this journal

The International Journal of Health Sciences & Research is a multidisciplinary indexed open access double-blind peer-reviewed international journal that publishes original research articles from all areas of health sciences and allied branches. This monthly journal is characterised by rapid publication of reviews, original research and case reports across all the fields of health sciences. The details of journal are available on its official website (www.ijhsr.org).

Submit your manuscript by email: editor.ijhsr@gmail.com OR editor.ijhsr@yahoo.com