



Case Report

Incidental Lesions of Appendix - Case Reports

Sandhya Panjeta Gulia^{1*}, Kalaivani Selvi^{2**}, Lavanya. M^{3*}

¹Associate Professor, ²Senior Resident, ³Assistant Professor,

*Dept. of Pathology, Sri Venkateshwaraa Medical College Hospital and Research Centre, Ariyur, Pondicherry.

**JIPMER, Pondicherry, India.

Corresponding Author: Sandhya Panjeta Gulia

Received: 10/11/2014

Revised: 08/12/2014

Accepted: 12/12/2014

ABSTRACT

Acute abdomen presenting as acute appendicitis is very common but the exact etiology can be confirmed only by histopathological examination. Here we present three cases of acute appendicitis reported as – isolated appendicular tuberculosis, enterobiasis and carcinoid tumor with incidence of 0.1-0.6%; 0.2-41.8% and 1-2 cases/1000 appendectomies.

Keywords – acute appendicitis, carcinoid, enterobiasis, histopathological, tuberculosis

INTRODUCTION

Acute appendicitis presenting as an acute abdomen in the emergency unit of the hospital is not unusual. The accurate diagnosis depends on the histopathological

examination of the resected specimen which can reveal some unusual findings in the appendix which appear to be grossly normal intra-operatively.

Table 1: shows incidental lesions of appendix reported on histopathology

Age	Clinical diagnosis	Gross examination	Microscopic picture	Histopathological diagnosis
16/F	Acute appendicitis	4.5cm; outer surface-congested ; presence of grey yellow mass in the tip of appendix measuring.0.5x0.5cms	mucosal erosion with edema;submucosa shows islands and nests of tumor cells with peripheral palisading of nuclei,monotonous appearance with moderate amount of cytoplasm and central round stippled nucleus, no mitoses seen. The nests of cells have infiltrated the muscularis propria. Inflammatory infiltrate predominantly neutrophils are seen in all the layers extending upto the serosa.	Carcinoid tumor with acute appendicitis
23/M	Acute appendicitis; appendicular mass	part of appendix measuring 2cm ; outer surface congested; cut surface- lumen patent	multiple epithelioid granulomas with langhans giant cells infiltrating the submucosa, muscularis propria up till the serosa AFB stain – negative	Appendicular tuberculosis
32/M	Acute appendicitis	6.5cms , congested outer/surface ; cut/surface – lumen obstructed	focal mucosal ulceration, exudate and cut sections of adult worm of enterobius vermicularis in lumen , mixed inflammatory cell infiltrate (lymphocytes,plasma cells, eosinophils) in lamina propria with congested serosal blood vessels	Acute on chronic appendicitis with enterobiasis.

Tuberculosis of the appendix occurs as primary or secondary disease, the former being rare with incidence of 0.1%-0.6%. [1] Isolated appendicular tuberculosis is a rare lesion with wide variety of clinical presentation and is confirmed by histopathological examination.

The incidence of enterobius infestation in patients with symptoms of appendicitis ranges from 0.2-41.8%. [2]

Carcinoid tumors are the most common neoplasm of the appendix [3] with incidence of 1-2 cases per 1000 appendectomies in surgical specimens. [4]

Here we report a variety of lesions in the appendix which presented as an acute episode of appendicitis- tuberculosis, carcinoid of the appendix and enterobius vermicularis infestation of the appendix.

DISCUSSION

Secondary involvement of the appendix from ileocaecal tuberculosis is uncommon due to the fact that there is minimal contact of appendicular mucosa with intestinal contents. [5] Three clinical types of tuberculous appendicitis have been described in literature [6] - acute type indistinguishable from pyogenic appendicitis until histologically proven; chronic form with vague abdominal pain, diarrhea, vomiting and mass in the right iliac fossa indistinguishable from ileocaecal tuberculosis and; third type is a latent one found incidentally on histopathological examination. Our case (figure.1) is the chronic type similar to one described by Nuwal et al in 2000. [5] The exact mechanism of involvement of the appendix remains unclear. The various ways by which the appendix can be involved are - hematogenous, infected intestinal contents and extension of disease from neighbouring ileocaecal or genital tuberculosis. [7] Patient presented with history of recurrent pain in the right iliac fossa with hematological

investigations, CXR and ESR within normal limits. USG revealed presence of an appendicular mass. Our patient was put on anti tubercular treatment and showed improvement on follow up.

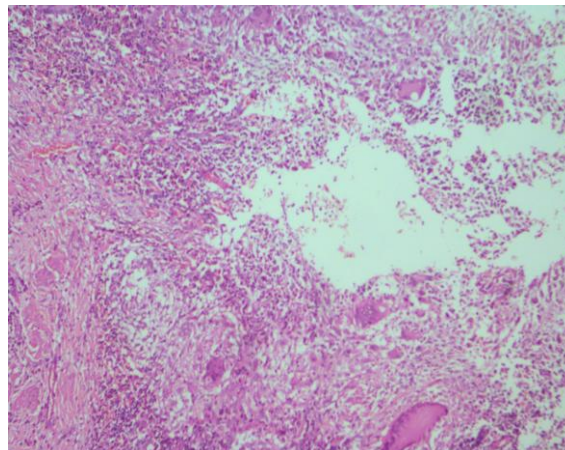


Figure 1. shows low power view(10X , H&E) of appendix with multiple granulomas composed of caseation necrosis, langhans giant cells, epithelioid cells, lymphocytes and fibroblast:- Appendicular Tuberculosis

The incidence of enterobius vermicularis infestation in patients presenting with symptoms of acute appendicitis ranges from 0.2-41.8%. [8] Infection mainly occurs through feco-oral route and the spectrum of manifestations can vary from asymptomatic cases to non specific features of perianal pruritis, decreased appetite, loss of sleep, mimics acute appendicitis without any histological evidence of acute inflammation or can produce no tissue reaction or chronic inflammatory infiltrate with eosinophilia. [9] Our case was 32 years male who presented with acute onset of pain in the right iliac fossa, vomiting with laboratory investigations showing leukocytosis and raised ESR. Appendectomy was performed and the specimen was sent for histopathology. The report of acute appendicitis with enterobiasis (figure.2) was given. Patient was put on antihelminthics in the post operative period.

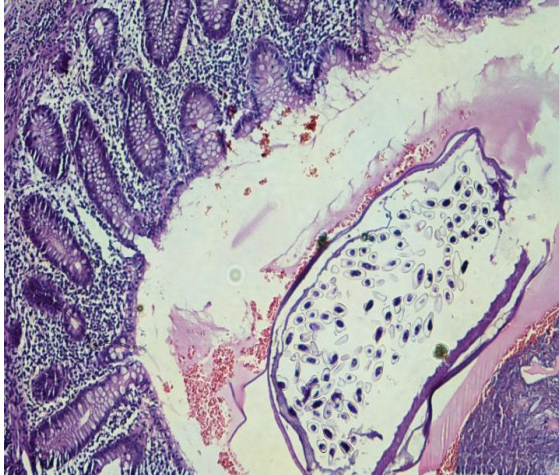


Figure.2 shows (10X,H&E) section of the appendix with cut section of enterobius worm in the lumen

Carcinoid tumors are neuroendocrine tumors derived from argentaffin cells and secrete catecholamines. These tumors can arise from gastrointestinal tract, ovary, testis, bronchopulmonary system, ovary, testis,. Within GIT 26% are found in appendix, 15% ileum, 11.3% rectum, 4.1% in caecum. [10] In the study conducted by Guraya et al [11] 9 cases of appendiceal carcinoids removed surgically were diagnosed by histological analysis. Our case patient presented with history of vomiting and pain in the right iliac fossa. Physical examination revealed mildly elevated temperature, neutrophilic leukocytosis, raised ESR with an inflamed appendix on

USG. Majority of the carcinoids are localized at the tip (75%), 20% mid portion and 5% base. [12] The mean age of the patients according to the study is 32.7 years (20-59 years) [15] in contrast to our patient with age 16 years. In a study conducted by Jones et al, 46 unexpected findings were reported on biopsy sections – parasites (10), endometriosis (3), benign tumors (carcinoid-13; polyps-4; cystadenoma-6) and malignancies (2). [13] Only 2 of these were suspected by the surgeon intra-operatively on the basis of finding a firm yellow material at the tip. In our case the probable diagnosis was made on the gross examination of the specimen which was confirmed by histopathological examination (figure.3). The treatment of choice for the lesions less than 2 cm is appendectomy while the size, site and metastasis decides for an extended surgery. In a review, Goede et al. describe that acceptable indications for re-intervention represented by all lesions larger than 2 cm in diameter, histological evidence of mesoappendiceal extension, tumours at the base of the appendix with positive margins or involvement of the caecum, high-grade malignant carcinoids and goblet cell adenocarcinoids. [14]

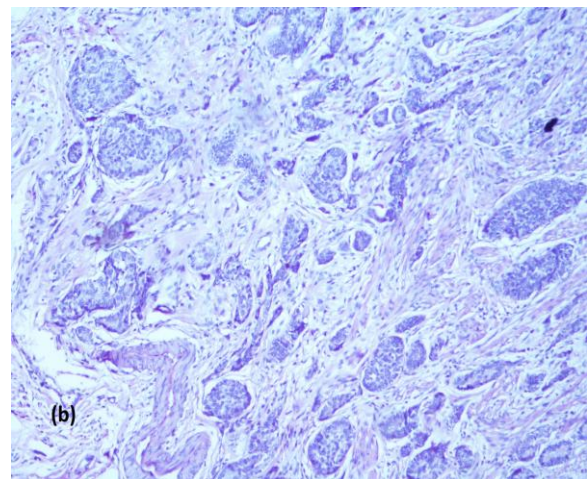
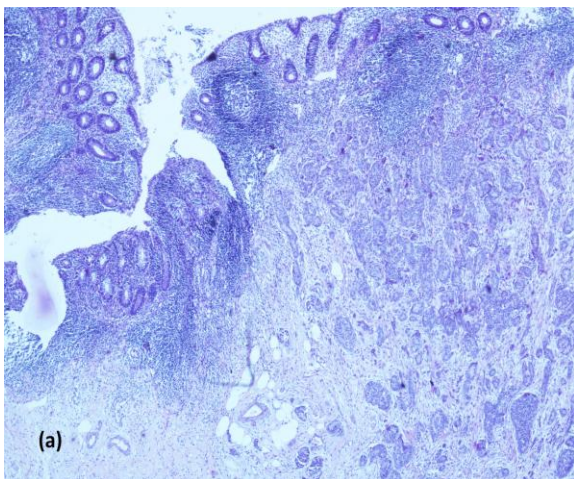


Figure 3. (a) shows low power view (H&E, 10X) – ulcerated mucosa of the appendix with infiltration of the muscularis propria with islands and nests of tumor cells. (b) monotonous appearing tumor cells – Carcinoid tumor of appendix

In the study done by Abdulrahman Saleh Al-Mulhim, the histopathological examination revealed varieties of lesions (parasites - enterobius and schistosomiasis, crohns disease, endometriosis, carcinoid and adenocarcinoma), not detected at operation. Not all the incidental pathological findings have clinical significance), but some finding (tumors) need further patient management. [15]

CONCLUSION

Hence it is imperative that the patient management and follow up depends on the histological reports as to start anti-helminthic treatment; or anti-tubercular treatment or to subject the patient to chemotherapy depending on the biopsy reports.

REFERENCES

1. Shah RC, Mehta KN, Jullundwala JM. Tuberculosis of appendix. J Indian Med Assoc 1967;49:138-40
2. Eleni Efraimidou, Anthia Gatopoulou, Charilaos Stamos, Nikolaos Lirantzopoulos and George Kouklakis. Enterobius Vermicularis infection of the appendix as a cause of acute appendicitis in a Greek adolescent: a case report. Cases Journal 2008,1:376 doi:10.1186/1757-1626-1-376
3. Kulke MH, Mayer RJ: Carcinoid tumor. N Engl J Med 1999 , 340:858-864
4. Godwin JD 2nd: Carcinoid tumors : An analysis of the 2837 cases.Cancer 1975,36:560-569
5. Paras I Nuwal, Ramakant Dixit, SudltaJain , VandanaPorwal. Isolated Appendicular Tuberculosis – A Case Report. Ind J Tub 2000;47:241-242
6. Bobrow ML, Friedman S. Tuberculous Appendicitis. Am J Surg 1956;91:389(PUBMED)
7. AS Ammanagi, VD Dhobale, BV Patil , AT Miskin. Isolated Appendicular Tuberculosis. Glob Infect Dis.2011;3(1):102-103 (doi:10.4103/0974-777X.77312) (PMCID:PMC3068570)
8. EleniEfraimidou, AnthiaGatopoulou, CharilaosStamos, Lirantzopoulos and George Kouklakis. Enterobius Vermicularis infection of the appendix as a cause of acute appendicitis in a greekadolescent:a case report. Cases Journal 2008, 1:376 doi:10.1186/1757-1626-1-376
9. UjwalKumar , NK Jha , DK Sinha. Acute Appendicitis due to Enterobius Vermicularis in a middle aged adult , rare finding – A Case Report. IOSR-JDMS 2013;6(1):49-50
10. Memon MA, Nelson H. Gastrointestinal carcinoid tumors: Current management strategies. Dis Colon Rectum 1997;40:1101-1118
11. Salman Y Guraya, GamalA.Khairy , Alia Ghallab, Abdulaziz Al-Saigh. Carcinoid tumors of the appendix:Our experience in a university hospital. Saudi Med J 2005;26(3):434-437
12. Prommegger R, Obrist P, Ensinger C, Miturmair R, Hager J. Retrospective evaluation of carcinoid tumors of the appendix in children. World J Surg 2002:1489-1492
13. Alun E Jones,Alexander W Phillips, Jonh R Jarvis,Kevin Sargen. The value of routine histopathological examination of appendicectomy specimens.BMC Surgery 2007;7:17
14. Goede AC,Caplin ME,Winslet MC.Carcinoid tumor of the appendix.Br J Surg 2003;90:1317-1322
15. Abdulrahman Saleh Al-Mulhim. Unusual findings in appendicectomy

How to cite this article: Gulia SP, Selvi K, Lavanya M. Incidental lesions of appendix - case reports. Int J Health Sci Res. 2015; 5(1):377-381.

International Journal of Health Sciences & Research (IJHSR)

Publish your work in this journal

The International Journal of Health Sciences & Research is a multidisciplinary indexed open access double-blind peer-reviewed international journal that publishes original research articles from all areas of health sciences and allied branches. This monthly journal is characterised by rapid publication of reviews, original research and case reports across all the fields of health sciences. The details of journal are available on its official website (www.ijhsr.org).

Submit your manuscript by email: editor.ijhsr@gmail.com OR editor.ijhsr@yahoo.com