

Case Report

Juvenile SLE Presenting As Digital Gangrene - A Case Report

Rajendra Prasad Nagar¹, Anand Kumar Gupta², Teena Nagar³¹Assistant Professor, Department of Pediatrics, Jhalawar Medical College, Jhalawar, Rajasthan.²Senior Resident, Department of Paediatrics, All India Institute of Medical Sciences, New Delhi.³Assistant Professor, Department of Obstetrics and Gynaecology, Jhalawar Medical College, Jhalawar, Rajasthan.

Corresponding Author: Rajendra Prasad Nagar

*Received: 16/09/2015**Revised: 12/10/2015**Accepted: 15/10/2015*

ABSTRACT

Juvenile Systemic lupus erythematosus (SLE) is one of the common connective tissue diseases in children. Systemic lupus erythematosus (SLE) usually presents as pyrexia of unknown origin, constitutional, mucocutaneous, musculoskeletal and renal symptoms. Digital gangrene as an initial presentation is very uncommon in paediatric Systemic lupus erythematosus (pSLE). We are reporting a case of 6 year old female child who presented with digital gangrene and later on investigation found to have Systemic lupus erythematosus.

Key-words: Juvenile SLE, Digital gangrene.

Key Messages: Although digital gangrene in Juvenile SLE is very rare but one should keep high index of suspicion while evaluating a case of digital gangrene.

INTRODUCTION

Juvenile systemic lupus erythematosus (SLE) is a multisystem autoimmune disorder that is characterized by widespread immune dysregulation, formation of autoantibodies and immune complexes, resulting in inflammation and potential damage to a variety of organs. Peripheral gangrene is a uncommon as presentation in children with systemic lupus erythematosus. ^(1, 2) SLE in children has many manifestations. Wananukul et al also described that cutaneous manifestations were shown to be the second most common findings, after renal problems. ⁽³⁾

There are few case reports of digital gangrene in juvenile SLE. ^(4,5) We are presenting this case to highlight the importance of knowledge of uncommon

clinical manifestation in SLE at presentation and treatment of critical digital ischemia.

CASE REPORT

6 Year old female child admitted in hospital with complains of weakness for 2 ½ month and blackish discolouration of skin over all digits mainly in left foot for last 20 days followed by involvement of both lower limb associated with pain. Involved limbs also have demarcation between blackish and normal area. [Figure 1] History of paleness of finger during exposure to cold was also there. Apart from these complains there was no history of fever, photosensitivity, joint pain, oral ulcer and seizure. Past history and family history was non contributory.

At admission child was febrile with temperature- 100 F, heart rate was 106/min, respiratory rate was 24/min, blood pressure was 90/54 mm of Hg and capillary refill time was <3 second. General physical examination was normal except pallor and dry gangrene of multiple digits in both lower limbs. Some digits showing developing discoloration associated with pain. Systemic examination was apparently normal.

In view of digital gangrene and doubtful history of Reynaud's phenomena possibility of SLE with prothrombotic state or antiphospholipid antibody syndrome, exaggerated Reynaud's, and vasculitis was kept and investigated for these.

Her investigation showed haemoglobin-6.1gm%, total leucocyte count - 6500/mm³ (neutrophil-61%, lymphocyte-34%) and platelets were 1,76,000/mm³. Peripheral smear showed microcytic hypochromic anaemia with few target cell and reticulocyte count was 1%. PT (INR) - 15/13 (1.2), APTT-41/31 and TT was 16/16. Urea -14mg%, creatinine-0.5mg%, sodium-145meq/lit, potassium-4.2 meq/lit. Bilirubin- 0.6 mg/dl, SGPT-99 IU, SGOT- 71 IU and alkaline phosphatase was 149 IU.

C - reactive protein -52 mg/dl (high), ESR was 76 mm in 1st hour (elevated). Urine routine and microscopic examination was normal and urine and blood culture was sterile. 24 hour urine protein was 125 mg.

Antinuclear antibody level was 1:320 (homogenous pattern), anti dsDNA - 344 (high) and C3 was normal. Viral markers (HIV, HbsAg, and HCV) were negative. ANCA, Cryoglobulin, Rheumatoid factor were negative. Work up for antiphospholipid antibody syndrome (anticardiolipin antibody, lupus anticoagulant and B2 microglobulin) were negative. Prothrombotic workup including antithrombin C, APC resistance, protein C and S were normal.

Ultrasound abdomen showed mild hepatomegaly. Skin biopsy from discoloured part showed ischemic necrosis and there was no evidence of vasculitis. Fundus examination was normal.

At the time of admission in view of critical digital ischemia in some finger child was started on steroid, low molecular weight heparin and nifedipin. Later HCQs was also added. During the hospital stay pain subsided and there was no progression of gangrene. During follow up visit she was well and one digit amputated automatically and other digits were normal.

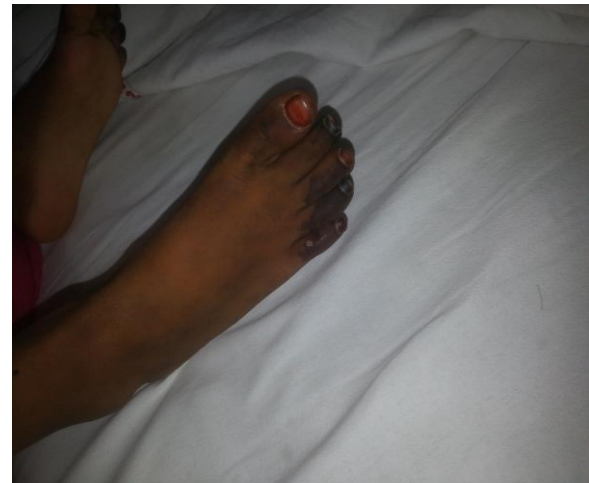


Figure 1: Showing gangrene of fingers

DISCUSSION

Paediatric systemic lupus erythematosus is multisystem disease. There is very scarce data about paediatric SLE in India. Constitutional, musculoskeletal, renal and skin symptom are common presenting feature but digital gangrene and Reynaud's phenomena are describes as uncommon manifestation. (2) Long duration of disease, Raynaud's phenomena and elevated inflammatory markers are predictive factor for SLE to develop peripheral gangrene. (6) There are various etiologies for peripheral gangrene in SLE i.e. antiphospholipid antibody, prothrombotic state, end arteritis, and vasculitis.

In adults there are many cases of digital gangrene as an initial manifestation

in SLE at presentation but in paediatric age group only few case report (till date only 2) are there. (4,5) Shetty et al (4) reported 11 month old girl infant with digital gangrene and treated with prednisolone. Vahid Ziaee et al (5) described 12 year female child who presented with digital gangrene and later found to be SLE with antiphospholipid antibody syndrome and treated with steroids and mycophenolate mofetil.

In our case child presented with digital gangrene only and later on investigation found to have positive for SLE but negative for antiphospholipid antibody, prothrombotic, vasculitis. Digital gangrene without these aetiologies is very rare in SLE. We also emphasized on aggressive treatment of critical digital ischemia which can save the ischemic digit and prevent progression of gangrene.

REFERENCES

1. Rosato E, Molinaro I, Pissari S, Salsano F. Digital ulcer as an initial manifestation of systemic lupus

- erythematous. Intern med 2011; 50:767-769.
2. Ahluwalia J, Naseem S, Singh S, Suri D, Das R. Prothrombotic profile in children with peripheral gangrene: a single center experience. Clin Appl Thromb Hemost 2011; 17: 497-501
3. Wananukul S, Watana D, Pongprasit P. Cutaneous manifestations of childhood systemic lupus erythematosus. Pediatr Dermatol 1998; 15:342-46.
4. Shetty VB, Rao S, Krishnamurthy PN, V U Shenoy. Peripheral gangrene during infancy: a rare presentation of systemic lupus erythematosus. Arch Dis Child 2001; 85: 335-36.
5. Ziaee V, Yeganeh MH, Moradinejad MH. Peripheral gangrene: A rare presentation of systemic lupus erythematosus in a child. Am J Case Rep 2013; 14: 337-340.
6. Liu A, Zhang W, Tian X, Zhang X, Zhang F, Zeng X. Prevalence, risk factors and outcome of digital gangrene in 2684 lupus patients. Lupus 2009; 18: 1112-1118.

How to cite this article: Nagar RP, Gupta AK, Nagar T. Juvenile SLE presenting as digital gangrene - a case report. Int J Health Sci Res. 2015; 5(11):400-402.

International Journal of Health Sciences & Research (IJHSR)

Publish your work in this journal

The International Journal of Health Sciences & Research is a multidisciplinary indexed open access double-blind peer-reviewed international journal that publishes original research articles from all areas of health sciences and allied branches. This monthly journal is characterised by rapid publication of reviews, original research and case reports across all the fields of health sciences. The details of journal are available on its official website (www.ijhsr.org).

Submit your manuscript by email: editor.ijhsr@gmail.com OR editor.ijhsr@yahoo.com