

*Case Report***Variant Anatomy of the Delto-Pectoral Region: Its Clinical Implications**Sandeep Saluja¹, Monika Gupta², Sarika Rachel Tigga³¹Senior Resident, Department of Anatomy, Maulana Azad Medical College, New Delhi, India-110002.²Assistant Professor, Department of Anatomy, RUHS college of Medical Sciences, Jaipur, Rajasthan.³Assistant Professor Dept. of Anatomy, ESIC Medical College & Hospital, NIT, Faridabad, Haryana, India.

Corresponding Author: Sarika Rachel Tigga

*Received: 29/08/2015**Revised: 21/09/2015**Accepted: 23/09/2015***ABSTRACT**

Extensive free/pedicled musculocutaneous flaps are essential pre-requisites for reconstruction in the breast, axillary, head and neck region. Such surgeries also require adequate or additional vascular supply at the recipient site. The segmental anatomy and neurovascular supply of the pectoral is major muscle aptly makes it the most favoured source of grafts, with a reliable source of vascular supply available from the adjoining thoraco-acromial arterial axis and cephalic vein. We report a case wherein the clavicular origin of pectoral is major muscle was pierced by the cephalic vein. The thoraco-acromial artery had a variant branching pattern with a peculiar presentation of the delto-pectoral groove and its contents. As facial and breast reconstruction surgeries rely on the availability and dependability of the aforementioned anatomical structures, any atypical presentations may cause intra-operative confusion and hinder the success of reconstructive procedures.

Keywords: Cephalic vein, Musculocutaneous flaps, Pectoral is major, Thoraco-acromial artery.

INTRODUCTION

A comprehensive understanding of the regional anatomy is critical in selecting the site from wherein a graft is to be harvested. A muscle becomes an ideal graft, if its freedom of mobility along with its neurovascular supply is coupled with the least functional deficit. The pectoralis major (PMj) muscle has been found to be appropriate for segmental splitting as it consists of segments as per their site of origin: clavicular, manubrial, sternocostal and abdominal. The muscle originates from the anterior surface of the sternal half of the clavicle, half the breadth of the anterior surface of the manubrium sterni and

adjacent second intercostal space, down to the level of the sixth or seventh costal cartilage with the anatomy of the abdominal segment being variable. [1] A dominant vascular pedicle is provided by the pectoral branch (Pbr) of the thoraco-acromial arterial (TAA) axis which courses under the PMj before giving rise to muscular branches as well as cutaneous perforators that supply the skin over the pectoral region. The majority of the muscle is drained by venae comitantes associated with the Pbr of the TAA, which then ultimately drain into the axillary vein. The overlying skin drains through venules accompanying the arterial perforators. The cephalic vein (CV) receives tributaries

draining from the overlying skin but does not form part of the PMj's venous drainage. [2] The presence of a dominant vascular pedicle along with musculocutaneous perforators aid the harvest of musculocutaneous flaps from the pectoralis major. This flap can be employed in reconstruction of head and neck areas and makes PMj, the most favoured graft resource. [3]

METHOD

During routine dissection conducted for medical undergraduate students, a variant anatomy of the pectoral region was observed in an embalmed 52 year old cadaver. After dissecting off the skin of the pectoral region and upper arm, the course, tributaries and termination of the cephalic vein were noted. The pectoral fascia and fat were removed to define the attachments of PMj and the muscle excised at its origin to visualize the TAA axis. The course and branching pattern of the TAA was noted and followed till its termination.

RESULT

The PMj muscles were inspected bilaterally and were found to have a normal mode of origin and nerve supply. The right PMj inserted onto the lateral lip of the bicipital groove while the left PMj had a linear insertion extending from the anterior border of the deltoid muscle, lateral lip of the bicipital groove and upto the anterior limb of the V-shaped deltoid tuberosity. As the tendinous fibres of PMj and deltoid muscles were merged, the delto-pectoral groove was not clearly defined. [Figure 1] The cephalic vein formed from the lateral distal continuation of the dorsal venous arch, coursed upwards along the lateral border of biceps brachii muscle. Instead of traversing the delto-pectoral groove, the vein inclined medially and crossed the groove obliquely, 3.7cm below the clavicle. At its termination

into the axillary vein, the CV pierced the clavicular origin of PMj just inferior to the middle of the clavicle. Further, we found a variant branching pattern of the thoraco-acromial artery. The artery was tortuous at its origin and gave off three branches- the clavicular (Cbr), acromial (Abr) and a common trunk of deltoid (Dbr) and pectoral (Pbr) branches. [Figure 2] The common trunk gave off two pectoral branches as it travelled infero-laterally upto a distance of 3.42 cm embedded within the PMj muscle and continued as the Dbr. At a site 4cms inferior and 3cm lateral to the emergence of CV, the Dbr of TAA pierced the PMj muscle and crossed the delto-pectoral groove obliquely to supply the deltoid.

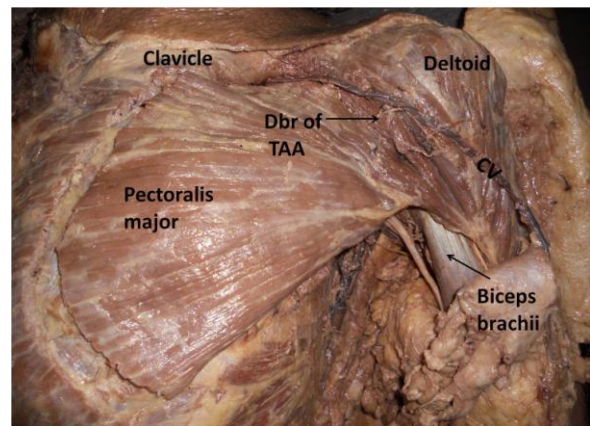


Figure 1: Dissection of left pectoral region and upper arm showing the cephalic vein (CV) piercing the clavicular origin of pectoralis major muscle. The linear insertion of the pectoralis major muscle is also seen. Dbr - Deltoid branch of thoraco-acromial (TAA) axis.

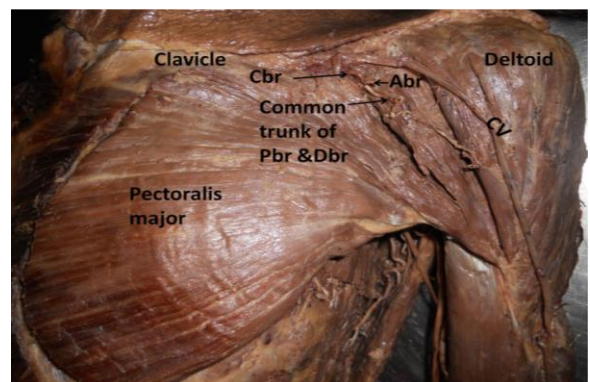


Figure 2: Dissection of the thoraco-acromial arterial (TAA) axis showing its three branches- the clavicular (Cbr), acromial (Abr) and a common trunk of deltoid (Dbr) and pectoral (Pbr) branches. CV- Cephalic vein.

DISCUSSION

At the proximal end of the early limb bud the muscles of the pectoral girdle occur at a region of indefinite transition between musculature of myotomic origin and that of mesenchymal limb bud origin and modifications of primitive segmental arrangement of the limb bud arise due to alterations in the intrinsic migration of its individual muscles during development. [4] Thus, possibility of anomalous arrangements should be kept in consideration to avoid complications during surgical procedures and to ensure better operative effect.

The surgical anatomy, vascular and nerve supply of the PMj muscle forms the basis for its transfer. Numerous variations in the PMj musculature have been documented ranging from complete to partial absence. Diverse levels of hypoplasia or accessory muscular slips also have been reported. [5] Beyond this, the clavicular heads of pectoralis major and deltoid muscles may be fused, making the delto-pectoral groove inconspicuous. [1] In such cases and as seen in the present report, the cephalic vein may pierce the muscular fibres to reach the axillary vein. [6] Another common affliction of the PMj is its susceptibility to muscular tears, which when coupled with that of deltoid are primarily sports related injuries. In cases like ours, combined insertions of PMj and deltoid cause confusion and hinder treatment but additional mobility of the PMj can be achieved by releasing the sterno-costal, clavicular attachments or humeral insertion of the muscle. [7] For reconstruction of elbow flexion in Arthrogryposis Multiplex Congenita (AMC) type I, a distal release (sterno-costal and abdominal) of the PMj as a unit is required and transferred to the brachium, but in cases like ours, where PMj is being perforated by vascular structures, patients may demonstrate the classic findings of venous obstruction and

treatment may prove to be unsatisfactory with future recurrences. [8]

The use of pedicled musculocutaneous perforator flaps is favoured over conventional flaps in soft-tissue reconstruction of head and neck defects. Of the three major arteries supplying the PMj muscle, the Pbr of the TAA supplies the largest muscular vascular territory. The artery predominantly (60%) gives off three secondary branches and its detailed knowledge is useful in maximizing pedicle length and the arc of rotation of the muscle. As the size of the Pbr has been found to be inconsistent, its reliability is questionable, but musculocutaneous perforator flaps are possible from the Cbr and Dbr of the TAA. [9]

The lack of vessels at the recipient site is more common with veins than arteries. Though vessels may be present but they may not be utilizable. This results due to their elimination in radical excision or because of scarring, irradiation and trauma from previous surgery. The cephalic vein with its relatively constant anatomy is considered a reliable source of venous drainage where there is non-availability of veins or when additional venous drainage is required. [10,11] It is also employed in creation of AVF (arterio-venous fistulas) for dialysis which relies on superficial veins i.e. the cephalic and the basilic veins. In cases of anatomic variability, the cephalic arch (portion that dips down in the infraclavicular region) is vulnerable for stenosis in the setting of high flows resulting from the AVF. [12]

CONCLUSION

Surgeons need to be well versed with the anatomy of the pectoral region, which is relatively simple and easily approachable. The evaluation of the vascular anatomy using a duplex ultrasonographic probe or real time mapping is extremely useful and

should be considered by the operating surgeon to decide on the A-V segment for fistula creation or muscle segment that has the potential to develop into an adequate graft.

Conflict of interest: None

REFERENCES

1. Johnson D, Collins P, Healy JC. Pectoral girdle, shoulder region and axilla. In: Standring S, editor. Gray's Anatomy: The Anatomical Basis of clinical practice. 40th ed. Spain: Elsevier Churchill Livingstone; 2008. P.807-8.
2. Bakri K, Mardini S, Evans KK, Carlsen BT, Arnold PG. Workhorse flaps in chest wall reconstruction: The pectoralis major, latissimus Dorsi and rectus abdominis flaps. *Semin Plast Surg.* 2011;25(1):43-54.
3. Bussu F, Gallus R, Navach V, Bruschini R, Tagliabue M, Almadori G, Paludetti G, Calabrese L. Contemporary role of pectoralis major regional flaps in head and neck surgery. *Acta Otorhinolaryngol Ital.* 2014; 34(5):327-41.
4. Sadler T.W. Langman's medical embryology. 11th ed. New delhi: Wolters Kluver (India) Pvt. Ltd; 2010; 150-1.
5. Huber KM, Boyd TG, Quillo AR, Wilhelmi BJ. Implications of anomalous pectoralis muscle in reconstructive breast surgery: The Oblique Pectoralis Anterior. *Eplasty [Internet].* 2012 [cited 2012 Sep 10]; 12:e44.
6. Perrin J.B. Notes on some variations of the pectoralis major, with its associate muscles. *J Anat Physiol.* 1871; 5:233-40.
7. Hanna CM, Glenny AB, Stanley SN, Caughey MA. Pectoralis major tears: comparison of surgical and conservative treatment. *Br J Sports Med* 2001; 35:202-6. doi:10.1136/bjsm.35.3.202.
8. Chomiak J, Dungal P. Reconstruction of elbow flexion in arthrogryposis multiplex congenita type I. Part I: surgical anatomy and vascular and nerve supply of the pectoralis major muscle as a basis for muscle transfer. *J Child Orthop* 2008; 2(5):357-64.
9. Geddes CR, Tang M, Yang D, Morris SF. An assessment of the anatomical basis of the thoracoacromial artery perforator flap. *Can J Plast Surg* 2003; 11(1):23-27.
10. Loukas M, Myers CS, Wartmann ChT, Tubbs RS, Judge T, Curry B, Jordan R. The clinical anatomy of the cephalic vein in the deltopectoral triangle. *Folia Morphol (Warsz).* 2008; 67(1): 72-7.
11. Shankhdhar VK, Yadav PS, Dushyant J, SeethaRaman SS, and Chinmay W. Cephalic vein: Saviour in the microsurgical reconstruction of breast and head and neck cancers. *Indian J Plast Surg.* 2012; 45(3): 485-493.
12. Shenoy S. Surgical anatomy of upper arm: what is needed for AVF planning. *J Vasc Access* 2009; 10(4): 223-32.

How to cite this article: Saluja S, Gupta M, Tigga SR. Variant anatomy of the delto-pectoral region: its clinical implications *Int J Health Sci Res.* 2015; 5(10):347-350.
