



Case Report

Tuberculous Epiglottitis - A Rare Case Report

Shivani Joshi¹, Meera Mahajan², Suparna Bindu³, Anil Vare³, Smita Mulay⁴

¹Chief Resident, ²Lecturer, ³Associate Professor, ⁴Head of Department and Professor;
Department of Pathology, MGM Medical College and Hospital, Aurangabad, India.

Corresponding Author: Shivani Joshi

Received: 27/05/2014

Revised: 14/06/2014

Accepted: 18/06/2014

ABSTRACT

Tuberculosis is a chronic bacterial infection caused by tubercular mycobacterium. Tuberculosis ranks high almost the major health problems in developing countries like India. Laryngeal tuberculosis is a very rare. It accounts less than 1% of all extrapulmonary tuberculosis. In larynx parts affected are

- i. interarytenoid folds
- ii. ventricular bands
- iii. vocal cords
- iv. epiglottis (in that order)

Tuberculous epiglottitis is very rare.

We present a case of tuberculous epiglottitis with active pulmonary tuberculosis. A 38 year old male presented with 4 months history of gradual onset of dysphagia, odynophagia, change in voice i.e. hot potato voice.

Indirect laryngoscopy revealed diffuse oedema, congestion and whitish spots over epiglottis. He underwent fiberoptic and microscopic direct laryngoscopy and biopsy was taken from epiglottis. Histopathological examination revealed typical granulomas consisting of caseation necrosis in centre surrounded by epithelioid cells, Langhans' giant cells and lymphocytes at periphery. The case was diagnosed as tuberculous epiglottitis.

Chest radiography showed ill defined bilateral extensive opacities. Sputum examination was positive for acid – fast bacilli(4+).

Key words: Tuberculous epiglottitis, Larynx, Granuloma.

INTRODUCTION

Tuberculosis is a chronic bacterial infection caused by tubercular mycobacterium which by its cell mediated immunity forms characteristic granuloma in the affected tissue. Tuberculosis ranks high amongst the major health problems in developing countries like India. The most common organ to be affected is the lung;

however it can affect other organs too. [1]

Tuberculosis is a systemic disease and its occurrence in the larynx and oral cavity is well documents in literature. [2] Laryngeal tuberculosis is very rare. It accounts for less than 1% of all extra pulmonary tuberculosis. [3] The disease affects the posterior part of larynx more than the anterior. Parts affected are:

- i. Interarytenoid folds
- ii. Ventricular bands
- iii. Vocal cords
- iv. Epiglottis (in that order) [4]

Tuberculous epiglottitis is very rare. In this report, we present a case of tuberculous epiglottitis with active pulmonary TB.

CASE REPORT

A 38 year old male, presented with 4 months history of gradual onset of dysphagia, odynophagia, change in voice i.e. hot potato voice. There was associated preceding history of dry irritating cough, weight loss and occasional low grade fever. Patient was non smoker and with no history of contact of pulmonary tuberculosis.

On general examination, his vitals were within normal limits. There was no cervical lymphadenopathy or clubbing. There were no scars and sinuses in the neck. Indirect laryngoscopy had shown diffuse edema, congestion and whitish spots over the epiglottis. Rest of the laryngeal structures did not show any signs of inflammation or infiltration.

His respiratory system examination revealed bilateral equal breath sounds with no added sounds or any abnormalities. Rest of the

systems were normal. Routine blood investigations were all within normal limits. He underwent direct laryngoscopy and biopsy was taken from the epiglottis [Fig 1].

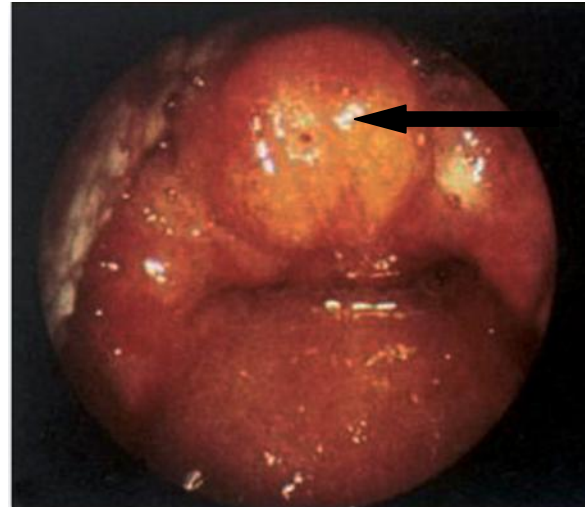


Fig 1. Laryngoscopy showing diffuse edema, congestion and whitish spots over the epiglottis.

Histopathological examination revealed typical granulomas consisting of caseation necrosis in the center surrounded by epithelioid cells, Langhan's giant cells and lymphocytes at the periphery. The case was diagnosed as Tuberculous Epiglottitis. [Fig 2,3]

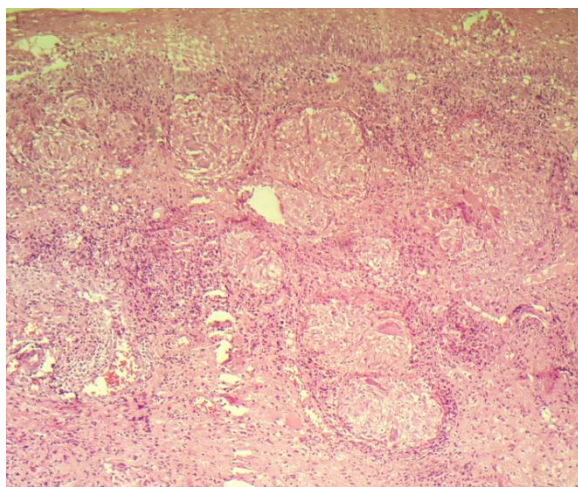


Fig 2. Low power view (10x) H and E stain, showing stratified squamous epithelium with multiple granulomas.

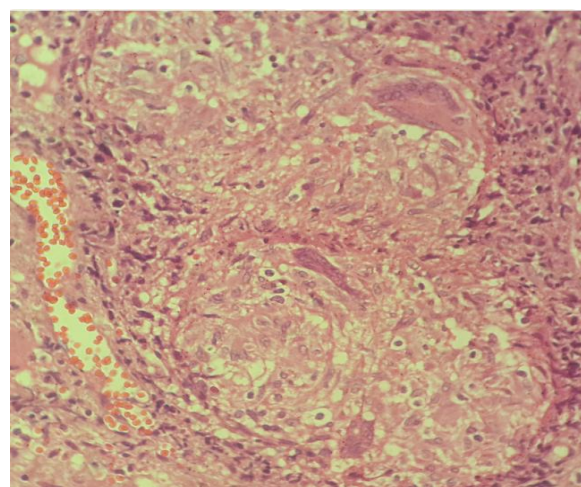


Fig 3. High power view (40x) H and E stain, showing granulomas with caseation, Langhans' giant cells, epithelioid cells and lymphocytes.

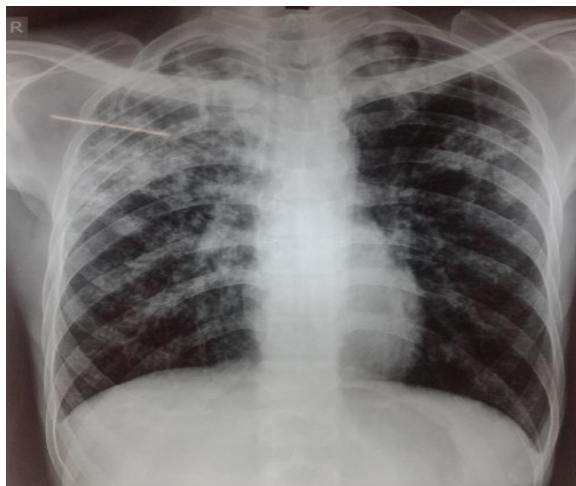


Fig 4. Chest radiography showing ill defined bilateral extensive opacities.

Chest radiography showed ill defined bilateral extensive opacities [Fig 4]. Sputum examination was positive for acid fast bacilli(4+).

On the basis of the bacteriologic, radiologic and histopathologic findings the diagnosis of pulmonary tuberculosis of epiglottis was established.

A standard 6 months treatment with a combination of Isoniazid, Rifampicin, Pyrizinamide and Ethambutol was started for 2 months followed by Isoniazid and Rifampicin for further 4 months. Clinically he responded well to the treatment and laryngoscopy showed resolution of epiglottic mass and remained stable on routine 1 year follow up.

DISCUSSION

In 1882, Robert Koch quoted, “If the number of victims which a disease claims is the measure of its significance, then all diseases particularly the most dreaded infectious diseases, such as bubonic plague, Asiatic cholera, etc., must rank far behind tuberculosis.” [5]

The incidence of tuberculosis in India is 181 per 1, 00,000 people in 2010. [6] Incidence of tuberculosis is now on a rise due to increase in incidence of autoimmune

deficiency syndrome and other immunosuppressive states. [1] In pre-antibiotic era, tuberculosis was considered as the most common disease of the larynx affecting 35-83% of patients with TB and the mortality rate was 45-90%. With the use of antituberculous medications, laryngeal involvement has decreased to less than 1% and the mortality rate decreased less than 2%. [7]

Mycobacterial infection generally affects posterior and glottic larynx and this situation is attributed to direct spread of infection by sputum. In some of the cases, the epiglottis is the primary site for TB without pulmonary involvement, implying possible hematogenous spread. [7]

Tubercle bacilli carried by sputum from bronchi settle and penetrate the intact laryngeal mucosa particularly in the interarytenoid region (bronchogenic spread). This leads to the formation of sub mucosal tubercle. [4] Primary tuberculosis involving epiglottis without pulmonary disease is very rare. [8]

The most common symptom is that of hoarseness which is present in almost all cases. Odynophagia is an important symptom, presenting in 45-90% of cases, which differentiates it from laryngeal carcinoma. Cough is less prominent and common, varying in incidence from 7-44%. Constitutional symptoms of weight loss, night sweats and fever are less common. [9]

The pathology of tuberculosis is the process and the consequence of interplay between the bacillus and host immunity. The relationship between the two can be varied, complex and can last lifelong. The host can win over the bacillus or the bacillus can overwhelm the host. At times the battle may stop for years, only to resume later on. All this is reflected in the gross and microscopic appearance of different organs. [5]

On laryngoscopic examination, there is pseudo edema of epiglottis, “Turban epiglottis”. [4] Inflammation, exophytic mass, obliteration of anatomic landmarks and ulcerative lesions of epiglottis are common findings. These can resemble carcinoma. [7]

Diagnosis is made by biopsy. Histological examination demonstrates granulomas with caseating necrotic centers, Langhans’ giant cells and acid fast bacilli. [10] Granulomas can be with or without caseating necrosis. [11] For the diagnosis of granulomatous lesion of epiglottis, tuberculosis, syphilis, sarcoidosis, Wegener’s granulomatosis, Cat scratch disease, fungal infections (e.g. histoplasmosis, blastomycosis, coccidiomycosis) and neoplastic lesions are to be considered as differentials. [12]

The response to anti tuberculosis treatment is another important diagnostic criterion. [1] Treatment is the same as pulmonary tuberculosis. [4] Our patient responded clinically well to antituberculous treatment and laryngoscopy showed resolution of epiglottic mass.

Epiglottis used to be considered as a rare location of TB. [7] An important arousal of tuberculosis has been observed in the last years, together with a change in its clinical pattern, specially the extra pulmonary form. Tuberculous epiglottitis is one of these atypical and unusual forms. [13]

Summary

A case of tuberculous epiglottitis with active pulmonary tuberculosis was presented. A 38 year old male presented with 4 months history of gradual onset of dysphagia, odynophagia, change in voice i.e. hot potato voice. On Indirect laryngoscopy revealed diffuse oedema, congestion and whitish spots over epiglottis. Biopsy taken from the epiglottis revealed histopathologically typical granulomas consisting of caseation necrosis in centre

surrounded by epitheloid cells, Langhans’ giant cells and lymphocytes at periphery. Chest radiography showed ill defined bilateral extensive opacities. Sputum examination was positive for acid – fast bacilli(4+). The case was diagnosed as tuberculous epiglottis. Epiglottis was considered to be as a rare location for TB.

CONCLUSION

The incidence of tuberculosis is now on a rise due to increase in the incidence of autoimmune deficiency syndrome and other immune-suppressive states. The successful management of patient with epiglottic tuberculosis relies on clinical suspicion, prompt diagnosis and early institution of appropriate antituberculous treatment. If recognized and treated early, potential spread to healthcare professionals and general public can be avoided by isolating the patient.

REFERENCES

1. Sachin Gandhi, Santosh Kulkarni, Prasun Mishra, Pallavi Thekedar, Tuberculosis of Larynx Revisited: a Report on clinical characteristics in 10 cases. Indian Journal of Otolaryngology and Head and Neck surgery 2012 september; 64(3) 244-247.
2. Galli J, Nardi C, Contucci AM, Cadoni G, Lauriola L, Fantoni M. Atypical isolated epiglottic tuberculosis: a case report and a review of the literature. American Journal of otolaryngology, head and neck medicine and surgery. Vol 23, issue 4, pages 237-240, July 2002
3. Anil Mehendiratta, Pravin Bhat, Lamartine D’Costa, A.M Mesquita and Nisha Nadkarni: Primary Tuberculosis of Larynx, Indian Journal of tuberculosis 1997. 44.211

4. P. L Dhingra , Diseases of Ear, Nose and Throat, 4th Edition, Pg No 270
5. Tuberculosis, Editor S. K Sharma , Jaypee Brothers, Medical publisher 1st edition 2001 pages 38-91
6. www.indexmundi.com/facts/india/incidence-of-tuberculosis
7. Celil Uslu. Cagatay Oysu. Burak Uklumen. European Arch of otolaryngology (2008) 265:599-601
8. Edizer DT, Karman E, Mercan H, Alimoglu Y, Esen T, Cansiz H. Primary tuberculosis involving epiglottis: a rare case report. Dysphagia.2010 sep; 25(3) 258-60
9. Naeem Ullah Khan, Seb Wallis, Naeem Siddiqui. Laryngeal tuberculosis: a diagnosis not be missed. BMJ case report 2009;2009 bcr 11.2208.1228
10. Andrew C Swift, Chapter 17, Acute infections of the larynx. Scott Brown's otorhinolaryngology. Head and Neck surgery. Volume 4; 7th edition, edited by Micheal Gleeson, Pg no 1182
11. Juan Rosai, Rosai and Ackerman's surgical pathology 10th Edition. Vol 1 Pg 320.
12. Rajesh Gupta , Sajay Fotedar, Pradeep Sanswal, SPS Yadav, Anupama Gupta, K.B Gupta and Kuldeep Soni. Indian journal of Tuberculosis 2008;55:100-103
13. Coscaron Blanco E, Santa Cruz Ruiz S, Serradilla Lopez JM. An Otorrinolaryngology Ibero, Am 2005; 32(1) 55-63.

How to cite this article: Joshi S, Mahajan M, Bindu S et. al. Tuberculous epiglottitis - a rare case report. Int J Health Sci Res. 2014;4(7):289-293.

International Journal of Health Sciences & Research (IJHSR)

Publish your work in this journal

The International Journal of Health Sciences & Research is a multidisciplinary indexed open access double-blind peer-reviewed international journal that publishes original research articles from all areas of health sciences and allied branches. This monthly journal is characterised by rapid publication of reviews, original research and case reports across all the fields of health sciences. The details of journal are available on its official website (www.ijhsr.org).

Submit your manuscript by email: editor.ijhsr@gmail.com OR editor.ijhsr@yahoo.com