



Original Research Article

## **Nocardia in Buccal Space Abscess - An Oral Manifestation: A Case Report**

Beena<sup>1\*</sup>, Rameez Raja<sup>2\*</sup>, Sandeep<sup>3\*</sup>, Kavitha Karur<sup>2\*</sup>, Peralam Yegneswaran Prakash<sup>3\*\*</sup>, Indumathi VA<sup>4\*</sup>

<sup>1</sup>Professor, <sup>2</sup>Post Graduate in Microbiology, <sup>3</sup>Assistant Professor, <sup>4</sup>HOD

\*Department of Microbiology, MS Ramaiah Medical College and Teaching Hospital, Gokul Extension, Bangalore.

\*\*Department Of Microbiology, Kasturba Medical College, Madhav Nagar, Manipal, Udipi District - 576 104

Corresponding Author: Beena

Received: 15/01/2014

Revised: 06/02/2014

Accepted: 13/02/2014

### **ABSTRACT**

Nocardia is a weekly staining gram-positive bacilli, forming partially acid-fast beaded branching filaments. Nocardia is found in soil rich in organic matter. They also form a part of oral microflora. Here, we report a case of oral nocardiosis in a 50-year-old male patient who was a known diabetic. He presented with painful swelling on the left side of the face since one year with intermittent pus discharge intra-orally. Incision and drainage was done for the abscess and pus was sent for routine culture and sensitivity, without suspecting nocardial infection. Gram stain of the pus showed numerous WBCs, occasional gram-positive cocci in clusters, and numerous filamentous gram-positive bacilli. Modified Ziehl-Neelsen stain of the pus sample showed acid-fast bacilli. Culture of the same yielded Nocardia asteroides (N. asteroides). The patient was treated with amikacin and amoxy-clavulanic acid to which he responded favourably.

**Keywords:** Buccal-space abscess, Nocardia asteroides.

### **INTRODUCTION**

Nocardia species are found in nature as soil saphrophytes. They are commonly reported as human pathogens and cause disease predominantly in immunocompromised hosts. They are aerobic, filamentous, gram-positive, partially acid-fast bacteria. The clinical presentation of nocardiosis includes localized cutaneous disease and pulmonary infection, often with dissemination to other organs.<sup>[1]</sup> Though Nocardia commonly causes infection in the immunocompromised patients which presents as disseminated type, it has also been reported to cause infections in immunocompetent patients wherein it

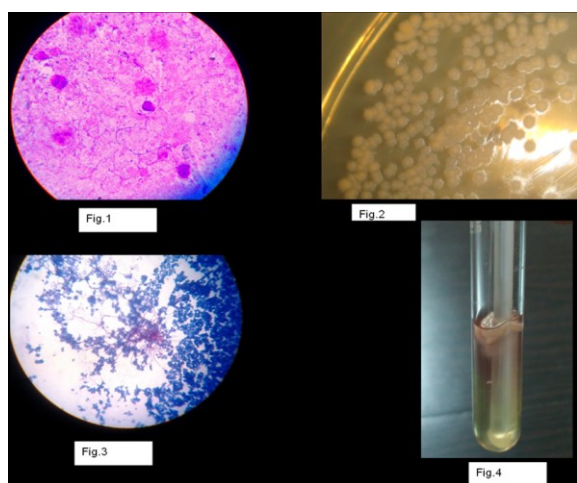
commonly presents as pustules, abscess, or cellulitis which can mimic diseases caused by more common organisms.

### **CASE REPORT**

A 50-year-old male patient who was a diabetic came to the Dental OPD with painful swelling on the left side of the face. Swelling was present since one year which used to enlarge and discharge pus intermittently. The swelling then extended extra-orally. The patient had adult-onset diabetes mellitus since 5 years and had uncontrolled blood sugar levels though on oral hypoglycemics. He had no apparent pulmonary manifestations of nocardiosis.

**On Examination:** Extra-orally, a well-defined swelling was seen over the left mandible measuring 5x5 cm. Intra-orally, mouth opening was restricted, pus discharge was seen near periodontal pocket of 2<sup>nd</sup> lower left molar tooth. Diagnosis was made as buccal space infection secondary to periodontitis of 2<sup>nd</sup> lower left molar.

**Investigations:** Intra-oral peri-apical radiograph revealed well-defined radiolucency interspersed with radio-opaque flecks.



Legends:

Fig.1 - Gram stain from the pus sample showing pus cells and filamentous gram-positive bacilli.

Fig.2 - Growth of *Nocardia asteroides* on Sabouraud's Dextrose Agar medium.

Fig.3 - Modified acid-fast staining with 1% sulphuric acid showing acid-fast filamentous bacilli.

Fig.4 - Paraffin bait technique for isolation of *Nocardia asteroides*.

Incision and drainage was done and pus was sent for culture and sensitivity. On Gram stain, numerous WBCs, occasional gram-positive cocci in clusters, and numerous filamentous weakly gram-positive, beaded bacilli suggestive of *Nocardia* species was seen (Fig 1). Acid-fast staining with 1% sulphuric acid showed long, filamentous, branching, acid-fast bacilli. Sample was inoculated onto MacConkey, blood agar (B A), Lowenstein-Jensen medium (LJ), Sabouraud's Dextrose agar (SDA). After 4 days of incubation at

37<sup>o</sup>C, small dry, wrinkled, creamy white colonies along with other white colonies appeared on B A, L J, SDA (Fig 2). Gram stain of the growth showed the presence of gram-positive cocci in clusters and filamentous gram-positive bacilli, which was confirmed as coagulase-negative staphylococcus and *Nocardia* species by culture. Acid-fast staining with 1% sulphuric acid from the culture also showed long, filamentous, branching acid-fast bacilli (Fig.3). Paraffin bait technique was done for isolating *Nocardia* species from the mixture.<sup>[2]</sup> (Fig.4). The isolate was sent to Kasturba Medical College, Manipal, for further speciation and was identified as *Nocardia asteroides*.

Patient was started on amoxicillin-clavulanic acid and amikacin that was continued after incision and drainage for two months. He responded to it and the swelling resolved. Further visit to the OPD did not show any recurrence.

## DISCUSSION

*Nocardiosis* was originally described by Nocard in cattle in 1888. Two years later, Eppinger (1890) reported the first human infection, a brain abscess. Members of the genus *Nocardia* are the aerobic actinomycetes and belong to the family *Mycobacteriaceae*. The *Nocardia* contain tuberculostearic acid but are different from mycobacteria in having shorter chain of mycolic acids. There are about 20-30 different spp and infection is produced by species like *N. asteroides*, *N. brasiliensis*, *N. caviae*.<sup>[3]</sup> *Nocardia* is known to involve almost every organ including lung, brain, kidney, pericardium, and eye. The most common presentation is pulmonary involvement with hematogenous dissemination to subcutaneous tissue and brain.<sup>[4]</sup>

*N. asteroides* is primarily an opportunistic pathogen which predominantly

causes deep-seated infection whereas *N. brasiliensis* causes superficial infection in a normal host with a history of trauma. *Nocardia caviae* is associated with mycetoma and fatal systemic infections.<sup>[5,6]</sup> Oral nocardiosis is a rare manifestation in general population. Normally, *Nocardia* is present as a normal commensal in oral cavity and occasionally can cause opportunistic infections in the immunocompromised. Different predisposing factors have been reported like corticosteroid therapy, diabetes mellitus, and HIV infection.<sup>[7]</sup> Suppression of cellular immunity in the immunocompromised host plays a key role in the establishment of nocardial infection.<sup>[8]</sup> Here, the patient was a diabetic, probably one of the reasons for a relatively immunocompromised state, and also had chronic periodontitis. *Nocardia* which exists as a normal flora could have become pathogenic here. The frequency of nocardial infections is on the rise, possibly as a consequence of more aggressive modern therapeutic measures; increase in organ transplants and immunosuppressive therapies leading to immunological abnormalities.<sup>[9]</sup> Host resistance to infection with *Nocardia* species is thought to depend on functioning of phagocytic cells. Neutrophils also limit the spread of infection in the early stage of tissue invasion. Activated macrophages and T-lymphocytes prevent dissemination and kill the bacteria. The crucial role of cell-mediated immunity has been proved in various studies, thus proving that *Nocardia* species behave as an opportunistic pathogen in an immunocompromised host.<sup>[10]</sup> Though most of the times nocardial infection is due to traumatic inoculation or dissemination, could be from lungs, here in this case there was no history of any injury or any pulmonary manifestation. So, probably the only source could be endogenous, where nocardia being a normal flora of mouth

would have become pathogenic due to his diabetic status. Nocardial infections have a tendency to recur, emphasizing the need for prolonged therapy. Although, trimethoprim-sulphamethoxazole is the first drug of choice for treating nocardiosis, successful treatment with other antibiotics have also been reported.<sup>[6]</sup> Here the patient responded to amikacin and amoxy-clavulanic acid well.

## CONCLUSION

A high degree of suspicion is needed to diagnose nocardial infection because of its resemblance to other bacterial infections. *Nocardia* may require longer incubation period for growth. Therefore, laboratories should be informed of the suspicion so that culture plates are incubated for a longer time. *Nocardia* have been isolated from various carious teeth, normal gingiva, inflamed gingival crevices, and periodontal pockets. In view of different oral manifestations, studies are required for evaluation of *Nocardia* as a potential oral pathogen.

## REFERENCES

1. Adair J C, Amber II, Johnston J.M. Peritonsillar abscess caused by *Nocardia asteroides*. *J Clin Microbiol* 1987;25(11):2214- 15.
2. Elmer K , Stephen A, William J , Paul S , Washington W. Koneman's Colour Atlas and Textbook of Diagnostic Microbiology: 5<sup>th</sup> ed. Philadelphia Lippincott Williams and Wilkins; 1997: 693-694.
3. Saubolle M A, Sussland D. Nocardiosis: Review of Clinical and laboratory Experience. *Journal of Clinical Microbiology* 2003; 41 (10):4497-501.
4. Joseph De Luca, Barry Walsh, William Robbins. *Nocardia asteroides* osteomyelitis.

- Postgraduate Medical Journal 1986; 62: 673-74.
5. Inamadar A C, Palit A. Primary cutaneous nocardiosis: A case study and review. Indian Journal of Dermatology, Venerology & Leprology 2003; 69(6): 386- 91.
  6. Naser M Kaplan Acute primary cutaneous nocardiosis in Diabetic woman: A case report. JRMS 2006; 13(1):52-60.
  7. Bhattacharyya S, Deepak Kumar, Gupta P, Banerjee G, Singh M. Subcutaneous abscess caused by *Nocardia asteroides* in a patient with pulmonary tuberculosis: case report and review of the literature. Journal of Evolution of Medical and Dental Sciences 2012; 1(6):9-13.
  8. Aghasadeghi K. Nocardiosis, a case report. Shiraz E-Medical J 2005; 6:25-30.
  9. Das S. Cutaneous nocardiosis in East Delhi - a case report. Indian J Med Sci 2001; 55(6):337-39.
  10. Menéndez R, Cordero P.J, Santos M, Gobernado M, Marco V. Pulmonary infection with *Nocardia* species: a report of 10 cases and review. Eur Respir J 1997; 10: 1542–1546.

How to cite this article: Beena, Raja R, Sandeep et. al. *Nocardia* in buccal space abscess - an oral manifestation: a case report. Int J Health Sci Res. 2014;4(3):238-241.

\*\*\*\*\*

International Journal of Health Sciences & Research (IJHSR)

**Publish your work in this journal**

The International Journal of Health Sciences & Research is a multidisciplinary indexed open access double-blind peer-reviewed international journal that publishes original research articles from all areas of health sciences and allied branches. This monthly journal is characterised by rapid publication of reviews, original research and case reports across all the fields of health sciences. The details of journal are available on its official website ([www.ijhsr.org](http://www.ijhsr.org)).

Submit your manuscript by email: [editor.ijhsr@gmail.com](mailto:editor.ijhsr@gmail.com) OR [editor.ijhsr@yahoo.com](mailto:editor.ijhsr@yahoo.com)