

Case Report

Foetal Autopsy in Hydrops Fetalis

Nagarekha Kulkarni

Professor, Department of Pathology, Vijayanagara Institute of Medical Sciences, Bellary, Karnataka, India.

Received: 15/12/2013

Revised: 15/01/2014

Accepted: 16/01/2014

ABSTRACT

Introduction: Hydrops fetalis is a condition in the fetus characterized by an abnormal collection of fluid beneath the skin, pleura, pericardium and abdomen.

Case Report: This case report presents the fetal autopsy in hydrops fetalis of 20 weeks gestation. Mother gives history of consanguineous marriage, negative for antibody screening test and viral infections.

Procedure: Foetus of 20 weeks gestation with placenta and attached umbilical cord was received in the Pathology Department. A Y shaped incision was taken. The skin was stretched as in adult autopsy. Thorax and abdomen were opened in layers. Fluid was noted in thoracic and abdomen cavity amounting to 2cc and 6cc respectively. Fluid was also noted in the subcutaneous tissue. All the organs were removed and examined histopathologically. Final impression was male foetus with 20 weeks of gestation associated with non-immune hydrops foetalis and without any congenital anomalies.

Conclusion: To conclude a post-mortem evaluation should be performed in all cases of hydrops that result in neonatal death. A combined approach of a thorough antenatal assessment and autopsy may be more likely to determine the cause of non-immune hydrops.

Key words: consanguineous, nonimmune, immune.

INTRODUCTION

Hydrops foetalis is a condition in the fetus characterized by an abnormal collection of fluid with at least two of the following:- edema (fluid beneath the skin, more than 5mm), ascites (fluid in abdomen), pleural effusion (fluid in the pleural cavity, the fluid-filled space that surrounds the lungs), pericardial effusion (fluid in the pericardial sac, covering that surrounds the heart). In addition, hydrops foetalis is frequently associated with polyhydramnios and a thickened placenta (>6cm).^[1] Hydrops foetalis is found in about 1 per 2,000 births and is categorized as immune or nonimmune hydrops. Immune hydrops

accounts for 10-20% of cases. Non-immune hydrops accounts for 80-90% of cases. In general non-immune hydrops is caused by a failure of the interstitial fluid to return into the venous system.^[2] It is typically diagnosed during ultrasound evaluation for other complaints such as polyhydramnios, size greater than dates, foetal tachycardia, decreased foetal movement, abnormal serum screening, antenatal hemorrhage.^[3] This case report presents the foetal autopsy in hydrops foetalis in a 20weeks gestation.

CASE REPORT

A 22 years old female, primigravida presented with five months amenorrhoea.

Antenatal ultrasound scan was performed which revealed intrauterine foetal demise with hydrops foetalis. She gives history of consanguineous marriage and belongs to muslim community. Her past and family history was insignificant. Vital signs were stable. Respiratory and cardiovascular systems were within normal limits. Per-abdominal examination revealed 20 weeks gestation, foetal heart sounds were absent. Ultrasound examination showed single intrauterine gestation with no cardiac activity and foetal movements. Lie was longitudinal with cephalic presentation. Placenta was post fundal with grade 2 maturity. Amniotic fluid was less.

Generalised subcutaneous edema was noted. Foetal heart rate was absent. Foetal parameters were noted and final impression was intrauterine death with hydrops foetalis. Maternal laboratory findings were within normal limits. Her blood group was “O positive” and husband’s blood group was “AB positive”. Antibody screening test was negative. Maternal serum titres for toxoplasmosis, rubella, cytomegalovirus, parvovirus, syphilis were negative. Therapeutic abortion was done and a still born foetus was delivered which was sent to the department of pathology for foetal autopsy.

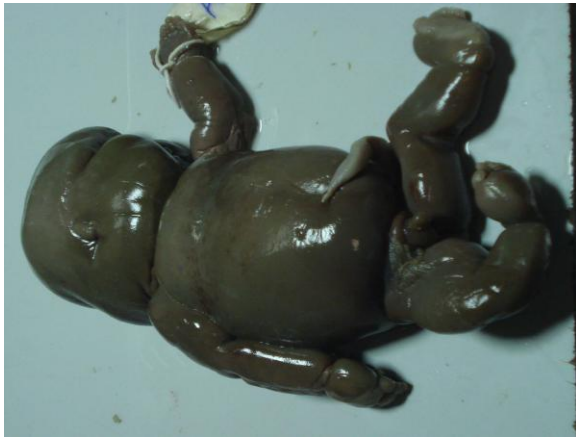

Figure-1: Shows foetus of 20 weeks gestation with edematous skin.

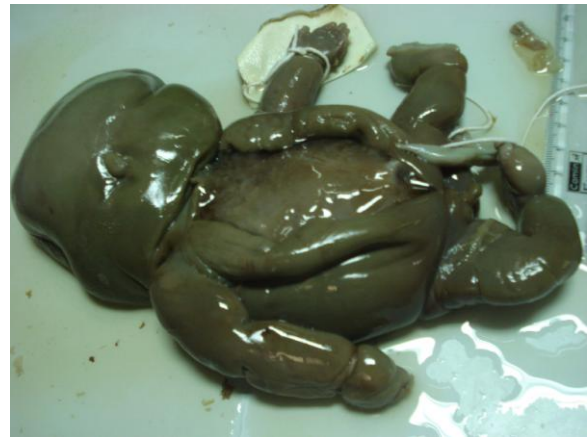

Figure-2: Shows a Y shaped incision with the skin stretched.



Figure-3: Shows thoracic and abdomen organs.

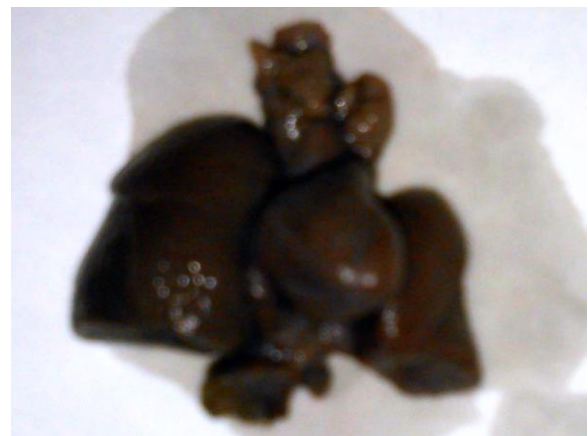

Figure-4: Shows enmass thoracic organs.

Autopsy findings: Received a foetus of 20 weeks gestation with placenta and attached umbilical cord.

External Examination of The Foetus: The whole body was oedematous (maceration-stage 0). Eye, ears, Nose and mouth seems to be underdeveloped, palate couldn't be felt, as it cannot be accessed by little finger. Digits were normal but underdeveloped. Palmar creases cannot be made out as body was oedematous.

Body weight – 410 gm

Crown heel length – 23 cm.

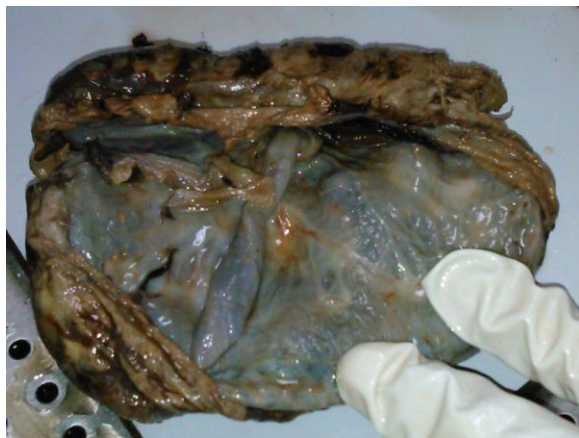

Figure-5: Shows internal surface of placenta.

<u>Organs</u>	<u>Measurement</u>	<u>Approximate weight</u>
Right sided lung	2 x 1.5 x 0.5 cm	3 gm
Left sided lung	1.4 x 1 x 0.4 cm	2.75 gm
Spleen	0.8 x 0.4 x 0.2 cm	1.5 gm
Liver	4 x 2.5 x 0.5 cm	8 gm
Each kidney with adrenals	0.6 x 0.5 x 0.2 cm	2 gm
Heart	1.5 x 0.5 x 0.4 cm	3 gm
Testis	0.3 x 0.2 x 0.1cm	0.25 gm

Internal Examination: A Y shaped incision was taken. The skin was stretched as in adult autopsy. Thorax and abdomen were opened in layers. Fluid was noted in thoracic and abdomen cavity amounting to 2cc and 6cc respectively. Fluid was also noted in the subcutaneous tissue. All the organs were removed.

Gallbladder was not developed.

Crown rump length – 15 cm.

Head circumference – 19 cm.

Biparietal diameter (BPD) - 4.5 cm.

Occipital frontal diameter – 9.5 cm.

Space between both the eyes – 1.2 cm.

Space between nose and upper lip- 0.5 cm.

Mouth was small and measuring 0.8 cm transversely.

Chin – Normal.

Humerus length (Bilateral) – 4 cm.

Femoral length (Bilateral) – 4.5 cm.

Genitalia – Male.

Anus – Noted.

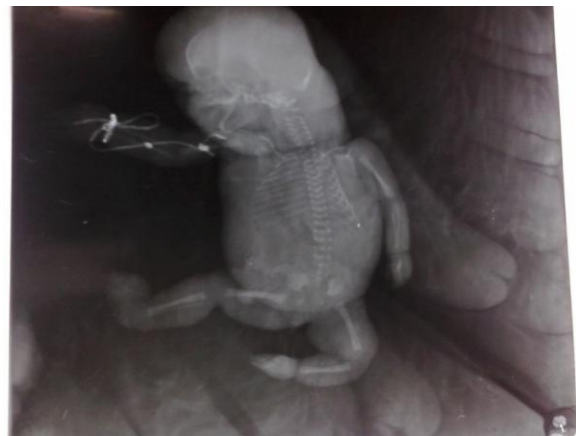


Figure-6: Shows the skeletal x-ray of foetus.

Bilateral Testis was noted at the inguinal region.

Intestine was removed from lower end of oesophagus to rectum.

Brain was not developed and was in semi-liquid state.

No congenital anomalies were noted.

Examination Of Placenta: Placenta was weighing 180gm and measuring 12 x 11 x 0.5cm. Both the maternal and fetal surface was examined and there were no abnormalities detected. Umbilical cord attached to the placenta measuring 16cm. Cut section-3 vessels were noted.

Cut section of placenta showed grey brown areas. There were no abnormalities.

One bit was given from each organ for histopathological examination.

Skeletal X-Ray: no abnormalities noted.

Microscopic Findings:

1. Section studied from lung showed developing alveoli and blood vessels. (Unremarkable)
2. Section studied from the liver, spleen, adrenals, testis showed autolytic features.
3. Section studied from both the kidneys showed abortive tubules and glomeruli. (Unremarkable)
4. Section studied from the heart, stomach, small intestine, brain, placenta and umbilical cord was unremarkable.

Final impression: A male foetus with 20 weeks of gestation associated with

Non-immune Hydrops Foetalis and without any congenital anomalies.

DISCUSSION

Hydrops fetalis is a clinical phenotype with a broad spectrum of causes. The common pathway to the phenotype follows fetal anemia, hypoproteinemia, and cardiac failure. Since the development of Rh immunoglobulin, most cases are associated with non-immune causes. Although in the majority of cases no etiology is determined, investigators have shown that with thorough investigation, an underlying cause can be identified in up to 84% of such fetuses. When hydrops fetalis is followed by intrauterine fetal death, the success rate for identifying an etiology drops to 40%.^[4] The most common causes of non-immune hydrops fetalis are cardiovascular, chromosomal and hematologic disorders. The remaining cases have less common etiologies that may be difficult to identify prenatally.^[5]

In the present case the positive findings are consanguineous marriage, fluid collection beneath the skin, thoracic cavity and abdomen with antibody screening test negative.

Consanguineous marriages have been described as an important factor contributing to increased genetic disorders and congenital malformations. The most frequent type of marriage was between first cousin. Because of high consanguinity rates within the Muslim population, the incidence of congenital malformations and genetic disorders in Islamic countries is between 10 to 45%.^[6] Increased incidence of genetic malformation in the offspring of consanguineous couples most likely arises from the homozygous expression of recessive genes inherited from their common ancestors.^[7] In the present case this may be the cause of hydrops fetalis. .

The differential diagnosis of hydrops fetalis include multiple etiologies, but the work – up and outcome are often disappointing in their yield. Families and physicians are frequently left with unanswered questions and no identifiable etiology.^[5] In the present case the fluid collection is beneath the skin, thoracic cavity and abdomen. Both husband and wife’s Rh typing is negative and antibody screening test is negative which rules out immune hydrops. Non-immune hydrops is associated with cardiac abnormalities, chromosomal/ genetic syndromes, foetal anemia, infection, thoracic abnormalities, twinning, tumors and miscellaneous.^[1] In the present case maternal serum titres for toxoplasmosis, rubella, cytomegalovirus, parvovirus, syphilis were negative. Chromosomal studies were not done in the present case which may be helpful to identify the cause.

CONCLUSION

1. Consanguinity may play an important role in the high rates of genetic disorders and malformations in children and must be taken into account for genetic counselling. For possible prevention, genetic

counselling before marriage must be applied not only for consanguineous couples but also for any couples who have family history of genetic disorders.

2. A post-mortem evaluation should be performed in all cases of hydrops that result in neonatal death. A combined approach of a thorough antenatal assessment and autopsy may be more likely to determine the cause of non-immune hydrops.
3. With an identifiable cause of hydrops foetalis, couples at risk can often undergo prenatal testing during subsequent pregnancies and appropriate counselling and treatment options can be offered.

ACKNOWLEDGEMENT

I thank the Director, Principal, Head of the Department & all staff members of Department of Pathology, VIMS, Bellary for their support & encouragement to prepare this report.

REFERENCES

1. Hydrops foetalis.
www.perinatology.com/conditions/Hydrops.htm

2. Wilkins, I. Nonimmune hydrops. In Creasy and Resnick's Maternal Fetal-Medicine Principles and Practice sixth ed. Ed Creasy R et al., 2009, Saunders. pp505-517.
3. Rodriguez MM, Chaves F, Romaguera RL, Ferrer PL, Delaguardia C, Bruce JH. Value of autopsy in nonimmune hydrops fetalis: series of 51 stillborn fetuses. *Pediatr Devel Path.* 2002; 5:365-374.
4. Bianchi DW, TM Crombleholme, ME D'Alton: *Fetology: Diagnosis and management of the fetal patient.* McGraw-Hill. 2000, pp959.
5. Yvonne Cheng, Marion S. Verp, Terri Knutel and Judith U. Hibbard. Mucopolysaccharidosis type VII as a cause of recurrent non-immune hydrops fetalis. *J.Perinat. Med.* 2003; 31:535-537.
6. Alper OM, Erengin H, Manguo AE, Bilgen T, Cetin Z, Dedeo Iu N, et al. Consanguineous marriages in the province of Antalya, Turkey. *Annales deGenetique.* 2004 Jun; 47(2):129-138.
7. Bromiker R, Glam-Baruch M, Gofin R, Hammerman C, Amitai Y. Association of parental consanguinity with congenital malformations among Arab newborns in Jerusalem. *Clin Genet* 2004.Jul; 66(1):63-66.

How to cite this article: Kulkarni N. Foetal autopsy in hydrops fetalis. *Int J Health Sci Res.* 2014;4(2):202-206.

International Journal of Health Sciences & Research (IJHSR)

Publish your work in this journal

The International Journal of Health Sciences & Research is a multidisciplinary indexed open access double-blind peer-reviewed international journal that publishes original research articles from all areas of health sciences and allied branches. This monthly journal is characterised by rapid publication of reviews, original research and case reports across all the fields of health sciences. The details of journal are available on its official website (www.ijhsr.org).

Submit your manuscript by email: editor.ijhsr@gmail.com OR editor.ijhsr@yahoo.com