



Case Report

## Adult Bochdalek Hernia- A Rare Case Presentation

Kshirsagar Ashok, Vekariya Mayank, Gupta Vaibhav, Pednekar Akshay, Nagur Basavraj, Mahna Abhishek, Patankar Ritvij

Krishna Institute of Medical Sciences, Karad, Maharashtra, India 415110.

Corresponding Author: Kshirsagar Ashok

Received: 08/10/2014

Revised: 10/11/2014

Accepted: 14/11/2014

### ABSTRACT

**Introduction:** Congenital diaphragmatic hernia is an anatomical defect of the diaphragm, which allows protrusion of abdominal viscera into the chest, causing serious pulmonary and cardiac complications. Congenital right diaphragmatic hernia of Bochdalek rarely occurs in adults. Most of them are asymptomatic. The overall prevalence of asymptomatic Bochdalek hernia in adults is 6%.

**Case Report:** A 58 year old female presented with abdominal pain and constipation. On examination bowel sounds heard in left sided chest. X-ray chest suggestive of air-fluid level in left lung field and shift of mediastinum structure to right. X-ray abdomen erect suggestive of small intestinal obstruction. Laparotomy was done and reduction of large bowel loops from diaphragmatic opening done.

**Discussion:** Bochdalek's hernia (posterolateral defect, pleuroperitoneal hernia), firstly described by Bochdalek in 1848, is a congenital posterior lateral diaphragmatic defect that allows abdominal viscera to herniate into the thorax, resulting from failed closure at 8 weeks of gestation of the pleuroperitoneal ducts, primitive communications between the pleural and abdominal cavities. Bochdalek hernia is a congenital anomaly in neonatal and postnatal patients and occurs in about one in 2,200 to 12,500 live births, but it is rare in adults.

**Conclusion:** Bochdalek hernia should be in mind while diagnosing the bowel obstruction case in adult. Surgery is the only treatment. Prompt treatment prevents complications.

**Key words:** Bochdalek hernia, diaphragmatic hernia repair, pleuroperitoneal membranes.

### INTRODUCTION

Congenital diaphragmatic hernia is an anatomical defect of the diaphragm, which allows protrusion of abdominal viscera into the chest, causing serious pulmonary and cardiac complications. It is the most common type of congenital diaphragmatic hernias and occurs in approximately 1 in 2,200–12,500 live births; they are seen with much greater frequency

on the left hemithorax and associated to a normal diaphragm. <sup>[1,2]</sup>

They can occur through an anterior parasternal foramen (Morgagni) or through a posterolateral, mainly left-sided, defect (Bochdalek). The Bochdalek hernias are the result of inadequate obliteration of the lumbar elements in the pleuroperitoneal area, during the eighth and tenth week of intrauterine development

Congenital right diaphragmatic hernia of Bochdalek rarely occurs in adults. Most of them are asymptomatic. The overall prevalence of asymptomatic BH in adults is 6%. [3]

When diagnosed in a newborn, congenital diaphragmatic hernias are frequently associated with significant respiratory distress and mortality. [4] Also, delay in the diagnosis of diaphragmatic hernias may result in increased morbidity. The clinical manifestation of symptoms and diagnosis in adults is extremely rare. Most of the hernias (80 to 90%) are found on the left side. Right-sided hernias are rarer because the right pleuroperitoneal canal closes earlier and the liver buttresses the right diaphragm. [5]

Bochdalek hernia is unexpectedly detected on chest X-rays in patients who are asymptomatic or have no specific symptoms. Chest X-ray shows gas-fluid levels in the chest and thus suggests the diagnosis of diaphragmatic hernia. Thin section CT scanning is highly accurate and should be regarded as the standard method to diagnose a Bochdalek hernia.

## CASE REPORT

Here in we present a case of 58 year old female who was presented with abdominal pain and constipation. On examination bowel sounds heard in left sided chest and resonant note from left lung obliterated. X-ray chest suggestive of air-fluid level in left lung field and shift of mediastinum structure to right (Figure-1). X-ray abdomen erect suggestive of small intestinal obstruction.(Figure-2) We performed Exploratory Laparotomy proceeds and reduction of large bowel loops from diaphragmatic opening(Figure-3) and closure of diaphragmatic defects(Figure-4) with intercostal drainage tube on left side. Post operative period was uneventful and patient discharged on 8<sup>th</sup> post operative day.

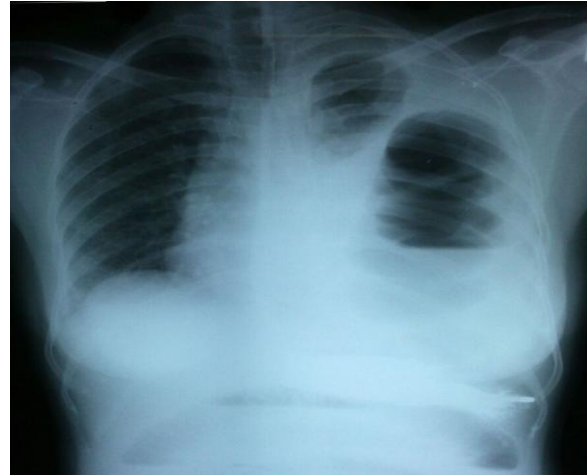


Figure 1 showing chest x ray suggestive of air fluid level on left side and shift of mediastinum to right side

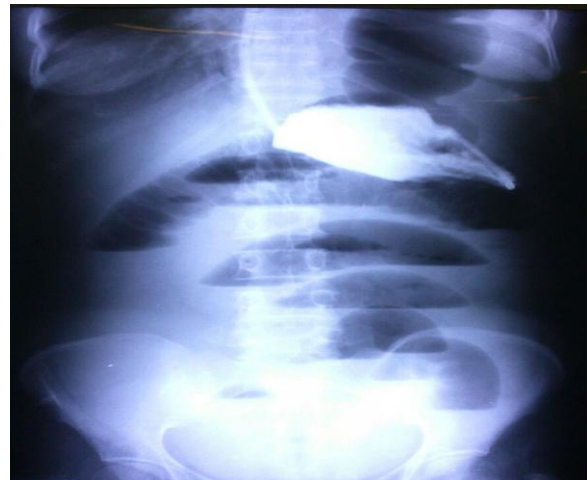

Figure 2 showing x ray abdomen erect suggestive of multiple air fluid levels suggestive of small bowel obstruction.

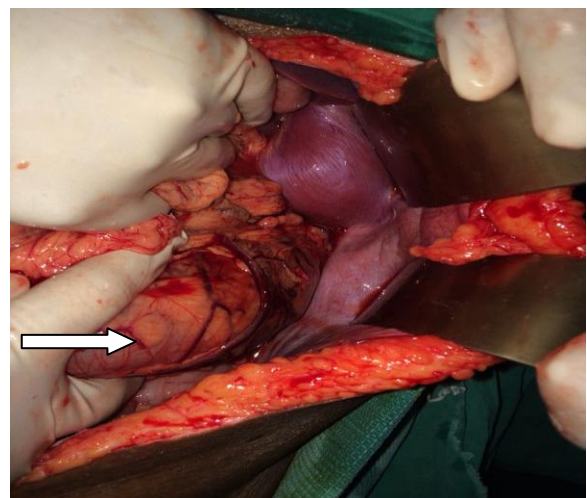


Figure 3 showing intra operative photograph of herniated transverse colon loop indicated by the arrow.

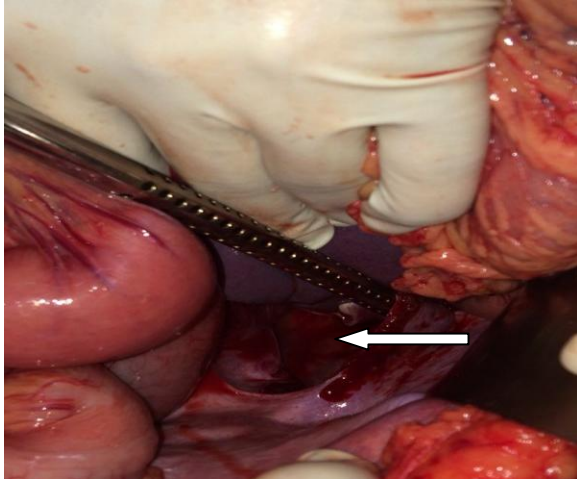


Figure 4 showing intra operative photograph of diaphragmatic defect indicated by the arrow.

## DISCUSSION

Bochdalek's hernia (posterolateral defect, pleuroperitoneal hernia), firstly described by Bochdalek in 1848, [3] is a congenital posterior lateral diaphragmatic defect that allows abdominal viscera to herniate into the thorax, resulting from failed closure at 8 weeks of gestation of the pleuroperitoneal ducts, primitive communications between the pleural and abdominal cavities. [1,6,7]

Bochdalek hernia is a congenital anomaly in neonatal and postnatal patients and occurs in about one in 2,200 to 12,500 live births, but it is rare in adults. [8]

The diaphragm derives from different sources. The central portion is formed from the septum transversum. The meso-oesophagus forms the mediodorsal portion. The musculature of the lateral body wall plus the pleuroperitoneal membranes form the lateral portions. The posterolateral portions are last to develop, and are closed by the pleuroperitoneal membranes, which grow ventrally and fuse with the septum transversum by the eighth week of embryonic life. [9,10] Cessation of closing can result in herniation of abdominal viscera into the thorax, through this opening. [9-11] Most

large defects are in the left posterolateral position. [12] Often there is no hernial sac.

Adult Bochdalek Hernias can present in two ways. They can give rise to vague, mainly gastrointestinal abdominal pain, nausea and vomiting, constipation or respiratory chest pain, dyspnea, wheezing symptoms, followed by severe attacks and episodes of incarceration with serious consequences. Characteristically, these symptoms can be intermittent, as herniated viscera can spontaneously reduce causing symptom regression. [13-16]

Herniated organs are frequently the omentum, bowel, spleen, stomach, kidney, and pancreas on the left, and part of the liver on the right. Because of the pulmonary hypoplasia due to the compression of the lungs by the adjacent hernia, these patients are frequently symptomatic at birth.

The physical examination of Bochdalek hernia in adults is typically misleading. Bochdalek hernia is unexpectedly detected on chest X-rays in patients who are asymptomatic or have no specific symptoms. Chest X-ray shows gas-fluid levels in the chest and thus suggests the diagnosis of diaphragmatic hernia. Thin section Computed Tomography scanning is highly accurate and should be regarded as the standard method to diagnose a Bochdalek hernia.

The current treatment of choice of a Bochdalek hernia is surgical repair even in asymptomatic cases because of the risk of visceral herniation and strangulation. [17]

## CONCLUSION

Bochdalek Hernia should be included in the differential diagnosis of small bowel obstruction of adult etiology list. Early and prompt treatment required for management of Bochdalek hernia to prevent complications. Surgical management is the only treatment for Bochdalek hernia.

## ACKNOWLEDGEMENT

We are thankful to Miss Rupali Salunkhe from Department of Surgery for her secretarial help.

## REFERENCES

1. J. E. Losanoff and E. R. Sauter, "Congenital posterolateral diaphragmatic hernia in an adult," *Hernia*, 2004, vol. 8, no. 1, pp. 83–85.
2. M. E. Gale, "Bochdalek hernia: prevalence and CT characteristics," *Radiology*, vol. 156, no. 2, pp. 449–452, 1985.
3. Wilkins AC, Govodes GF, Hibbeln JF. Imaging findings in adult Bochdalek hernias. *Clin Imaging* 1994; 18:224-229.
4. van den Hout L, Reiss I, Felix JF: Risk factors for chronic lung disease and mortality in newborns with congenital diaphragmatic hernia. *Neonatology* 2010, 98:370-380.
5. Kanazawa A, Yoshioka Y, Inoi O, Murase J, Kinoshita H: Acute respiratory failure caused by an incarcerated right-sided adult Bochdalek hernia: report of a case. *Surg Today* 2002, 32:812-815.
6. J. A. Haller Jr., "Professor Bochdalek and his hernia: then and now," *Progress in Pediatric Surgery*, 1986, vol. 20, pp. 252–255.
7. V. Schumpelick, G. Steinau, I. Schlüper, and A. Prescher, "Surgical embryology and anatomy of the diaphragm with surgical applications," *Surgical Clinics of North America*, 2000, vol. 80, no. 1, pp. 213–239.
8. Yamaguchi M, Kuwano H, Hashizume M, Sugio K, Sugimachi K, Hyoudou Y: Thoracoscopic treatment of Bochdalek hernia in the adult: report of a case. *Ann Thorac Cardiovasc Surg* 2002, 8:106-108.
9. Ketonen P, Mattila SP, Harjola PT, Järvinen A, Matilla T. – Congenital posterolateral diaphragmatic hernia in the adult. *Acta Chir Scand* 1975; 141: 628–632.
10. Langman J. – *Inleiding tot de Embryologie*. 8e herzienedruk. Utrecht, Bohn, Scheltema en Holkema, 1987; pp. 289–291 and 299.
11. Thomas S, Kapur B. – Adult Bochdalek hernia: clinical features, management and results of treatment. *Jap J Surg* 1991; 21(1): 114–119.
12. Sugg WL, Roper CL, Carlsson E. – Incarcerated Bochdalek hernias in the adult. *Ann Surg* 1964; 160: 847–851.
13. Ahrend TR, Thompson BW. Hernia of the foramen of Bochdalek in the adult. *Am J Surgery* 1971; 122:612-615.
14. Hines GL, Romero C. Congenital diaphragmatic hernia in the adult. *Int Surg* 1983; 68:349-351.
15. Perhoniemi V, Helminen J, Luosto R. Posterolateral diaphragmatic hernia in adults. Acute symptoms, diagnosis and treatment. *Scand J Thorac Cardiovasc Surg* 1992; 26:225-227.
16. Osebold WR, Soper RT. Congenital posterolateral diaphragmatic hernia past infancy. *Am J Surg* 1976; 131:748-754.
17. Mullins ME, Saini S. Imaging of incidental Bochdalek hernia. *Semin Ultrasound CT MR* 2005; 26:28-36.

How to cite this article: Ashok K, Mayank V, Vaibhav G et. al. Adult Bochdalek hernia- a rare case presentation. *Int J Health Sci Res.* 2014;4(12):372-375.

\*\*\*\*\*