



Original Research Article

A Study on the Foramen Transversarium in Cervical Vertebrae

Kalpana Ramachandran¹, Parvathavarthine Chetty Ravikumar², Mahima Sophia Manavalan²

¹Professor and Head, Department of Anatomy, Sri Muthukumaran Medical College and RI, Mangadu, Chennai-69.

²Assistant Professor, Department of Anatomy, Sri Muthukumaran Medical College and RI, Mangadu, Chennai-69.

Corresponding Author: Kalpana Ramachandran

Received: 17/10/2014

Revised: 13/11/2014

Accepted: 17/11/2014

ABSTRACT

Introduction: Foramen transversarium is a typical feature of cervical vertebra which exhibits variations in the size, shape and may be multiple or absent.

Aim of the study: The main objective was to study the foramen transversarium, its variations such as the duplication of foramen transversarium and to discuss its clinical importance.

Materials and Methods: This study was conducted on a total of 120 cervical vertebrae obtained from the Department of Anatomy, Sri Muthukumaran Medical College Hospital and Research Institute, Chennai.

Results: Among the 120 cervical vertebrae examined, accessory Foramen transversarium was observed in 19 vertebrae (15.8 %). Out of this, 10 vertebrae (8.3%) showed unilateral accessory foramen transversarium and 9 vertebrae (7.5 %) showed bilateral accessory foramen transversarium. Five shapes of foramen transversarium were observed and Type 1 (round) shape was the predominant shape observed in 76 vertebrae (63.3%).

Conclusion: A thorough knowledge of these variations will be helpful for radiologists and also neuro surgeons and spine surgeons operating in this region.

Key Words: Cervical vertebra, Accessory Foramen transversarium, Vertebral artery

INTRODUCTION

The characteristic feature of adult cervical vertebrae is a foramen in each transverse process, called as the foramen transversarium (FT). This unique presence of foramen transversarium differentiates cervical vertebrae from other vertebrae. The cervical transverse process is a compound structure with foramen transversarium and has ventral and dorsal bars which end laterally as the corresponding tubercles. These tubercles unite lateral to the foramen by a bar of bone called as costal (inter tubercular lamella).^[1] All the foramen

transversarium of the cervical vertebra except that of the seventh cervical vertebrae (C7) transmits vertebral artery, vertebral vein and a branch from cervico-thoracic ganglion. Foramen transversarium of C7 transmits vertebral vein.

An Accessory vertebral foramen as quoted by Sharma *et al*,^[2] is the smaller posterior part of foramen transversarium which is divided into anterior and posterior parts by a fibrous or bony bridge, the larger anterior part encloses the artery and the smaller posterior part encloses the vertebral nerve and vertebral vein. An accessory

foramen transversarium which is posterior to and smaller than the primary foramen may be commonly found in the sixth cervical vertebra and less frequently in the other vertebrae. [3]

The foramen transversarium shows variations in size, shape and may be multiple or absent. [4] The variations of foramen transversarium in size, shape can be embryological in origin or related to the course of the vertebral artery. [5] As cited by Kaya et al, the variations in the number and size of cervical foramen transversarium can lead to symptoms like headache, migraine and fainting attacks which may be due to the compression of vertebral artery. [5] A thorough knowledge of these variations in foramen transversarium are also necessary for clinicians & radiologists who are interpreting X-rays & CT scans.

Hence, the main objective was to study the foramen transversarium, its variations such as the duplication of foramen transversarium, absent foramen transversarium and types of foramen transversarium.

MATERIALS & METHODS

This study was carried out in the Department of Anatomy of Sri Muthukumaran Medical College Hospital and RI, Chennai, India. A total of about 120 cervical vertebrae C1-C7 (C1-15, C2-23, C3-27, C4-31, C5-8, C6-6, and C7-10) were used for the study. Broken and incompletes vertebrae or vertebrae with pathological changes were excluded from the study. The age and sex of the vertebrae under the study were not known.

The foramina were macroscopically analysed and the number of vertebra with unilateral or bilateral accessory Foramen transversarium was noted. The shape and direction of the main diameter the foramen transversarium were divided in to five types as per the classification given by Taitz et al

[6] (The vertebrae were studied in an A-P direction with the body of the vertebra facing the examiner). Type 1: Round, Type 2: Elliptical with main diameter (Length) antero posterior, Type 3: Elliptical with main diameter transverse (breadth), Type 4: Elliptical with main diameter oblique from right to left, Type 5: Elliptical with main diameter oblique from left to right.

The vertebrae with bilateral (Fig.1), unilateral (Fig.2) accessory foramen and the various types of foramen transversarium (fig.3) were photographed. The various types and occurrence of unilateral and bilateral accessory foramen transversarium from C1-C7 were tabulated.

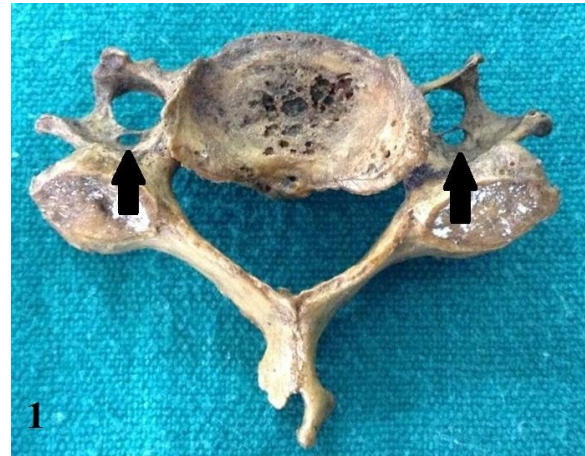

Fig.1: Typical cervical vertebra showing bilateral accessory foramen Transversarium (black arrow)

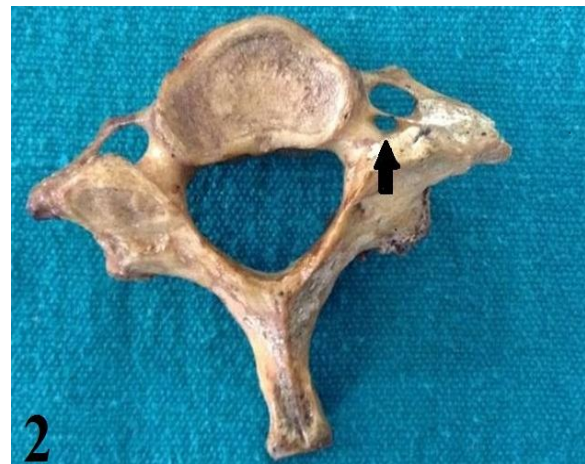

Fig.2: Atypical cervical vertebra (C7) showing unilateral accessory foramen Transversarium (black arrow)

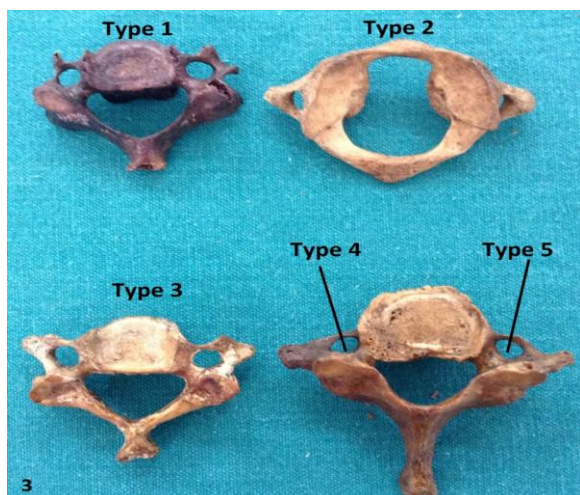


Fig.3: Various types of foramen transversarium according to shape and direction of main diameter

RESULTS

Following were the results of our study. The number of cervical vertebrae studied were 120.

I: Shape of the Foramen Transversarium:

The various shapes and the direction of the main diameter of the foramen transversarium observed in C1- C7 are given in Table 1.

It can be seen from above that out of the 120 cervical vertebrae studied, Type 1 (round) shape was the commonest shape observed in 76 (63.3%) vertebrae.

Table 1: Shape and direction of the main diameter of foramen transversarium






Shape & direction of axis	C1	C2	C3	C4	C5	C6	C7	TOTAL	Incidence %
Type 1: round 	13	20	19	13	04	03	04	76	63.3
Type 2: elliptical with main diameter antero-posterior 	2	3	01	04	01	01	0	12	10
Type 3: elliptical with main diameter transverse (breadth) 	-	-	04	10	01	0	0	15	12.5
Type 4: Elliptical with main diameter oblique from right to left 	-	-	03	03	01	01	05	13	10.9
Type 5: Elliptical with main diameter oblique from left to right. 	-	-	-	01	01	01	01	04	3.3
Total	15	23	27	31	08	06	10	120	100

Table 2: Unilateral and bilateral accessory foramen transversarium in cervical vertebra and its incidence

Type of vertebra	No of vertebra examined	Vertebra with unilateral accessory foramen transversarium	Vertebra with B/L accessory foramen transversarium	Total no of vertebra with accessory foramina	Incidence %
C1	15	-	-	0	0
C2	23	-	-	0	0
C3	27	R(1)	-	1	3.7
C4	31	R(4) L(1)	8	13	41.9
C5	8	R(1)	-	1	12.5
C6	6	R(1) L(1)	1	3	50
C7	10	R(1)	-	1	10
Total	120	10	9	19	15.8

II. Accessory foramen transversarium

The occurrence of Unilateral and bilateral accessory foramen transversarium in cervical vertebrae C1-C7 and also its incidence is summarised in Table 2.

It can be observed that, out of the 120 cervical vertebrae examined, 19 vertebrae (15.8%) had accessory foramina either unilateral or bilateral. Out of this, 10 vertebrae (8.3%) showed unilateral accessory foramen transversarium and 9

vertebrae (7.5 %) showed bilateral accessory foramen transversarium. Higher incidence of the accessory foramen was seen in C6 and C4 vertebrae.

III. Absence of foramen transversarium

In our study, all the cervical vertebrae showed foramen transversarium and none of them showed absence of foramen transversarium.

Table 3: Comparison of studies on FT by various authors

Study by	Number of vertebrae studied	Overall Incidence of Accessory transversarium %	Incidence of Unilateral Accessory foramen transversarium %	Incidence of Bilateral Accessory foramen transversarium %
Taitz <i>et al</i> ^[7]	480	7	-	-
Patil <i>et al</i> ^[7]	175	5.71	3.42	2.2
Murali Manju <i>et al</i> ^[8]	363	1.6	0.3	1.4
Chaudhari <i>et al</i> ^[9]	133	23.15	14.73	8.42
Rathnakar <i>et al</i> ^[10]	140	5.7	3.6	1.42
Kaya <i>et al</i> ^[5]	22	22.7	1.14	0.76
Karau <i>et al</i> ^[11]	102	3.9	3.9	-
Our study	120	15.8	8.3	7.5

DISCUSSION

The foramen transversarium is due to specialty in the formation of the cervical transverse process. Formation occurs because of the fusion of vestigial costal element with the body and the original transverse process of vertebra. The vertebral vessels and nerve plexuses are being caught between these bony parts. A costo transverse bar closes laterally the FT, which is a plate of bone which connects the costal element to the original transverse process. ^[6] Taitz *et al.* also reported the absence of foramen transversarium at the level of C4 and C6 vertebrae. It has been stated that an absent foramen transversarium could be due to absent vertebral artery. ^[6] In our study, we observed foramen transversarium in all the cervical vertebrae.

Many studies have been carried out on the morphometry of foramen transversarium (Table 3). In one of the study conducted by Kaya *et al.* ^[5] on 22 cervical vertebra of ancient Byzantine cervical vertebra, double foramen transversarium was found in five vertebrae (22.7%), unilateral in three and bilateral in two vertebra.

In another study of Patil *et al.* ^[7] on 175 cervical vertebrae, double foramen transversarium was found in 5.71%,

unilateral duplication in 3.42%, and bilateral in 2.28%.

In yet another study by Murali Manju *et al.* ^[8] on 363 specimens six (1.6%) showed accessory foramina, five (1.4%) showed bilateral accessory foramina and only one (0.3%) showed unilateral accessory foramina.

Taitz *et al.* ^[6] in their study of 480 cervical vertebra observed double foramen transversarium in 7% cases.

Out of 200 typical cervical vertebra studied by Sharma *et al.*, ^[3] accessory foramina were found in 16 vertebrae (8%) among vertebra between C3-C6, incidence being higher in C6 vertebra in their study.

In the present study of 120 cervical vertebrae, the incidence of accessory foramen transversarium was 15.8%. In this 8.3% vertebrae showed unilateral accessory foramen transversarium and 7.5% vertebrae showed bilateral accessory foramen transversarium. The incidence of accessory foramen transversarium was more common at the level of C6.

Table 3 is a comparison between our study and other studies.

The paired Vertebral arteries develops from the fusion of the longitudinal anastomosis that connects cervical intersegmental arteries which branch from

the primitive dorsal aorta and they secondarily lose their connection with the aorta. [12] The intersegmental arteries disappear except the seventh intersegmental artery which forms the proximal part of the subclavian artery which also includes the origin of the vertebral artery. [13] Fenestration of vertebral artery or its duplication can also lead to double foramen transversarium as in case of duplicated arteries which have two origins and their fusion points are in the neck but fenestrated vessels have single origin and divide into two parallel trunks within or outside the vertebral canal. [14]

Knowledge of the anatomy and morphology of foramen transversarium is helpful for spine surgeons and also radiologists in interpretation of X-rays of the cervical region and CT scans. The variation in the Foramen transversarium can lead to distortion of the vertebral artery and compression of the artery can lead to neurological and hearing disturbances. [9] Any variation in the foramen transversarium can lead to vertebrobasilar insufficiency due to movements of the neck. [5]

CONCLUSION

The present study observed accessory foramen transversarium in 15.8% cases. The causative factors were explained on an embryological basis. The present study shows that a thorough knowledge of these variations will be helpful to radiologists, neurosurgeons and recognition of this variation is utmost essential for spine surgeons operating in this region.

REFERENCES

1. Standring S, Ellis H, Healy JC et al. *Grays Anatomy*. 39th Edition. Elsevier. Churchill Livingstone. 2005; 743.
2. Sharma A, Singh K, Gupta V, et al. Double foramen transversarium in

- cervical vertebra. An osteological study. *J.Anat .Soc.India* 2010; 59(2): 229-231.
3. Bergman RA, Thompson SA, Afifi AK et al. *Compendium of Human Anatomic Variation*. Germany: Urban & Schwarzenberg; 1988.
4. Das Srijit, Suri R, Kapur V. Double Foramen Transversaria: An Osteological Study with Clinical Implications. *Int Med J* 2005; 12:311-313.
5. Kaya S, Yilmaz ND, Pusat S, et al. Double foramen transversarium variation in ancient Byzantine cervical vertebra : preliminary report of an anthropological study. *Turkish Neurosurgery* 2011; 21(4):534-538.
6. Taitz C, Nathan H, Arensburg B .Anatomical observations of foramina transversaria *Journal of Neurology Neurosurgery and Psychiatry* 1978; 41:170-176.
7. Patil N P, Dhapate SS, Satish P, et al. The study of incidence of accessory foramen transversaria in the cervical vertebra. *Journal of Dental and Medical Sciences* 2014; 13(1): 85-87.
8. Muralimanju BV, Prabhu LV, Shilpa K, et al. Accessory transverse foramina in the cervical spine – Incidence, Embryological basis, Morphology and Surgical importance. *Turkish Neurosurgery*. 21(3):384-387.
9. Chaudhari ML, Maheria PB, Bachuwar SP. Double foramen transversarium in cervical vertebra. Morphology and Clinical Importance *Indian Journal of Basic and Applied Medical Research* 2013; 8(2):1084-1088.
10. Rathnakar P, Remya K, Swathi B. Study of accessory foramen

- transversaria in cervical vertebrae. NUJHS 2013; 3(4):97-99.
11. Karau PB, Odula P. Some anatomical and morphometric observations in the transverse foramina of the Atlas among Kenyans. AJA 2013; 2(1):61-66.
 12. Schoenwolf GC, Bleyl SB, Brauer PR et al. Development of Vasculature. Larsen's Human embryology. 4th ed. Elsevier. Churchill Livingstone, Philadelphia. 2009; 411.
 13. Ioneta C, Omojola MF. Angiographic demonstration of bilateral duplication of the extracranial vertebral artery: unusual Course and review of literature. AJNR 2006; 27:1304-1306
 14. Mehta G, Shamkumar S, Mokhasi V. Foramina transversaria 'Bipartita'. A study of cervical vertebra. Int J Cur Res Rev 2014; 6(7) :31-34.

How to cite this article: Ramachandran K, Ravikumar PC, Manavalan MS. A study on the foramen transversarium in cervical vertebrae. Int J Health Sci Res. 2014;4(12):178-183.

International Journal of Health Sciences & Research (IJHSR)

Publish your work in this journal

The International Journal of Health Sciences & Research is a multidisciplinary indexed open access double-blind peer-reviewed international journal that publishes original research articles from all areas of health sciences and allied branches. This monthly journal is characterised by rapid publication of reviews, original research and case reports across all the fields of health sciences. The details of journal are available on its official website (www.ijhsr.org).

Submit your manuscript by email: editor.ijhsr@gmail.com OR editor.ijhsr@yahoo.com