



Original Research Article

A Computerized Tomographic Study of Normal Mediastinal Anatomy in Indian Subjects

Syed Naziya P¹, Althaf Ali S², Pritha S Bhuiyan³, Syed Imran S⁴, Anand Abkari², Murthy G S N²

¹Department of Anatomy, Deccan College of Medical Sciences, Hyderabad, Telangana, India.

²Department of Radiology, Deccan College of Medical Sciences, Hyderabad, Telangana, India.

³Department of Anatomy, Seth G S Medical College, Mumbai, Maharashtra, India.

⁴Department of Anatomy, Dr. Shankarrao Chavan Govt. Medical College, Nanded, Maharashtra, India.

Corresponding Author: Syed Naziya P

Received: 01/10/2014

Revised: 13/10/2014

Accepted: 17/10/2014

ABSTRACT

Background: The mediastinum is a complex region, containing vital structures. The details of the spatial relations of these structures can be studied with the help of cross sections at various vertebral levels. Computerised Tomography (CT) is the best way to explore this region in living subjects. The advent of minimal access surgeries like mediastinoscopy demand better knowledge of anatomy. This pioneering study will be of immense help in understanding the living anatomy of mediastinal structures especially in Indian subjects.

Aim: To study the vertebral levels of sternal angle and tracheal bifurcation and to measure the dimensions of mediastinum in Indian subjects.

Materials and Method: CT chest of 48 patients were studied and dimensions of mediastinum and vertebral levels of sternal angle and tracheal bifurcation of mediastinum were measured.

Results:

1. The vertebral level of sternal angle passed through T5 in 68.75% cases.
2. The vertebral level of tracheal bifurcation was seen at T5 in 52.08% cases and at and below T6 in 31.25% cases.
3. The average anteroposterior diameter of mediastinum was 59.69 ± 3.99 mm in males and 49.74 ± 3.2 mm in females.
4. The average transverse diameter of mediastinum was 55.62 ± 2.18 mm in males and 49.83 ± 2.94 mm in females.

Conclusion: The above comprehensive data of mediastinal dimensions will help clinicians in understanding the mediastinal anatomy for diagnostic and therapeutic purpose especially in Indian subjects.

Key Words: mediastinal dimensions, sternal angle, tracheal bifurcation, living anatomy, Indian subjects

INTRODUCTION

The mediastinum is the region of the thorax located between the two pleural sacs

bounded anteriorly by the sternum and posteriorly by the thoracic vertebral column and extending vertically from the thoracic

inlet to the diaphragm. [1] It is a complex and tightly knit package of structures vital to the life of individual as it contains the central airways, the heart and the great vessels. Other important structures located here are: esophagus, thymus, thoracic duct, vagus and phrenic nerves and lymphatics. The details of the structural relations are important and are studied with the help of cross sections.

The anatomy as seen in the cadaver doesn't always reflect accurately the situation in life because formalin fixation causes tissue hardening and shrinkage. Here comes the role of imaging techniques like CT and MRI. Ability to depict in vivo anatomy and pathology has resulted in imaging becoming a corner stone for understanding health and disease. [2]

Mediastinum is relatively inaccessible to physical examination thus imaging techniques play an important role in the evaluation of suspected mediastinal pathologies. X-ray is the first line investigation because of low radiation dose, easy accessibility and cost effectiveness but it provides only two dimensional view. [3] The mediastinum was considered to be the radiological "blind spot"- an area composed of multiplicity of structures that are hidden from X-ray view. [4] CT is capable of defining the precise anatomical details and characterizing the nature, site and the extent of mediastinal lesions. [5-7] Limitations of using CT are radiation hazard and cost concern. MRI doesn't make use of ionizing radiation and has a good soft tissue resolution but there occurs respiratory and cardiac motion artifacts. While both CT and MRI provide cross-sectional depiction of the mediastinum, CT has better spatial resolution and shorter imaging time than MRI, besides being less expensive and more widely available; thus CT remains the best imaging modality to study the mediastinum. [2,3]

Literature shows very few studies; that too in western countries about mediastinal anatomy on CT. There is no such study conducted in Indian subjects. Fewer studies on this part has added up to the inherent complexity of mediastinal anatomy; ultimately resulting in diagnostic difficulties.

Sternal angle - the forward prominence formed by the manubriosternal joint; is an important landmark in the anatomy of the thorax (Fig 1). The plane passing through this angle is called as Ludwig's plane; Mediastinal structures said to lie on the Ludwig's plane in cadaver include the bifurcation of trachea, the concavity of arch of aorta and the azygos arch. [8] The purpose of this study is to determine the vertebral level of this plane and the anteroposterior and transverse diameters of mediastinum at the level of sternal angle.

MATERIALS AND METHODS

Materials: The CT chest images using Somatom, four rows CT scanner (Siemens) of 48 patients (30 males and 18 females) investigated in a corporation and a government hospital were studied.

Criteria of Inclusion / Exclusion: Only the patients of age group 18-60 years with normal mediastinal report were included in the study. The patients with any space occupying lesion of mediastinum or any lung disease which affects mediastinal dimensions were excluded.

Method: It was a prospective study. The patient's informed consent was taken to participate in the study. Patient was put in a supine position with both arms abducted and was instructed to hold the breath in full inspiration. 5mm thin sections were taken in axial plane. The data obtained was analysed in a cranio-caudal sequence at the work station of reporting room. The vertebral level of sternal angle was identified first.

The intervertebral disc was included with the preceding vertebra. For example the disc between T4-5 was included with T4 vertebra. The sternal angle was identified by the criteria of Goodman et al. [9] The criteria states that the sections through the angle of Louis include the inferior irregular manubrial border, the upper border of the body and the intervening fibrocartilage. The bone in this area appears rhomboid or square or rectangular and is homogeneously dense without a sharp cortical rim or has irregular mottled calcifications.

The vertebral body which was cut by the scan through the sternal angle was identified by counting either upward from the fifth lumbar vertebra or downward from the first thoracic vertebra or both. The vertebral level of tracheal bifurcation (Fig 2) was noted. The dimensions of mediastinum were then measured at the level of sternal angle (Fig 3). The anteroposterior diameter was measured from the posterior surface of sternal angle to the anterior surface of thoracic vertebra or the intervertebral disc. The transverse diameter was measured as the widest possible diameter of mediastinum at the level of sternal angle. All these data were recorded as per the proforma in a master chart.

Statistical Analysis: All these measurements were statistically analyzed by calculating the Mean (\bar{X}) and Standard Deviation (SD) using software SPSS version 22.0

RESULTS

The following observations were made:

The vertebral level of sternal angle

The vertebral level of sternal angle ranged between T4 to T6. The sternal angle passed through T4 and above in 11 cases (22.91%), through the T5 in 33 cases (68.75%) and through T6 and below in only 4 cases (8.33%). Thus T5 is the commonest vertebral level of sternal angle in present study.

The vertebral level of tracheal bifurcation

The tracheal bifurcation was seen at and above T4 level in 7 cases (14.58%) and in 15 cases (31.25%) it was found at and below T6 vertebra. Majority of cases (25 cases: 52.08%) had tracheal bifurcation at T5.

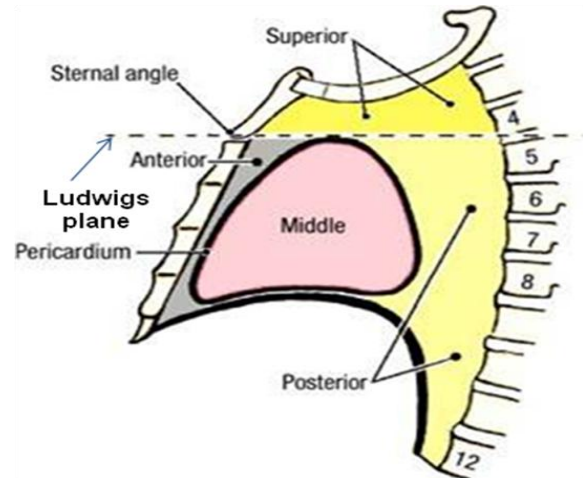


Figure 1: Schematic illustration showing divisions of mediastinum and sternal angle.

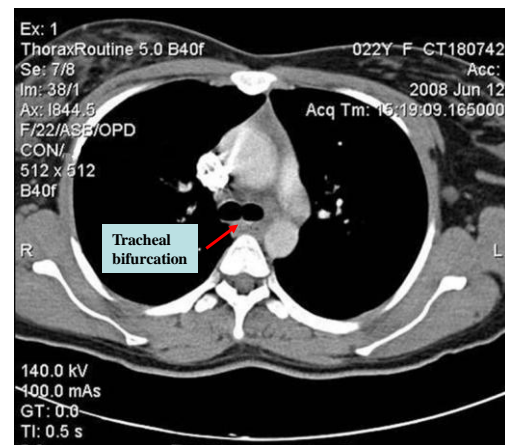


Figure 2: Illustration showing CT chest at the level of tracheal bifurcation (red arrow)

The anteroposterior diameter of mediastinum at the level of sternal angle

The anteroposterior diameter of mediastinum at the level of sternal angle ranged between 49.58 mm and 67.86 mm in males and between 45.25 mm and 56.91 mm in females. In males, the average diameter was 59.69 ± 3.99 mm; whereas in females, it was 49.74 ± 3.2 mm.

The transverse diameter of mediastinum at the level of sternal angle

The transverse diameter of mediastinum at the level of sternal angle ranged between 48.18 mm and 58.89 mm in males and between 44.98 mm and 54.64 mm in females. In males, the average diameter was 55.62 ± 2.18 mm whereas in females, it was 49.83 ± 2.94 mm.

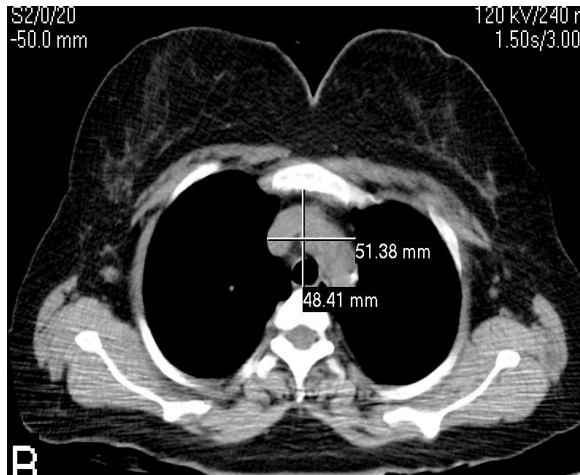


Figure 3: CT chest illustration showing anteroposterior and transverse diameter of mediastinum at the level of sternal angle in a 28 year old male subject.

DISCUSSION

The anatomy of mediastinum is exceedingly complex therefore detailed study of mediastinum is very important. As the new diagnostic modalities like CT and MRI have established their place in our diagnostic armamentarium, they have required us to be knowledgeable especially about sectional anatomy as never before. The knowledge of structural relationship of mediastinum not only has diagnostic implications but therapeutic use also. [10,11]

Chukwuemeka et al, [12] from London in their study of CT chest on 51 subjects, found that the vertebral level of sternal angle was T4 in 18.6% cases, T5 in 72.5% cases and T6 in 7.9% cases. In the present study the vertebral level of sternal angle was found to pass through T4 and above in 22.91% cases, T5 in 68.75% cases

and T6 in 8.33% cases. These values when compared indicated that the average value of the vertebral level of sternal angle found in present study was very similar to that found by Chukwuemeka et al. [10] The commonest vertebral level found in both the studies is T5, which is one vertebra lower than the classically described level of sternal angle in cadaveric dissections. It is a known fact that there is a difference in the vertebral level of various mediastinal structures between cadavers and living subjects. Thus the students and the clinicians must be aware of the changes in the vertebral level of sternal angle.

In the same study, Chukwuemeka et al, [12] reported the average vertebral level of tracheal bifurcation to be above T4 in 17.6% cases, at T5 in 41% cases and at and below T6 in 41% cases. In the present study the tracheal bifurcation was seen at and above T4 level in 14.58% cases, at T5 in 52.08% cases and at and below T6 in 31.25% cases. It was evident from our study that the commonest vertebral level of tracheal bifurcation was T5; the next common being T6. A slight difference in the percentage of vertebral level between present study and the study of Chukwuemeka et al [12] may be because of subjective variation and the ethnic differences between the study populations. The lower position of tracheal bifurcation can be explained by the fact that in deep inspiration the diaphragm lowers down and thus the mediastinal contents are found at a lower level.

Gleeson et al, [13] found that the transverse diameter is 61.3 ± 0.97 mm in their study of CT chest on 282 subjects from Ireland. In present study the average transverse diameter of mediastinum was found to be $55.62 \text{ mm} \pm 2.18 \text{ mm}$ in males and $49.83 \text{ mm} \pm 2.94 \text{ mm}$ in females and the common average was $53.45 \text{ mm} \pm 3.75 \text{ mm}$. The differences in the average transverse diameter of mediastinum between the two

studies may be due to the ethnic differences between the study populations and the subjective variation.

The studies on the anteroposterior diameter of mediastinum were not found in literature. In the present study the average anteroposterior diameter of mediastinum was 59.69 mm \pm 3.99 mm in males and 49.74 mm \pm 3.2 mm in females and the common average was 55.96 mm \pm 6.12 mm.

The dimensions of mediastinum are very important during mediastinoscopy and mediastinal surgeries. In patients with chest trauma, the upper limit of normal mediastinal width (transverse diameter) is taken as 8 cm. If the width exceeds 8 cm, mediastinal hemorrhage is suspected. [14,15]

Levels described in anatomy books and levels seen in clinical practice in living subjects are different. The data presently available is not sufficient for clear understanding of mediastinal anatomy. The present study provides quantitative data on the dimensions of mediastinum as well as the relations of various contents of mediastinum in Indian subjects.

CONCLUSION

Mediastinum is an area of intricate anatomy commonly harboring a wide variety of pathologic lesions. Despite its complexities, the mediastinum can and should be viewed as a dynamic region whose component parts can be analyzed by careful analysis of the various sections in CT imaging. The present study revealed that the sternal angle and tracheal bifurcation are usually one vertebral level below that was described in the standard text books of anatomy; in living subjects which may be explained by the deep inspiration and supine position. Further studies with larger sample size were needed to rationalize the present findings.

REFERENCES

1. Standing Susan. Gray's Anatomy: The Anatomical Basis of Clinical Practice. 40th ed. Churchill Livingstone, Elsevier Ltd. 2008; 939-941.
2. Harold Ellis, Logan BM, Dixon AK. Human Sectional Anatomy: Atlas of Body Sections, CT and MRI Images. 3rd ed. London, Hodder Arnold, 2007; viii-xiii, 106-127.
3. Lee JK, Sagel SS, Stanley RJ and Heiken JP. Computed Body Tomography with MRI correlation. 3rd ed. Volume1. Philadelphia, Lippincott-Raven Publishers.1998;1-9,202-220.
4. Heitzman ER. The Mediastinum: Radiologic Correlations with Anatomy and Pathology. 2nd ed. New York, Springer-Verlag BerlinHeidelberg. 1988;1-5.
5. John K. Crowe, Larry R. Brown, and John R. Muhm. Computed Tomography of the Mediastinum. Radiology 1978 128:1 , 75-87
6. McLoud, Theresa C. Wittenberg, Jack, Ferrucci, Joseph T. Computed Tomography of the Thorax and Standard Radiographic Evaluation of the Chest: A Comparative Study. Journal of Computer Assisted Tomography. 1979; Vol 3(2)
7. R. Gilbert Jost, Stuart S. Sagel, Robert J. Stanley, and Robert G. Levitt. Computed Tomography of the Thorax. Radiology; 1978 126:1 , 125-136
8. Bo WJ, Carr J, Kruger WA, Woleman NT and Bowden RL. Basic Atlas of Sectional Anatomy with Correlated Imaging. 4th ed.Saunders Elsevier, 2009; xiii-xv.
9. Goodman LR, Teplick SK and Kay H. Computed Tomography of Normal Sternum. American Journal of Roentgenology.1983; 41:219-223.
10. Goldwin RL, Heitzman ER and Proto AV. Computed Tomography of the Mediastinum: Normal Anatomy and Indications for the Use of CT. Radiology.1977; 124, 235-241.
11. Heitzman ER, Goldwin RL, Proto AV. Radiologic analysis of the mediastinum

- utilizing computed tomography. Radiologic Clinics of North America. 1977, 15(3):309-329.
12. Chukwuemeka A, Currie L and Ellis H. CT Anatomy of the Mediastinal Structures at the Level of the Manubriosternal Angle. Clinical Anatomy. 1997; 10:405-408.
 13. Gleeson C, Spedding R, Harding L, and Caplan M. The Mediastinum—Is it Wide? Emergency Medicine Journal. 2001; 18(3): 183–185.
 14. Wilson D, Voystock JF, Sariago J, Kerstein. Role of Computed Tomography Scan in Evaluating the Widened Mediastinum. The American Surgeon. 1994; 60(6):421-3.
 15. R L Baron, R G Levitt, S S Sagel, and R J Stanley. Computed tomography in the evaluation of mediastinal widening. Radiology 1981 138:1, 107-113.

How to cite this article: Naziya SP, Ali AS, Bhuiyan PS et. al. A computerized tomographic study of normal mediastinal anatomy in Indian subjects. Int J Health Sci Res. 2014;4(11):111-116.

International Journal of Health Sciences & Research (IJHSR)

Publish your work in this journal

The International Journal of Health Sciences & Research is a multidisciplinary indexed open access double-blind peer-reviewed international journal that publishes original research articles from all areas of health sciences and allied branches. This monthly journal is characterised by rapid publication of reviews, original research and case reports across all the fields of health sciences. The details of journal are available on its official website (www.ijhsr.org).

Submit your manuscript by email: editor.ijhsr@gmail.com OR editor.ijhsr@yahoo.com