



Original Research Article

Anatomy of Distal Biceps Tendon and Its Footprint - A Cadaveric Study

Anjali Shastry¹, Yogitha Ravindranath², Thuslima Mohamed¹, Roopa Ravindranath³

¹PG student, ²Associate Professor, ³Professor,
Department of Anatomy, St John's Medical College, Bangalore, India.

Corresponding Author: Anjali Shastry

Received: 12/06/2014

Revised: 05/07/2014

Accepted: 11/07/2014

ABSTRACT

Rupture of distal biceps tendon is common and there are very few research articles describing its anatomy. The purpose of this study was to assist surgeons with correct tendon orientation during surgical repair by mapping the footprint of the biceps tendon insertion on the radial tuberosity. Cross sectional observational study was done on twenty four embalmed cadaveric upper limbs of known gender (14 males and 10 females). Limbs were carefully dissected. Length and width was measured using digital calipers of 0.01mm accuracy. Area of footprint was measured using graph sheet. Side and gender differences were also observed. Statistical analysis was done using SPSS. The mean length, width and area of footprint of biceps tendon on bicipital tuberosity were 19.82 ± 1.44 mm, 8.97 ± 0.95 mm and 135.62 ± 12.38 mm² respectively. The mean length and width of distal biceps tendon was 61.13 ± 12.89 mm and 12.49 ± 1.75 mm respectively. There was no significant difference between right and left sides. There was significant difference in values of length of footprint between male and female cadavers. Values of present study are comparable with previous studies. There was significant difference in values of length of footprint between male and female cadavers which needs to be considered during surgical repair.

Key words: distal biceps tendon, bicipital tuberosity, footprint, tendon repair, tendon rupture, biceps brachii, cadaveric study, embalmed specimens.

INTRODUCTION

Biceps brachii muscle originates as two proximal heads that merge at the level of the deltoid tuberosity to form a single muscle belly. This muscle belly produces a single oval distal tendon that twists from a predominantly frontal plane to a sagittal plane before inserting into the posterior rough area of bicipital tuberosity on the proximal part of the radius. ⁽¹⁾ Insertion of tendon creates the so called footprint. The tendon occupies almost full length but half the width of tuberosity. ⁽²⁾ Occurrence of

distal biceps brachii tendon rupture has been reported to be 1.2 per 100,000 persons per year. ⁽³⁾ This is an injury that reportedly occurs in highly functioning middle-aged men, more so laborers; left untreated, it is associated with a significant functional and, often, financial loss. Untreated distal rupture results in chronic arm pain and weakness in flexion and forearm supination demanding a surgical correction.

The objective of the current topographic study was to measure the dimensions of the distal biceps tendon and

its footprint by dissecting the embalmed cadaveric limbs.

MATERIALS AND METHODS

Cross sectional observational study was performed on twenty four embalmed adult cadaveric upper limbs of unknown age and known sex selected from Department of Anatomy, St John's Medical College, Bangalore. Specimens which had signs of prior trauma or surgery were excluded from the study. Dissection of the distal biceps tendon was exposed in specimens by stripping off skin and subcutaneous tissue. Surrounding muscles and fascia were removed to delineate the insertion of tendon on radial tuberosity, the tendon detached from its insertion and footprint was measured for the following parameters:

1. Visible length of tendon (LT) from point of muscle fibre termination to insertion on bicipital tuberosity [Fig 4(a)].
2. Width of tendon (WT) at point of muscle fibre termination [Fig 4(b)].
3. Length (LF), width (WF) and area (A) of footprint of biceps tendon insertion [Fig 4(c,d)].

Length and width were measured using digital vernier calipers and area was measured by tracing on graph sheet.

Statistics: Statistical analysis was done using SPSS version 16. Mean and standard deviation were calculated. Side differences

were compared using paired 'T' test and gender differences using unpaired 'T' test. 'p' value ≤ 0.05 was considered significant.

RESULTS

The dimensions of bicipital tuberosity as measured directly from specimens were as follows: The mean length, width and area of footprint of biceps tendon were 19.82 ± 1.44 mm, 8.97 ± 0.95 mm and 135.62 ± 12.38 mm² respectively. The mean length and width of distal biceps tendon was 61.13 ± 12.89 mm and 12.49 ± 1.75 mm respectively. As presented in table 1, there are no significant differences in the values of these dimensions between right and left sides. However there is a significant difference in the length of footprint between male and female cadavers ($p < 0.05$, table 2).

Table-1: Mean, SD, 'p' value of the measured parameters of the right & left sides (n=24).

Parameters(n=24)	Right(n=14)	Left(n=10)	p value
LF (mm)	20.14±1.55	19.52±1.35	0.15
WF(mm)	8.98±1.04	8.97±0.908	0.94
A (mm ²)	133.5±1.21	137.75±1.28	0.062
LT(mm)	61.23±1.28	61.06±1.35	0.72
WT(mm)	12.53±1.72	12.46±1.89	0.49

Table- 2: Mean, SD, 'p' value of the measured parameters of the male and female cadavers (n=24).

Parameters(n=24)	Male(n= 14)	Female (n=10)	p value
LF (mm)	20.54±0.94	18.86±1.61	0.039*
WF (mm)	9.26±0.86	8.51±1.06	0.45
AF (mm ²)	139.43±10.01	130.52±15.45	0.058
LT (mm)	58.05±13.09	65.43±12.05	0.42
WT (mm)	13.65±1.79	11.65±1.65	0.112

*significant (<0.05)

Table -3: Comparison of footprint measurements with previous studies.

Author/year/ population	Method	LF(mm)	WF(mm)	A(mm ²)
Forthman et al. ⁽⁷⁾	Computer tomography	22	7	-
Athwal et al. ⁽²⁾	Embalmed cadavers	21	7	108
Hutchinson et al. ⁽⁹⁾	Cadavers	18.7	3.7	-
Cho et al. ⁽⁶⁾	Embalmed cadavers	20.5	9.7	156.3
Mazzocca et al. ⁽⁸⁾	Fresh frozen cadavers	14	2	-
Present study	Embalmed cadavers	19.82	8.97	135.62

Table- 4: Comparison of tendon measurements with previous studies.

Author/year/population	LT(mm)	WT(mm)
Cucca et al. ⁽¹⁰⁾	57	15
Present study	61.13	12.49

DISCUSSION

Reestablishment of flexion and supination strength is one of the major goal of distal biceps tendon repair. ⁽⁴⁾ The supination torque of the biceps is related to

its insertion site on the radial tuberosity. (5) Contemporary anatomic descriptions of the biceps brachii muscle offer only a generalized description of the distal biceps brachii tendon, bicipital aponeurosis, and insertion of the tendon at the radial tuberosity. The radial tuberosity and distal biceps insertion footprint are important structures affecting forearm supination mechanics, and an anatomic repair of a ruptured tendon is important for restoration of power, endurance, and terminal forearm rotation. (5)

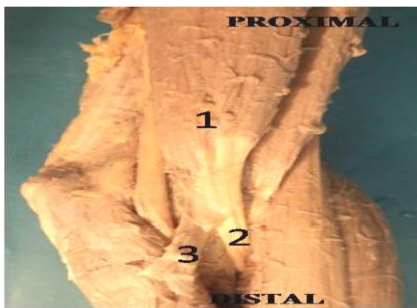

Figure 1: Skin and subcutaneous tissue has been stripped off to show biceps brachii muscle and its distal tendon. 1-Biceps brachii, 2-biceps tendon, 3-lacertus fibrosis.

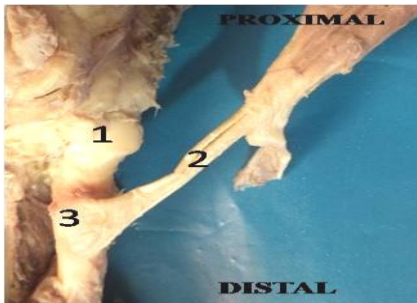


Figure 2: Surrounding muscles are removed to show insertion of tendon on radial tuberosity. 1 - Head of radius, 2 - biceps tendon, 3 - Radial tuberosity.

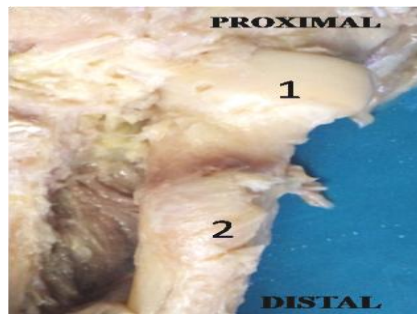


Figure 3: Distal tendon was detached from its point of insertion and footprint was exposed. 1-head of radius, 2-footprint.

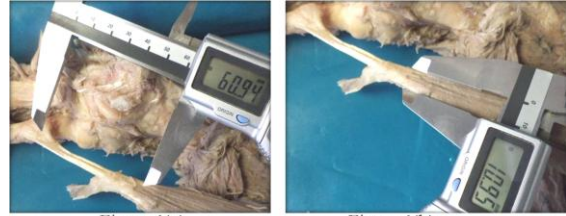

Figure 4(a)

Figure 4(b)

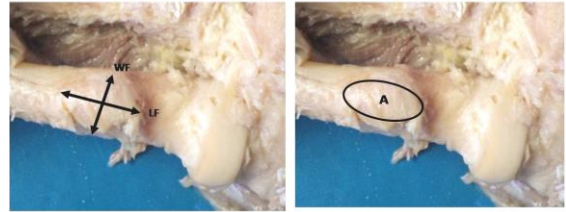

Figure 4(c)

Figure 4(d)

Figure 4 (a): Length of the tendon (LT).

Figure 4 (b): width of the tendon (WT).

Figure 4 (c): Length and width of the foot print (LF &WF).

Figure 4 (d): Area of the foot print (A).

Athwal et al. (2) reported a study on 15 fresh frozen cadavers with average length, width and area of footprint being 21mm, 7mm and 108mm² respectively. Cho et al. (6) dissected 25 embalmed cadaveric specimens and concluded that average length, width and area of footprint was 20.5 mm, 9.7mm and 156.3mm² respectively, with the footprint area occupying approximately 35.9% of the area of the radial tuberosity. Also the distal biceps tendon was reported to be inserted on the posterior rim of the radial tuberosity, with semilunar configuration, and concavity of the anterior surface of the footprint noted on the radial tuberosity.

The area of insertion of long and short head of biceps tendon was reported separately by Athwal et al. (2) and Cho et al. (6) The short head of the distal biceps tendon was inserted more anteriorly than the long head on the radial tuberosity.

Forthman et al. (7) evaluated insertional anatomy of 30 cadaveric radii using computer axial tomography. They concluded that length and width of footprint was 22mm and 7mm respectively. Present study is in concordance with the imaging study by Forthman et al., (2008).

Mazzocca et al. ⁽⁸⁾ described distal biceps insertion in 18 fresh frozen cadaver elbows and reported a mean length of 14mm and mean width of 2mm. Similarly Hutchinson et al. (2008) measured distal biceps tendon footprint in 20 cadaveric elbows. Mean length and width of footprint was 18.7mm and 3.7mm respectively.

Only two previous studies reported gender related differences. In study done by Athwal et al. ⁽²⁾ width, length and area of footprint in male cadavers were 22mm, 8mm and 112mm² respectively and in female cadavers were 20mm, 7mm and 104mm² respectively. In study done by Cho et al. ⁽⁶⁾ width, length and area of footprint in male cadavers were 20.6mm, 10mm and 163mm² respectively and in female cadavers were 20.4mm, 9.4mm and 146.7mm² respectively. Above studies have however not reported the significant difference between genders.

Values of previous studies (Table 3) are comparable with our present study except that of study by Mazzocca et al. ⁽²⁾ and Hutchinson et al. ⁽⁹⁾ In the study done by Mazzocca et al. ⁽⁸⁾ width and length of footprint are lesser than the present study. In study done by Hutchinson et al. ⁽⁹⁾ width of footprint is lesser than present study. The difference in values may be due to methodology, racial differences, occupation and handedness of individual. Recognized risk factors like male gender, smoking, anabolic steroid use and body building/weight lifting may also be the contributory factors for the differences observed.

The mean length and width of distal biceps tendon was 61.13 ± 12.89mm and 12.49 ± 1.75mm respectively. Cucca et al. ⁽¹⁰⁾ study on 20 embalmed cadaveric specimens concluded that length and width of tendon were 57mm and 15mm respectively (Table 4). The authors opine that recent research will aid in developing

better surgical repair procedures and postoperative results.

To the best of our knowledge there are no reported literatures available on side related differences. In the present study comparisons was done on measurements between right and left sides to observe any differences so that this can be taken into account before surgery (table 1). Since in our study there are no statistical significant side differences in measurements of all parameters, it is plausible that surgical repair of the traumatized limb can be reconstructed with the measurements of the non-traumatized limb.

We also compared measurements in male and female cadavers (table 2) to observe for any gender differences. Significant difference was found in length of footprint (p <0.05) which may be of crucial importance in surgical repair.

Knowledge of footprint measurements could assist in correct suture anchor and bone trough replacement as also familiarity with tendon measurements may help in performing supplemental soft tissue tendon grafts for restoration of length to the retracted and scarred biceps tendon.

CONCLUSION

The dissections performed for our study allowed us to conclude that no significant side differences were present leading to the premise that the normal side MRI will help in reconstruction of traumatized side. There was significant difference in values of length of footprint between male and female cadavers. This parameter should be considered before doing surgical repair of biceps tendon to get good postoperative results.

ACKNOWLEDGEMENTS

We would like to thank teaching and non teaching staff of Department of Anatomy, St John's Medical College, Bangalore.

REFERENCES

1. Standring S, ed. Gray's Anatomy. 40th Ed., New York, Churchill Livingstone. 2008; p.825-826.
2. Athwal GS, Steinmann SP, Rispoli D M. 2007.The distal biceps tendon: footprint and relevant clinical anatomy. *Hand Surg Am.* 32:1225-9.
3. Safran MR, Graham SM. 2002.Distal biceps tendon ruptures: incidence, demographics, and the effect of smoking. *Clin Orthop Relat Res.* 404:275–83.
4. Charles MJ, Jobin CM, Kippe MA, Gardner TR, Levine WN, Ahmad CS. 2009.Distal biceps tendon repair: a cadaveric analysis of suture anchor and interference screw restoration of the anatomic footprint. *Am J Sports Med.* 37:2214–2221.
5. Henry J, Feinblatt J, Kaeding CC, Latshaw J, Litsky A, Sibel R, Stephens JA, Jones GL . 2007.Biomechanical analysis of distal biceps tendon repair methods. *Am J Sports Med.*35:1950–1954.
6. Cho CH, Song KS, Choi IJ, Kim DK, Lee JH, Kim HT, Moon YS. 2011.Insertional anatomy and clinical relevance of the distal biceps tendon. *Knee Surg Sports Traumatol Arthrosc.*19:1930-5.
7. orthman CL, Zimmerman RM, Sullivan MJ, Gabel GT. 2008. Cross-sectional anatomy of the bicipital tuberosity and biceps brachii tendon insertion: relevance to anatomic tendon repair. *J Shoulder Elbow Surg.* 17:522-6.
8. Mazzocca AD, Cohen M, Berkson E, Nicholson G, Carofino BC, Arciero R. 2007. The Anatomy of the bicipital tuberosity and distal biceps tendon. *J Shoulder Elbow Surg* .16: 122-127.
9. Hutchinson HL, Gloystein D, Gillespie M. 2008. Distal biceps tendon insertion: an anatomic study. *J Should Elbow Surg* .17:342–346.
10. Cucca YY, Mclay SV, Okamoto T, Ecker J .2010.The bicepsbrachii muscle and its distal insertion: observations of surgical and evolutionary relevance. *Surg Radiol Anat.*32:371-5.

How to cite this article: Shastry A, Ravindranath Y, Mohamed T et. al. Anatomy of distal biceps tendon and its footprint - a cadaveric study. *Int J Health Sci Res.* 2014;4(11):92-96.

International Journal of Health Sciences & Research (IJHSR)

Publish your work in this journal

The International Journal of Health Sciences & Research is a multidisciplinary indexed open access double-blind peer-reviewed international journal that publishes original research articles from all areas of health sciences and allied branches. This monthly journal is characterised by rapid publication of reviews, original research and case reports across all the fields of health sciences. The details of journal are available on its official website (www.ijhsr.org).

Submit your manuscript by email: editor.ijhsr@gmail.com OR editor.ijhsr@yahoo.com