

*Case Report***Placenta Increta in a Ruptured Rudimentary Horn Pregnancy - A Rare Case**Subrata Pal^{1*}, Srabani Chakrabarti², Sanjay Sengupta², Biplab Kr Biswas²¹Post Graduate Trainee, ²Associate Professor
Dept of Pathology, B S Medical College, Bankura, West Bengal, India.

*Correspondence Email: subratapal1985@gmail.com

*Received: 27/04/2013**Revised: 28/05/2013**Accepted: 31/05/2013***ABSTRACT**

Pregnancy in a rudimentary horn of uterus is very rare finding and placenta increta in a case of rudimentary horn pregnancy is much rarer occurrence. We are presenting a case of ruptured rudimentary horn pregnancy presented as an acute abdominal emergency, treated by laparotomy. Uterine horn with adhered placenta was resected out and sent for histological examination. On histological examination trophoblastic tissues were deeply infiltrated in the myometrium and intervening decidual layer was absent. Final histological report of placenta increta in a rudimentary horn was done. In conclusion, prompt diagnosis and operative management can avoid catastrophe in a case of rupture rudimentary horn pregnancy with placenta increta.

Key words: Rudimentary uterine horn, rupture of pregnant uterine horn, placenta increta.

INTRODUCTION

Pregnancy in rudimentary horn of uterus has been infrequently reported. [1, 2] Documented incidence of rudimentary horn pregnancy varies from 1:76000 to 1:140,000 pregnancies. [3] But majority of these pregnancies (80%- 90%) usually cause rupture of rudimentary horns during 10th to 20th weeks of gestation resulting fatal haemorrhage. [3] Placenta increta in rudimentary horn is very rare complication of pregnancy. Till now only few cases are reported in world literature. [1, 2, 9] Except few reported cases, most of the pregnancies resulted in uterine rupture leading to massive bleeding with serious morbidity and mortality in young females. However early diagnosis with termination of pregnancy by

resection of the rudimentary horn and proper resuscitation can avoid serious and potential catastrophes associated with ruptured rudimentary uterine horn pregnancy complicated with placenta increta. [1, 3]

CASE REPORT

A 27 year old primigravida mother admitted in our obstetrics emergency with severe abdominal pain and severe anaemia during 16th week of pregnancy. She was not a booked case of our institution and was not assessed by ultrasound yet. On clinical examination foetal heart sound was absent, blood pressure was 100/64 mm of Hg and severely anaemic. Following resuscitation patient was urgently sent for emergency laparotomy. On laparotomy she had massive

intra-peritoneal bleeding (approximately 1500ml), ruptured rudimentary horn of uterus and products were in peritoneal cavity. During laparotomy placenta could not be out due to its adherence at myometrium of the rudimentary horn. The rudimentary horn with the adhered placenta was excised out and sent for histological evaluation. Patient was transfused four units of whole blood and post operative management done in critical care unit. She responded well with post operative management.

On gross examination it was a 6x4x3 cm³ mass covered by peritoneum on its anterior and post aspect. There was a rupture area at fundus of the horn and placental tissue had been invaded deeply in myometrium (Image 1). Multiple serial sections examined from different parts of the specimen. Trophoblastic tissues were invaded deep in the myometrium and the intervening decidual layer was absent (Image2, 3). But placental tissue had not encroached to serosa at any place. Final histopathological report of placenta increta in rudimentary horn was done.

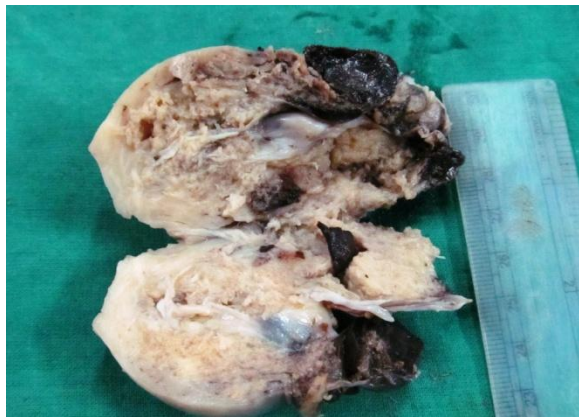


Image 1- Gross picture of ruptured uterus with adherent placenta.

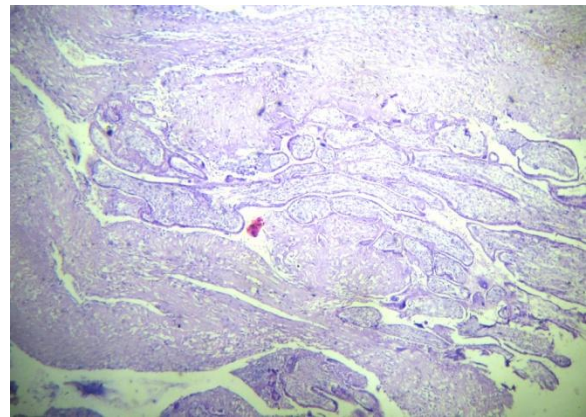


Image 2- Microscopy shows invasion of villi into myometrium without intervening decidual tissue (H & E stain- scanner view).

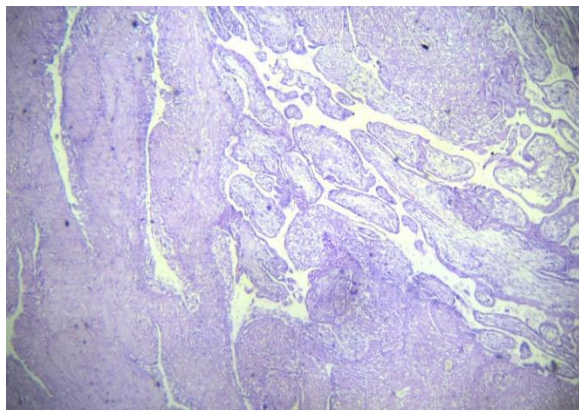


Image 3- Microscopy shows invasion of villi deep in myometrium without intervening decidual layer (H & E stain- low power view).

DISCUSSION

Partial development of contra lateral mullerian duct of a unicornuate uterus leads

to formation of rudimentary uterine horn. According to American Fertility Society classification of mullerian anomalies it is a class II anomaly.^[4] Pregnancy in rudimentary horn is an extremely rare clinical condition. Theory of intraperitoneal transmigration of spermatozoon (by Nahun et al) or fertilized ovum explains the causation of rudimentary horn pregnancy.^[10] Whatever may be the mechanism, pregnancy in a rudimentary horn is associated with high chance of spontaneous abortion or rupture of the uterine horn if pregnancy progresses. Pregnancy in rudimentary horn usually ruptures at 2nd trimester causing massive peritoneal haemorrhage and serious maternal mortality & morbidity.^[5] In

previous literature, only few cases had been diagnosed pre-operatively as unruptured rudimentary horn pregnancy. [6] Diagnosis of rudimentary horn pregnancy is possible by MRI or strong ultrasound in earlier weeks of gestation but ultrasound has significant false evaluation as ectopic, corneal or isthmic pregnancy. [9]

Placenta increta is thought to be due to lack of decidual response in endometrium and variable degree of myometrial penetration by chorionic villi. Oral et al [4] had shown that estimated prevalence of placenta accreta in rudimentary horn pregnancy might be more than 10%. Unlike placenta increta in uterine pregnancy, prior cesarean section, manual removal of placenta and myomectomy could not explain the causation of placenta increta in rudimentary uterine horn pregnancy. It may be due to improper development of relatively weak myometrium which lacks in decidual reaction. Rupture of rudimentary horn pregnancy can be explained by its weak and thin musculature and improper ability for distension during progression of pregnancy. [6,8] In uterine pregnancy placenta increta can be diagnosed prenatally by MRI & Doppler ultrasound but ultrasound has significant false negativity. [7] But in case of placenta increta in rudimentary uterine horn pregnancy it is very difficult to diagnose by ultrasound and only possible mean is MRI. [7]

CONCLUSION

However most of the previous literatures suggest immediate elective surgery in a case of rudimentary horn pregnancy even it is unruptured to avoid life threatening haemorrhage. Urgent resuscitation & laparotomy are recommended for a ruptured rudimentary uterine horn pregnancy to avoid catastrophe as it is serious and potentially fatal.

REFERENCES

1. Oral B, Guney M, Ozsoy M, Sonal S. Placenta accreta associated with a ruptured pregnant rudimentary uterine horn. Case report and review of literature. Arch Gynecol Obstet 2001;265(2):100-2.
2. Jerbi M, Trimech A, Choukou A, et al. Rupture of rudimentary horn pregnancy at 18th week gestation: a case report. Gynecol Obslet Fertil 2005;33(7-8):505-50.
3. Nahum GG. Rudimentary uterine horn pregnancy. The 20th century world wide experience of 588 cases. Reprod Med 2002;47:151-63.
4. American Fertility Society (1988) The American Fertility Society Classification of adnexal adhesions, distal tubal occlusion, tubal occlusion secondary to tubal ligation, tubal pregnancies, mullerian anomalies and intrauterine adhesions. Fertil Steril 49: 944-955.
5. Fedele L, Bianchi S, Zanconato G, Berlanda N, Bargamini V. Laparoscopic removal of the cavitated noncommunicating rudimentary uterine horn: surgical aspects in 10cases. Fertil Steril 2005;83(2):432-43.
6. Lu Jihong, Anthony Siow, Bernard Chern. Laparoscopic excision of rudimentary horn pregnancy in a patient with previous caesarean section. Arch Gynecol Obstet 2009;279: 403-5.
7. Finberg HJ, Williams JW. Placenta accreta: prospective sonographic diagnosis in patients with placenta previa and prior cesarean section. J Ultrasound Med 1992;11:333-43.
8. Murat S, Salih Taskin, Cem A, Mete G, Cihat U. Laparoscopic management of rudimentary uterine horn pregnancy: case report and

- literature review. Journal of the Society of Laparoscopic Surgeons 2006;10:396-9.
9. E Henriot, Horace R, Joel Z, Bernard L, J C Sabourin, Marpeau L. Pregnant noncommunicating rudimentary uterine horn with placenta percreta. Journal of the Society of Laparoscopic Surgeons 2008;12:101-3.
10. Nahum GG, Stanislaw H, McMahon C. Preventing ectopic pregnancies: how often dose transperitoneal transmigration of sperm occurs in affecting human pregnancy? BJOG 2004;111(7):706-14.

How to cite this article: Pal S, Chakrabarti S, Sengupta S et. al. Placenta increta in a ruptured rudimentary horn pregnancy - a rare case. Int J Health Sci Res. 2013;3(6):102-105.
