



Case Report

Symptomatic Capillary Hemangioma in Pregnancy: A Rare Case Report of Complete Recovery of Paraparesis with Review of Literature

H.G Ravikiran^{1*}, R Puranik Harish², Mukartihal Ravikumar², Naik Sandeep², R.G Roopesh³, Rahul K Patil⁴

¹Asst. Professor, Dept. of Orthopaedics, JSS Medical College, Mysore, & Consultant, Sparsh Hospital, Bangalore.

²Consultant Orthopaedic Surgeon, Sparsh Hospital, Bangalore.

³Junior Consultant Orthopaedics Surgeon, Sparsh Hospital, Bangalore, & Assistant Professor, Rajarajeshwari Medical College, Bangalore.

⁴Consultant Plastic Surgeon, Sparsh Hospital, Bangalore.

*Correspondence Email: ravikiranhg@gmail.com

Received: 03/09//2013

Revised: 11/10/2013

Accepted: 22/10/2013

ABSTRACT

Background: Hemangiomas are the commonest benign tumors to be encountered in the vertebra with a reported incidence of 10-27%. Pregnancy even though has been known to be an important risk factor for progression of these lesions (often symptomatic), very few of them (less than 30) have been reported in literature. The management of which still remains controversial.

Case Description: A 30 years old women in the 26th week of gestation presented with acute onset of upper back pain and progressive paraparesis. Imaging studies correlated with a large hemangioma at T-9 which involved the body, pedicles and the transverse process with extradural extension of the soft tissue component. In view of the precious pregnancy she was kept under observation till the completion of 32 weeks of gestation at which an elective cesarean section was completed and the patient was taken up for decompression and fusion with instrumentation after prior embolization of the lesion at the 1st week postpartum. The patient gradually recovered from the neurological deficits. At the last follow-up, 2 years from the surgery the patient continues to remain symptom free with full neurological recovery.

Conclusion: The management of symptomatic vertebral hemangiomas in pregnancy continues to be a matter of debate. Based on review of literature and our case report, the accepted norm of delaying the surgical management till the fetus achieves a viable status can still be adopted with good results.

Key words: vertebral hemangioma, pregnancy related hemangiomas, postpartum surgery hemangioma.

INTRODUCTION

Vertebral hemangiomas are common benign tumors seen in almost 10%-11% of spines at autopsy.^[1] They are often asymptomatic lesions,^[2,3] but some of them show aggressive characteristic and cause para-paresis /paraplegia with compression of

the spinal cord.^[4-7] Pregnancy has been a well recognized condition during which vertebral hemangiomas may become clinically significant. Management of these symptomatic hemangiomas still remains controversial. A review of literature suggested that fewer than 26 cases have

been reported so far. [8-11] Postpartum management of these cases continues to remain a challenge. [11]

This report describes a rare case of vertebral hemangioma that was treated by a single stage surgical procedure in the postpartum period. Patient recovered from her symptoms (paraparesis) completely.

CASE REPORT

A 25 year old lady presented at 26 weeks of gestation of her first pregnancy with complaints of pain in the back and loss of balance during gait with slowly progressive weakness in both the lower limbs. She was able to get up and stand independently but was able to walk only with support. She had no history of constitutional symptoms or involvement of bowel and bladder at the time of presentation.

On examination, she had tenderness in the upper back around the T2- T6 vertebra. There was no evidence of spinal deformity. Higher mental functions and cranial nerves were normal. There was spasticity in both the lower limbs and power in the hip knee and ankle was 3/5. Knee jerk was exaggerated bilaterally with ankle clonus and a positive Babinski sign. Abdominal reflexes were absent. Sensory loss was patchy and diffuse. Examination of the upper limb was normal. Abdominal examination showed a single live fetus corresponding to 26 weeks of gestational age.

Rest of the general and physical examination was normal.

Imaging Studies:

X rays: showed presence of an expansile lytic lesion at the T2 vertebra with extension into pedicles with possible canal compromise without noticeable collapse.

MRI: Showed abnormal signal intensity lesions involving vertebral bodies of T2,T4 T9,T12,L1,L3, and S1.The mass was seen

extending into the epidural space compressing and displacing the cord at T1 and T2. Multiple foci of hypointensity in the lesion giving a polka dot appearance. These features were suggestive of multiple hemangioma of the thoracic and lumbar vertebra with epidural soft tissue mass at T1-T2. (Fig 1A and B)

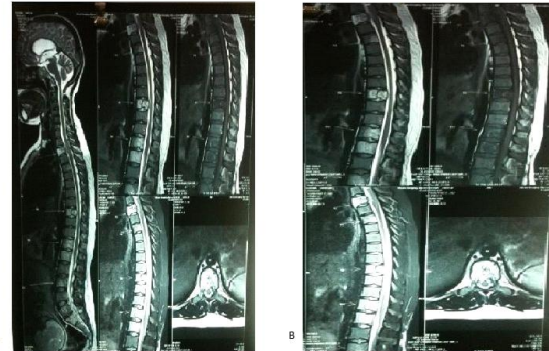

Fig 1.A and B. MRI showing features suggestive of multiple vertebral hemangiomas

Ultrasound scan of the abdomen showed that fetus was normal for the gestational age.

Following the investigations, in view of the fact that it was a precious (primi) pregnancy and the patient was very keen on continuing the pregnancy. They were explained about the condition and the natural history of the disease. With their consent it was planned to continue the pregnancy and keep the patient on observation at least till the fetus achieves the age of viability. With the next follow up four weeks later it was noticed that the patient's condition had worsened with progression of the neurologic deficit to total paraplegia of both lower limbs. Fortunately her bowel and bladder was normal. The patient was bedridden with near complete loss of sensations in the lower limbs.

With the fetal viability two weeks away it was planned to wait till 32 weeks before scheduling a single stage decompression and fixation even with

progression of neurologic symptoms which was also consented by the patient. At 32 weeks with total paraplegia the patient underwent an elective caesarian section under general anesthesia she delivered a healthy male baby weighing 3 kg which cried immediately after birth.

After her general condition improved on the fourth day after c-section she was evaluated again clinically and radiologically which revealed that her condition was status quo. She was prepared for the surgery with transarterial embolization of T2 vertebral body hemangioma and operated by corpectomy of the T2 vertebra and stabilization with iliac bone grafting and fixation with anterior cervical plate, performed through the anterior approach with a clavicular osteotomy. Intraoperative findings confirmed the hemangioma. No significant difficulties were encountered during the procedure. The immediate postoperative period was smooth and the patient general condition was stable. (Fig 2).

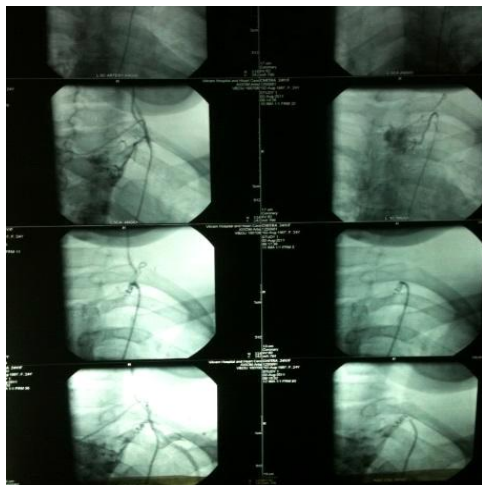


Fig 2: Arterial Embolization.

The patient started showing neurological recovery from the immediate postoperative period with full neurological recovery at 8 weeks post surgery. At the last follow-up 24 months since the surgery the patient is totally asymptomatic with no

residual neurological deficits. [Fig 3A and B].

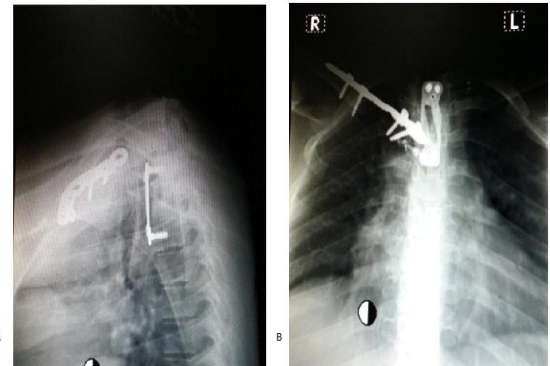


Fig 3. A and B: Post-op. x-ray at 24 months post surgery.

DISCUSSION

Hemangiomas though first described by Virchow(1867) [12] its effects in pregnancy has been ascribed to Baldoa(1926). [13] Hemangiomas are slowly growing benign vascular neoplasms derived from the endothelium of vessels. Subtypes include those with an increase of capillaries (capillary hemangioma) and those associated with an enlargement of blood channels (cavernous hemangiomas) as well as those of mixed type.

Hormone regulation and hemodynamic factors are considered to be the leading factors in the lesion's rapid growth during pregnancy. Enlarging third trimester uterus increases the local pressure in the para-vertebral veins by compressing the inferior venacava. In addition, increased venous distension and vascular growth, thought to be mediated by the systemic influence of progesterone and estrogen respectively, might further increase local venous pressure. These two mechanisms appear to act in synergy on the lesion's close environment, adding to the probability of a compression effect on adjacent neural structures. Symptomatic conversion leading to neurological compromise is believed to be due to several pathologies. Direct vascular expansion that originates from the vertebral

elements, mainly the vertebral body is the most common mechanism. Other mechanisms, such as an enlarging extradural mass (e.g. bleeding) pathologic fractures and spinal ischemia caused by steal phenomena are also implicated in the pathology. [14-17] Immunohistochemical analysis done on vertebral hemangiomas has not been able to demonstrate estrogen and progesterone receptors on tumor tissue and this implicates a hemodynamic rather than a hormonal cause for disease progression. [17,18]

Chi et. al. [19] in his review had concluded that of 23 cases of symptomatic hemangiomas in available literature prepartum surgery was performed in seven patients, postpartum surgery in twelve, and no surgery in four. Among patients treated surgically before childbirth, four experienced preterm labour. Prepartum surgery was also associated with two maternal deaths and two fetal deaths. Among patients treated surgically after childbirth, two improved following delivery, two experienced transient improvement followed by decline and persistent deficit, and five deteriorated or had persistent deficits after delivery. However his case as well as other cases done in the recent times has had better outcomes with antepartum surgery also but with significant risk of complications to the fetus. [11]

Despite the accumulating data on the management of these cases there is still a lack of any level 1 study that could substantially support any particular modality of treatment and the timing of surgery. In terms of modalities of treatment; embolization, surgical decompression, radiotherapy and vertebroplasty have been regarded as having a role in the management of vertebral hemangiomas. Radiotherapy in the context of pregnancy has not had much of a role to play in the antepartum or postpartum period. Embolization and vertebroplasty have had important role to

play both as independent treatment options and as an adjunct with surgical treatment. But surgical decompression especially in a patient with progressive neurological deficits remains the gold standard for treatment of vertebral hemangiomas in pregnancy.

More importantly the timing of the surgery continues to be a matter of debate. The most comprehensive evidence based suggestion from Chi et. al. [19] has suggested an algorithm for the management of these cases. Any patient more than 30 weeks of gestation the management appears to be better defined, with conservative management being the standard norm. This is, done under close observation with active mobilization to prevent venous stasis and possible exacerbation of symptoms on bed rest. This is continued till the baby achieves the age of viability after which the baby can be delivered with elective cesarean section. However patients with less than 30 weeks of gestation especially with progression of neurological deficits pose a tougher clinical scenario. The approach in such cases would be to go ahead for a surgical decompression with informed consent regarding danger to fetal viability. However, our patient was explained about the condition, the various treatment options including the morbidity and mortality associated with each of the available procedures. As the patient was a primi and due to various other social and cultural reasons the patient opted to wait till 32 weeks of gestation before undergoing any interventions for the progressive neurological deficits. In view of the facts that available literature suggests that majority of patients documented in the literature recover well from pregnancy-related vertebral hemangioma, despite long periods of spastic paresis and weakness, we decided not to pose strong objections to the patients choice of treatment. The patient underwent trans-arterial embolization of T2

vertebral body hemangioma and later operated by corpectomy of the T2 vertebra and stabilization with autologous iliac bone grafting and fixation with anterior cervical plate after which she showed dramatic response. At the last follow-up 24 months after the surgery she has full neurological recovery and is able to perform all activities without any hindrances. The child is also healthy.

CONCLUSION

Though early surgical intervention has been advocated for patients with pregnancy related hemangiomas presenting before 30th weeks of gestation, in selected cases we can delay the intervention under careful observation. The neurological recovery in these type of cases has been uniformly good.

REFERENCES

- Schmorl G, Junghanns H. The human spine in health and disease. Besemann EF, trans-ed. 2nd ed. New York, NY: Grune & Stratton, 1971.
- Cortet B, Cohen A, Deprez X, Deramond H, Lejeune J: Interet de la vertebroplastie couplee a une decompression chirurgicale dans le traitement des angiomes vertebraux aggressifs, Rev. Rhumatisme 1994, 61(1): 16-22.
- Derenbaum F, Cote D, Rancurel G: Complications tardives d'un angiome vertebraal, Revue de rhumatisme 1990, 57(3): 211-12
- Hammes EM Cavernous Hemangioma of the Vertebra. Arch Neurol Psychiatry. 1993;29;330-333
- Healy M, Herz DA, Pearl LL. Spinal hemangiomas. Neurosurg 1983;13; 689-691
- Hemmy DC, Geem MC, Armbrust FM, Larsons J. Resection of a vertebral hemangioma after preoperative embolization. J Neurosurg. 1977;47;282-85.
- Laredo JD, Assouline E, Gelbert F, Wybier-Merland JJ, Tubiana JM. Vertebral hemangiomas: Fat content as a sign of aggressiveness. Radiol. 1990;177;467-72.
- Acquaviva R, Lhevenot C. Compression medullaire recidivante par hemangiome vertebraal. Role determinant des grossesses. Maroc Med. 1957;389:924-44.
- Askenasy H, Behmoaram A. Neurological manifestation in hemangioma of the vertebrae. J Neurol Neurosurg Psychiatry. 1957;20:276-284.
- Kiroglu Y, Benek B, Yagci B, Cirak B, Tahta K, Spinal cord compression caused by vertebral hemangioma being symptomatic during pregnancy. Surg Neurol. 2009; 71(4): 487-92.
- Kamath V, Shetty AP, Rajshekran S. Symptomatic vertebral hemangioma in pregnancy treated antepartum. A case report with review of literature. Eur Spine J. 2008 September; 17(Suppl 2): 299-303.
- Virchow R. Die krankhaften Geschwulste, vol 3. Berlin: A Hirschwald; 1867.
- Mealey J Jr, Carter JE. Spinal cord tumor during pregnancy. Obstet Gynecol. 1968;32: 204-9
- Askenasy H, Behmoaram A. Neurological manifestation in hemangioma of the vertebrae. J Neurol Neurosurg Psychiatry. 1957;20:276-84.
- Brobeck O. Hemangioma of vertebrae associated with compression of the spinal cord. Acta Radiol. 1950;34:235-43.
- Schwartz DA, Nair S, Hershey B, et al. Vertebral arch hemangioma

- producing spinal cord compression in pregnancy—diagnosis by magnetic resonance imaging. *Spine*. 1989; 14:888–90.
17. Tekkok IH, Acikgoz B, Saglam S, et al. Vertebral hemangioma symptomatic during pregnancy: report of a case and review of literature. *Neurosurgery*. 1993;32: 302–306.
18. Theodore HS, Hanina H, Charles JR. Estrogen and progesterone receptor negative T11 vertebral hemangioma presenting as a postpartum compression fracture: case report and management. *Neurosurgery*. 2000;46(1):218–21.
19. Chi JH, M.D, Manley GT, Dean C. Pregnancy-related vertebral hemangioma Case report, review of the literature, and management algorithm. *Neurosurg Focus* 2005;19 (3):E7.

How to cite this article: Ravikiran HG, Harish RP, Ravikumar M et. al. Symptomatic capillary hemangioma in pregnancy: A rare case report of complete recovery of paraparesis with review of literature. *Int J Health Sci Res*. 2013;3(11):161-166.
