



Case Report

Life Threatening Complications of a Preventable Illness

Budensab AH^{1*}, SN Joshi²

²Professor, ²Professor & HOD,
Dept. of Pediatrics, SDM College of Medical Sciences and Hospital, Dharwad-580009, Karnataka, India.

*Correspondence Email: budensab.sab@gmail.com

Received: 20/08/2013

Revised: 26/09/2013

Accepted: 30/09/2013

ABSTRACT

Diphtheria continues to be reported in many parts of world even though effective vaccine available. Complete heart block is rare but often a fatal complication. Other complications like airway obstruction due to laryngitis and palatal paralysis can occur. We report 3 cases with complications of diphtheria. Aggressive management including pacing and antidiphtheritic serum may improve the outcome.

Key words: complete heart block, myocarditis, laryngitis, palatal palsy

INTRODUCTION

Diphtheria is a major preventable disease of childhood with high morbidity and mortality. Although it is no longer a public health problem in the developed nations, it continues to be reported from developing world.⁽⁰⁻⁴⁾ The toxin mediated disease affects multiple systems. Cardiovascular involvement can occur in 10-25% of patients and is a major contributor to the mortality varying from 50% to 75%.⁽⁵⁻⁶⁾ Cardiac manifestations include myocardial dysfunction as well as bradyarrhythmias and tachyarrhythmias; although the most feared one is complete heart block (CHB) with almost all cases being fatal despite ventricular pacing.⁽⁷⁾ neurological complications in the form of palatal palsy bulbar palsy and peripheral neuropathy can occur.⁽³⁾ Laryngitis causing obstruction can occur as primary or secondary extension from pharynx can

manifest as hoarseness croupy cough and stridor.

CASE REPORTS

Case 1

4 year old boy presented with swelling of neck and fever since 8 days and difficulty in swallowing and breathlessness since 3 days. There was no history of nasal regurgitation of fluids or weakness of limbs. He was 4th child in the family coming from poor socioeconomic background not immunized except BCG.

Child was conscious afebrile, pulse rate 24/minute, respiratory rate 36/minute, BP not recordable. Throat examination revealed enlarged congested tonsils with whitish membrane seen in left tonsil. There was bradycardia, normal heart sounds with grade 2 systolic murmur, abdomen examination revealed 2 cm hepatomegaly other systems being normal. Complete blood count revealed Hb 10.5gms% Total count

19100/cumm platelets 701000 /cumm, blood urea 45mg%, creatinine 2.2mg% Liver function tests normal. Throat swab culture yielded no growth.

ECG showed complete heart block with ventricular rhythm, child was resuscitated with IV fluids and child was seen by cardiologist transvenous pacemaker was inserted to right ventricle and child's heart rate increased to 90/min and BP picked up after pacemaker insertion. Child was cared in pediatric intensive care unit. Injection Crystalline penicillin 500000 units intravenously 6 hourly and Antidiphtheritic serum 60000units was given. Child was also started on heparin infusion. Child was on pacemaker for 9 days and died on 10th day due to tachycardia, arrhythmias and heart failure.

Case 2

12 yr old girl presented with fever since 5 days, sore throat 3 days and hoarseness of voice since 2 days. There was no history nasal regurgitation of fluids or weakness. She is 2nd child among 7 siblings and mother does not remember whether immunized.

Child was conscious oriented febrile Temperature 38.5C Pulse rate 100/minute Respiratory rate 24/minute Blood pressure 106/60mmHg Weight 30kg. On examination of throat revealed white patches over posterior pharyngeal wall extending downwards, swab was taken for Albert stain and culture. Other systems were normal. Hb

11.8grams% Total count 9480/cumm, platelets 312000/cumm Throat swab Albert stain was positive for corynebacterium diphtheria, Electrocardiogram normal, Echocardiography normal. Child was given intravenous fluids, Injection Crystalline penicillin 10Lakh units intravenous 6 hourly and Antidiphtheritic serum 100,000 units. Child made an evenful recovery and discharged on 10th day after immunization.

Case 3

6 yr old boy presented with drooling of saliva nasal regurgitation of fluids and difficulty in swallowing since 1 week. There was history of fever and sore throat one month before. He was 2nd among 4 siblings and immunization was not regular and booster doses were not given.

Child was conscious oriented Temperature 37°C Pulse rate 90/minute Respiratory rate 24/minute BP 100/70mmHg Weight 13 kg. Pooling of secretions in mouth, difficulty in swallowing, nasal regurgitation while swallowing and speech difficulty was noted. Other systems normal. Complete blood count normal. Throat swab culture no growth. Electrocardiogram and Echocardiography normal. Child was treated with Injection Crystalline penicillin 10Lakh units intravenous 6 hourly, Antidiphtheritic serum 40000 units, Intravenous fluids and nasogastric tube feeding. The child could take feeds orally without regurgitation on 10th day and discharged after immunization.

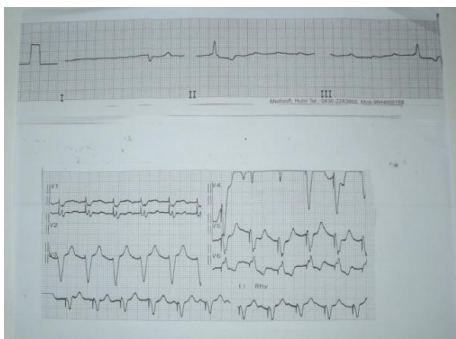


Figure 1. ECG before and after pacemaker insertion.

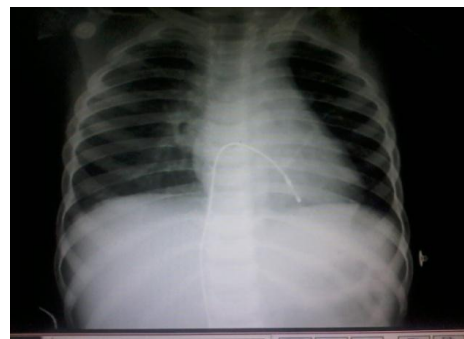

Figure 2. Chest X-ray showing pacemaker insertion.

DISCUSSION

Diphtheritic myocarditis occurs in 10-20% of patients presenting with oropharyngitis. (8) Relatively recent Indian series on diphtheria report a 16-66% occurrence of myocarditis; followed by neuritis 6.5% and respiratory obstruction 2.8%. (3,6,9) Diphtheritic myocarditis is

Toxin mediated inhibition of protein synthesis is the essential mechanism for all systemic manifestations in diphtheria. Diphtheria toxin is directly cardiotoxic and it causes DNA fragmentation and cytolysis by inhibiting the elongation factor-2 activity in protein synthesis. (12) Data regarding CHB associated with myocarditis including those due to diphtheria is limited in recent literature. Conduction system disturbances in patients with diphtherial myocarditis are markers of severe myocardial damage and are uniformly fatal despite ventricular pacing. (7)

Apart from supportive measures, treatment options in diphtheria myocarditis are limited. Antitoxin is of proven value in the early stages of the illness, but it has limited action against penetrating toxin or toxin already absorbed into the cell. Hence, it is unlikely to have made much of a difference if presented late. Yet, antitoxin administration to all who are suspected of diphtheria myocarditis or other complications is recommended as this is the only specific antidote available and may neutralize any unbound toxin. The role of immunosuppressive therapies such as steroids and immunoglobulin's are not proven yet. (13,14) In a study of 66 patients with diphtheria, steroid therapy did not prevent the occurrence of myocarditis and of neuritis. (13) A study reported that carnitine showed a significant reduction in incidence of myocarditis and a significant reduction in mortality as compared with controls. (15)

It is important to remember the preventive measures against diphtheria for the care givers. We provided standard droplet infection prophylaxis to all the suspected diphtheria cases. Moreover, all were given antibiotic prophylaxis with Azithromycin 500 mg once daily or erythromycin 500 mg QID for the duration

associated with a mortality rate of 60-70%, and is the most common cause of death in diphtheria. (6) Conduction system involvement in diphtheria is shown to be due to acute inflammation of sinoatrial and atrioventricular nodes leading to even their disruption in fatal cases. (10,11)

of contact. All traceable contacts of these patients were advised to get throat cultures done and to watch for symptoms. Close household contacts of these patients were also given prophylactic course of antibiotics.

Limitations

The report pertains to only 3 patients; one had complete heart block due to myocarditis one had laryngitis and one palatal palsy. The organism was isolated in one child. Mechanical support devices or ECMO was not used in the patient with cardiogenic shock that could influence the outcome potentially.

CONCLUSION

Diphtheritic myocarditis and other complications continue to occur among the poor under vaccinated children and are associated with very high mortality. Complete heart block due to diphtheritic myocarditis carries high risk of mortality.

REFERENCES

1. Singh J, Harit AK, Jain DC, Panda RC, Tewari KN, Bhatia R, et al. Diphtheria is declining, but continues to kill many children: Analysis of data from a sentinel

- center in Delhi, 1997. *Epidemiol Infect* 1999; 123:209-15.
2. Lodha R, Dash NR, Kapil A, Kabra SK. Diphtheria in urban slums in north India. *Lancet* 2000;355:204.
 3. Anima H, Malay M, Santanu H, Rajashree R, Sita C, Baran SA. A study on determinants of occurrence of complications and fatality among diphtheria cases admitted to ID and BG hospital of Kolkata. *J Commun Dis* 2008;40:53-8.
 4. Ornek E, Ureyen CM, Kurtul A, Oksüz F. Diphtheria myocarditis in Turkey after years. *Anadolu Kardiyol Derg* 2012;12:279-80.
 5. Kneen R, Pham NG, Solomon T, Tran TM, Nguyen TT, Tran BL, et al. Penicillin vs. erythromycin in the treatment of diphtheria. *Clin Infect Dis* 1998;27:845-50.
 6. Jayashree M, Shruthi N, Singhi S. Predictors of outcome in patients with diphtheria receiving intensive care. *Indian Pediatr* 2006;43:155-60.
 7. Stockins BA, Lanas FT, Saavedra JG, Opazo JA. Prognosis in patients with diphtheric myocarditis and bradyarrhythmias : assessment of results of ventricular pacing. *Br Heart J* 1994;72:190-1.
 8. Hoyne A, Welford N. Diphtheritic myocarditis, a review of 496 cases. *J Pediatr* 1934;5:642-53.
 9. Havaladar PV, Sankpal MN, Doddannavar RP. Diphtheritic myocarditis: Clinical and laboratory parameters of prognosis and fatal outcome. *Ann Trop Paediatr* 2000;20:209-15.
 10. Smith S. Heart rhythm in diphtheria. *JAMA* 1922;77:765-71.
 11. James TN, Reynolds EW Jr. Pathology of the cardiac conduction system in a case of diphtheria associated with atrial arrhythmias and heart block. *Circulation* 1963;28:263-7.
 12. Collier RJ. Diphtheria toxin: Mode of action and structure. *Bacteriol Rev* 1975;39:54-85.
 13. Thisyakorn U, Wongvanich J, Kumpeng V. Failure of corticosteroid therapy to prevent diphtheritic myocarditis or neuritis. *Pediatr Infect Dis* 1984;3:126-8.
 14. Mason JW, O'Connell JB, Herskowitz A, Rose NR, McManus BM, Billingham ME, et al. A clinical trial of immunosuppressive therapy for myocarditis. The myocarditis treatment trial investigators. *N Engl J Med* 1995;333:269-75.
 15. Ramos AC, Barrucand L, Elias PR, Pimentel AM, Pires VR. Carnitine supplementation in diphtheria. *Indian Pediatr* 1992;29:1501-5.

How to cite this article: Budensab AH, Joshi SN. Life threatening complications of a preventable illness. *Int J Health Sci Res.* 2013;3(11):157-160.
