



Original Research Article

Morphometric Study of Human Cadaveric Caecum and Vermiform Appendix

Siva Nageswara Rao Sundara Setty^{1*}, Raja Sekhar Katikireddi²

¹Associate Professor, ²Assistant Professor,
Department of Anatomy, Bhaskar Medical College, Yenkapally, Moinabad, Ranga Reddy District, Andhra Pradesh.

*Correspondence Email: sivanageswararao55@yahoo.com

Received: 14/07/2013

Revised: 13/08/2013

Accepted: 14/08/2013

ABSTRACT

Aim: The aim of present cadaveric study is, to determine the position, Shape, length, breadth of caecum and vermiform appendix and ileal opening into caecum.

Materials & Methods: The total number of specimens studied for this present work was 90. Out of 90 specimens 40 were adult cadavers and 50 dead fetuses. The total specimens were collected from department of anatomy and Gynecology & obstetrics, Guntur and Bhaskar medical colleges, Andhra Pradesh, India.

Results: The position of caecum in adults 100 % in right iliac fossa, in fetuses 76 % in right lumbar, 20 % in subhepatic, 4 % in right iliac fossa. The shape of caecum was adult type in 100 % in adults, in fetuses 84% foetal type, 14% adult type, 2% quadrate type. Entry of ileum into caecum was in adults 100 % posteriomedially, in fetuses 70% posteriomedially, 20% medially, 8% anteriomedially, 2% anteriorly. The average length of caecum in adult male was 54.9mm, in female 50mm and average breadth in adult male was 64.3, female was 59mm. In fetuses, average length of caecum in male foetus was 11.5mm, in female 11.7mm and average breadth in male foetus was 14.5mm, female was 14.5mm. The position of appendix in adults, 50% retrocaecal, 10% subcaecal, 15% pelvic, 5% promantric, 5% midinguinal, 5% preileal, 10% postileal. In fetuses 54% retrocaecal, 22% subcaecal, 10% preileal, 12% postileal, 2% midinguinal position. **Conclusion:** In the present study we compared and concluded, the various parameters of adult and foetal caecum and appendix with standard parameters and previous literatures and also the morphometric parameters were concluded between adult sexes and foetal sexes.

Key words: Vermiform appendix, Caecum, Morphometry, Ileum.

INTRODUCTION

The caecum is a large blind pouch situated in the right iliac fossa. It is continuous proximally with the distal ileum and distally with the ascending colon. The average length of caecum is 6 cm and breadth is 7.5 cm. The caecum is usually short, conical and broad based in early fetal life, it increases initially in length more than

in breadth, As the fetus growth proceeds. The ileum opens into the posteromedial aspect of the large intestine at the junction of the caecum and colon. The vermiform appendix is a narrow, tubular, worm like structure, which arises from the posteromedial aspect of caecum, approximately 2 cm below the end of the ileum. Retrocaecal or retrocolic are the

commonest positions of appendix, it varies from 2–20 cm in length. [1] It is absent in fish, amphibians, reptiles, birds and most mammals. Among primates it is present in anthropoid apes and man. During embryonic development of appendix, the position in the abdomen is not constant. Depending upon stage of development and rotation of gut, appendix is found at different locations in the abdominal cavity. [2,3]

MATERIALS & METHODS

The total number of specimens studied for this present work was 90. Out of 90 specimens 40 were adult cadavers (33 male and 7 female) and 50 dead fetuses (24 male and 26 female). The total specimens were collected from department of anatomy and Gynecology & obstetrics, Guntur and Bhaskar medical colleges, Andhra Pradesh, India. The caecum and appendix was examined in adult cadavers in routine dissection, which placed for medical students. Fetuses were preserved by

injecting the common embalming preservative fluids.

The vertical incision was given from xiphisternum to pubic symphysis, abdomen was opened, greater omentum moved to one side and coils of small intestine, transverse colon pushed towards the upper abdomen to visualize the ileocaecal junction and vermiform appendix. The position, Shape, length, breadth of caecum and vermiform appendix were measured and ileal opening into caecum was also noted. The position of appendix was confirmed by the direction of tip of the appendix.

RESULTS

Position of caecum: In all adult specimens the caecum was situated in right iliac fossa. Out of 50 fetuses, in 38 specimens the caecum was situated in right lumbar region (FIGURE: 01) and in 10 fetuses, it was found in the sub hepatic region (FIGURE: 02). In 2 fetuses the caecum found in the right iliac fossa (FIGURE: 03), (TABLE: 01).

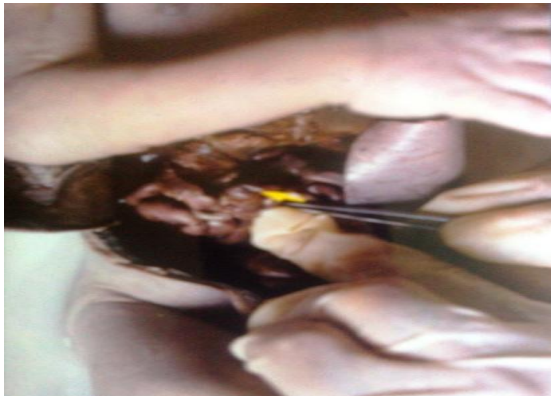

FIGURE: 01: Arrow showing the caecum in right lumbar position in foetus.

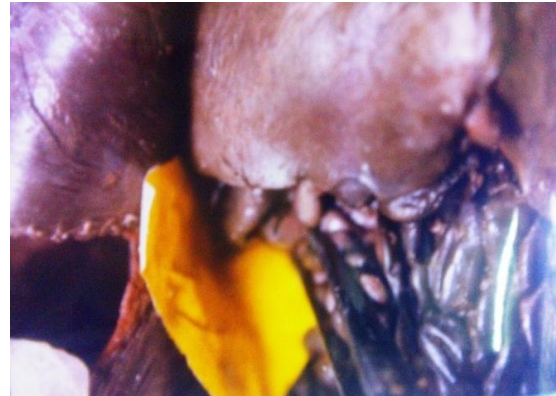

FIGURE: 02: showing the caecum in sub hepatic position in foetus.

Shape of caecum: The caecum was adult type in all the 20 adult specimens. In 42 foetal specimens the shape of caecum was foetal type (conical) type. In 7 foetal specimens the shape of caecum was adult type. In one foetus it was quadrate in type (TABLE: 01).

Ileal opening into caecum: In all 40 adult specimens the ileum was opened into posterior medial to caecum. In 35 (70%) fetuses the terminal part of the ileum has opened posterior medial into the caecum. In 4(8%) fetuses the ileum has opened into caecum anterio medially. In one (2%)

foetus the ileum has opened into caecum anteriorly. In 10 (20%) fetuses the terminal part of ileum was opened medially into the caecum.

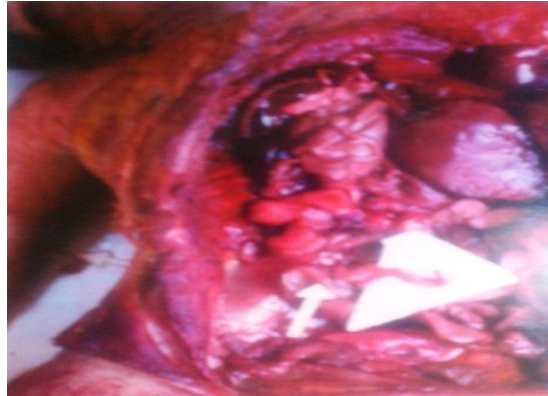


FIGURE: 03: showing the caecum and appendix in right iliac fossa in position in foetus.

TABLE: 01: SHOWS THE PARAMETERS OF POSITION AND SHAPE OF CAECUM.

POSITION OF CAECUM				
SPECIMENS	RIGHT LUMBAR	SUBHEPATIC	RIGHT ILLIAC FOSSA	PERCENTAGES
ADULTS	0	0	40	0%, 0%, 100%
FOETUSES	38	10	2	76%, 20%, 4%
SHAPE OF CAECUM				
SPECIMENS	FOETAL TYPE	ADULT TYPE	QUDRATE TYPE	PERCENTAGES
ADULTS	0	40	0	0%, 100%, 0%
FOETUSES	42	7	1	84%, 14%, 2%

Measurements of caecum: The length of caecum in 33 male adults varied from 50mm to 60mm with an average of 54.9mm and the breadth was varied from 56mm to 70mm with an average of 64.3mm. The length of caecum in 7 Fe male adults varied from 40mm to 60mm with an average of 50mm and the breadth was varied from 50mm to 70mm with an average of 59mm (TABLE: 02).

TABLE: 02: SHOWS THE PARAMETERS OF THE LENGTH AND BREADTH OF CAECUM IN MALE AND FEMALE ADULT.

THE LENGTH AND BREADTH OF CAECUM IN MALE ADULTS		
SPECIMENS	LENGTH INMM	BREADTH IN MM
1	55	65
2	55	70
3	53	62
4	52	65
5	60	70
6	58	67
7	60	65
8	50	65
9	53	61
10	50	56
11	54	62
12	54	65
13	60	64
14	55	65
15	55	66
16	54	64
17	56	63
18	50	62
19	52	66
20	54	64
21	56	63
22	53	65
23	54	65
24	56	70

25	60	69
26	52	51
27	53	63
28	57	65
29	54	60
30	55	66
31	54	64
32	55	55
33	53	60
	AVERAGE LENGTH : 54.9MM	AVERAGE BREADTH: 64.3MM
THE LENGTH AND BREADTH OF CAECUM IN FEMALE ADULTS		
1	50	60
2	60	70
3	50	60
4	50	56
5	40	50
6	48	55
7	52	62
AVERAGE LENGTH: 50MM		AVERAGE BREADTH: 59MM

In 24 male fetuses the length of caecum varied from 10mm to 15mm with an average of 11.5mm and breadth was varied from 12mm to 18mm with an average 14.5mm (TABLE: 03). In 26 Female fetuses the length of caecum varied from 8mm to 15mm with an average of 11.7mm and breadth was varied from 12mm to 18mm with an average 14.5mm (TABLE: 04).

TABLE: 03: SHOWS THE PARAMETERS OF THE LENGTH AND BREADTH OF CAECUM IN MALE FOETUSES.

THE LENGTH AND BREADTH OF CAECUM IN MALE FOETUSES		
SPECIMENS	LENGTH IN MM	BREADTH IN MM
1	12	15
2	15	18
3	15	17
4	10	15
5	12	15
6	12	15
7	12	18
8	12	15
9	10	12
10	12	16
11	12	18
12	10	12
13	12	15
14	10	12
15	10	15
16	10	12
17	10	12
18	13	15
19	10	15
20	15	15
21	10	12
22	10	12
23	12	15
24	10	12
AVERAGE LENGTH : 11.5mm		AVERAGE BREADTH: 14.5mm
THE LENGTH AND BREADTH OF CAECUM IN MALE FOETUSES		

TABLE: 04: SHOWS THE PARAMETERS OF THE LENGTH AND BREADTH OF CAECUM IN FEMALE FOETUSES.

THE LENGTH AND BREADTH OF CAECUM IN FEMALE FOETUSES		
SPECIMENS	LENGTH IN MM	BREADTH IN MM
1	10	15
2	15	18
3	14	16
4	12	15
5	12	15
6	15	16
7	12	15
8	10	13
9	14	16
10	12	15
11	10	12
12	10	14
13	12	15
14	12	15
15	10	12
16	10	12
17	08	12
18	12	15
19	12	15
20	10	12
21	09	13
22	14	17
23	13	15
24	12	15
25	15	18
26	10	12
	AVERAGE LENGTH: 11.7mm	AVERAGE BREADTH: 14.5mm

Position of vermiform appendix: Out of 40 adult specimens, in 20 specimens, the appendix was in retrocaecal position, in 4 specimens subcaecal in position, 6 specimens pelvic in position, in 2 specimen promonteric position, in 2 specimen midinguinal position, in 2 specimen preileal position and 4 specimens it was post ileal position.

Out of 50 foetal specimens, in 27 specimens appendix was in retrocaecal position (FIGURE: 04), 11 specimens subcaecal position (FIGURE: 05), 5 specimens preileal position (FIGURE: 06), 6 specimens postileal position, one foetus it was midinguinal position (FIGURE: 07), (TABLE: 05).

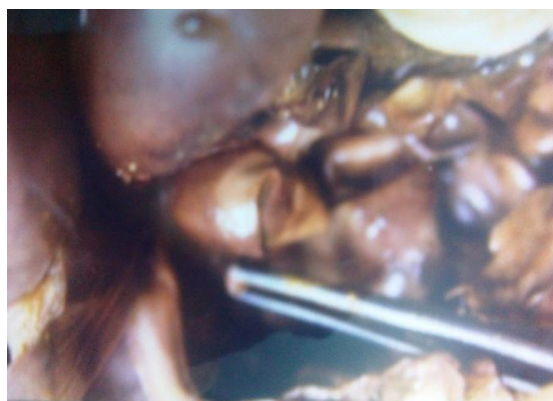

FIGURE: 04: Forceps showing the retro caecal position of vermiform appendix in foetus.




FIGURE: 05: Arrow showing the sub caecal position of vermiform appendix in foetus.

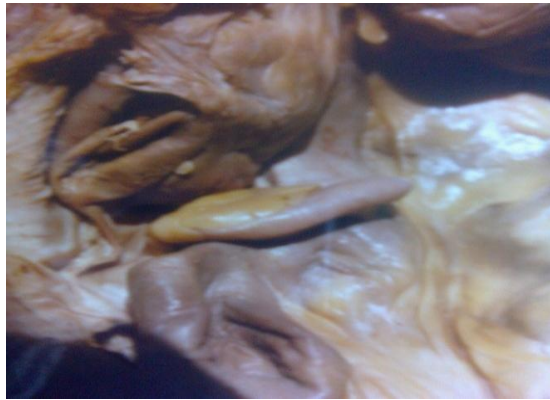

FIGURE: 06: Arrow showing the pre-ileal position of Vermiform appendix in foetus.

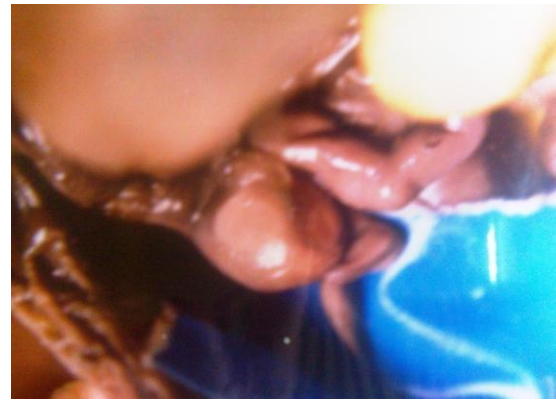


FIGURE: 07: Arrow showing the mid inguinal position of vermiform appendix in foetus.

TABLE: 05: SHOWS THE DIFFERENT POSITIONS OF APPENDIX IN ADULT AND FOETUSES.

POSITION OF THE VERMIFORM APPENDIX IN ADULT AND FOETUSES							
SPECIMEN	RETRO CAECAL	SUB CAECAL	PELVIC	PRO MONTERIC	MID INGUIINAL	SPLENIC	
ADULTS	20	4	6	2	2	2	4
PERCENTAGE	50%	10%	15%	5%	5%	5%	10%
FOETUSES	27	11	0	0	1	5	6
PERCENTAGE	54%	22%	0	0	2%	10%	12%

Measurements of vermiform appendix: In 33 male adult specimens, the length of the appendix was varying from 45mm to 100mm with average length of 65.2mm and breadth at base was from 5mm to 10mm with average of breadth of 6mm. In 7 Female adult specimens, the length of the appendix was varying from 55mm to 80mm with average length of 62.8mm and breadth at base was from 4mm to 7mm with average of breadth of 5.42mm. In 24 male foetal specimens, the length of the appendix was varying from 25mm to 50mm with average length of 35.8mm and breadth at base was from 2mm to 5mm with average of breadth of 3.1mm. In 26 female fetuses, the length of the appendix was varying from 20mm to 45mm with average length of 32.3mm and breadth at base was from 2mm to 4mm with average of breadth of 2.9mm (TABLE: 06).

TABLE: 06: SHOWS THE AVERAGE LENGTH AND BREADTH OF ADULT MALE, FEMALE AND FOETAL MALE, FEMALE VERMIFORM APPENDIX.

AVERAGE LENGTH IN MM AND BREADTH IN MM OF ADULT MALE, FEMALE AND FOETAL MALE, FEMALE VERMIFORM APPENDIX		
SPECIMEN	AVERAGE LENGTH	AVERAGE BREADTH
ADULT MALE	65.2	6
ADULT FEMALE	62.8	5.42
MALE FOTUSES	35.8	3.1
FEMALE FOETUSES	32.3	2.9

DISCUSSION

Vermiform appendix is involved in inflammatory disease like appendicitis, it is the most common cause of emergency operation, but appendicitis is not common in children below two years of age due to its anatomical characteristics and its relation with caecum. [4] According to Jorge et.al, during development, caecum experiences differential growth in certain parts which is responsible for modifications in shape, size and location. [5] Reshma M d et al reported, the location of appendix in relation to

abdominal region presented higher incidence of sub-hepatic position in less than 30 weeks fetuses and right iliac fossa location in more than 30 weeks fetuses. ^[6] In The present study observed that, the length of the appendix in males was more than in females, it coincides with previous authors Katzarski M,^[7] Ajmani ML,^[8] Golalipour MJ.^[9] According to Solanke T F, Origin and position of appendix are subject to alterations with the race of the population. ^[10] According to Wakley et al, the position of appendix was retrocaecal and retrocolic 65.28%, pelvic 31%, subcaecal 2.26%, preileal 1% and postileal 0.4%. ^[11] Buchanan et al reported the average length of caecum was 62.5, ^[12] Treves et al 56mm. ^[13] Arindom Banerjee et al reported caecum position was found in right iliac fossa (96%) and shape was adult type (88%) and appendix was retrocaecal position in majority of cases. ^[14]

CONCLUSION

Knowledge of Anatomical Variation of different positions, shapes, location, parameters, dimensions of caecum and appendix is very important for surgeons to perform accurate operations. These parameters are alters depending upon race, sex, age and population, so the present observations in this study given the knowledge of morphometry of caecum and appendix in Indian population.

ACKNOWLEDGEMENTS

I am grateful to my teachers Dr. K. Anasuya (Professor), Dr. K. Krupadhanam. (Professor), Dr. K.V. Vijaya Saradhi (Professor & HOD) and previous authors, publishers, editors of all of those articles, journals and books from where the literature of this article has been reviewed and discussed.

REFERENCES

1. Susan Standring. Gray's Anatomy. Anatomical basis of clinical practice. 39th ed. Churchill Livingstone, 2005; 1189-1190.
2. Moore KL, Persaud TVN. Before we are born. Essentials of embryology and birth defects. 5th ed, W.B. Saunders Company. Philadelphia; 1988: 273-80
3. Kowit Chaisiwamongkol, Thanarat Chantaupalee, Nawaporn Techataweewan, Yanyong Toomsan, Tansita Aranateerakul, Somsuda Teepsawang, Sittichai Iamsaard, Tuangprat Srikulwong. Position Variation of Vermiform Appendix in Northeast Thai Cadavers. Srinagarind Med J; 2010; 25(3):250-5.
4. Grosfeld JL, Weinberger M, Clatworthy HW. Acute appendicitis in children, a Case Studies in Paediatric Surgery. 1973; 8(2): 285-292.
5. Jorge, A, Ferreira, JR. and Pacheco, YG, Braz. J. Development of vermiform appendix in children from different age groups; Morphol. Sci. 2009; 26 (2): 68-76.
6. Reshma M.d et al, Morphological features and morphometric parameters of human fetal vermiform appendix at different gestational ages. Int J Anat Res.2013; 02:18-25.
7. Katzarski M, Dutta CR. The vermiform appendix in Ghanaians. Ghana Med J. 1971; 4: 96-9.
8. Ajmani ML, Ajmani K. The position, length and arterial supply of vermiform appendix. 1983; 153(4):369-74.
9. Golalipour MJ, Aray B, Azarhoosh R, Jahanshahi M. Anatomical Variations of vermiform appendix in South-East Caspian sea (Gorgan-

- Iran). J Anat Soc India. 2003; 52(2): 141-3.
10. Solanke, T. F. The blood supply of the vermiform appendix in Nigerians. Anat. 1968; 102: 353-361.
 11. Wakely CPS. The position of the vermiform appendix as described by analysis of 10,000 cases. J Anat. 1933; 67: 272.
 12. Jones FW (ED) Buchanan's manual of anatomy. London, 8 th ed. Williams & Wilkins. 1950; 758-790.
 13. Treves F. Lectures on anatomy of intestinal canal and peritoneum in man. Br Med J. 1885; 1: 527-530.
 14. Arindom Banerjee, Anil Kumar, Arunabha Tapadar, M Prany. Morphological variations in the Anatomy of caecum and appendix- A cadaveric Study. National journal of clinical anatomy. 2012; 1: 30-35.

How to cite this article: Setty SNRS, Katikireddi RS. Morphometric study of human cadaveric caecum and vermiform appendix. Int J Health Sci Res. 2013;3(10):48-55.
