

Evaluation of Vertical Magnification of a Digital Panoramic Machine Kodak 8000 for Implant Planning in Complete Edentulous Patients

Shweta Dwivedy¹, Sunira Chandra², Nivedita Tayde¹, Sudarshan Pandit³,
Juhi Singh⁴

¹Department of Oral Medicine and Radiology, SMBT IDSR, Nashik, India

²Department of Oral Medicine and Radiology, Saraswati Dental College, Lucknow, India

³Department of Haematology, Ashoka Medocover Hospital, Nashik, India

⁴Department of Dentistry, Shyam Shah Medical College, Rewa, India

Corresponding Author: Shweta Dwivedy

DOI: <https://doi.org/10.52403/ijhsr.20230927>

ABSTRACT

To evaluate the variation in vertical magnification of digital panoramic machine Kodak 8000 Panoramic System in relation to different regions of maxillary and mandibular edentulous arches and to compare this variation in magnification. The study sample of 40 patients was divided into 2 different groups (20 each) depending upon the two different diameters of metallic spheres i.e., 3mm & 6mm used as radiographic reference. Each group was further subdivided into 2 subgroups depending upon the arch of placement of metallic sphere. The metallic spheres were placed in 4 different regions of maxilla and mandible. Digital panoramic radiograph was obtained and was subjected for measurement using Trophy Dicom Software. Data was analyzed statistical analysis by paired “t” test and student “t” test. The present study has established that there is variation in magnification both in vertical and horizontal direction for maxilla and mandible. In maxillary arch vertical magnification rate shows lowest values for 3mm spheres in right posterior, right and left anterior regions. In mandibular arch vertical magnification shows lowest values for 3mm spheres in right and left posterior, right anterior regions. The vertical magnifications in posterior regions were higher than anterior region. On comparing the magnification of maxilla and mandible, values were higher in maxilla. The study concludes that radiographic reference objects (use of metallic spheres) can be used as a steady method for radiographic assessment in edentulous patients, as there is variation in the magnification in both maxillary and mandibular arch area specifically.

Keywords: panoramic, radiography, magnification, digital radiography, edentulous

INTRODUCTION

Field of diagnosis and medicine was revolutionized with the advent of radiation for imaging purpose. In the field of dental medicine, diagnosis and treatment planning panoramic radiographs are the most contributing ones.^{1,2} Panoramic radiography provides a descriptive correlation of maxillofacial structures within the focal trough. It also specifies the location of important anatomical structures in relation

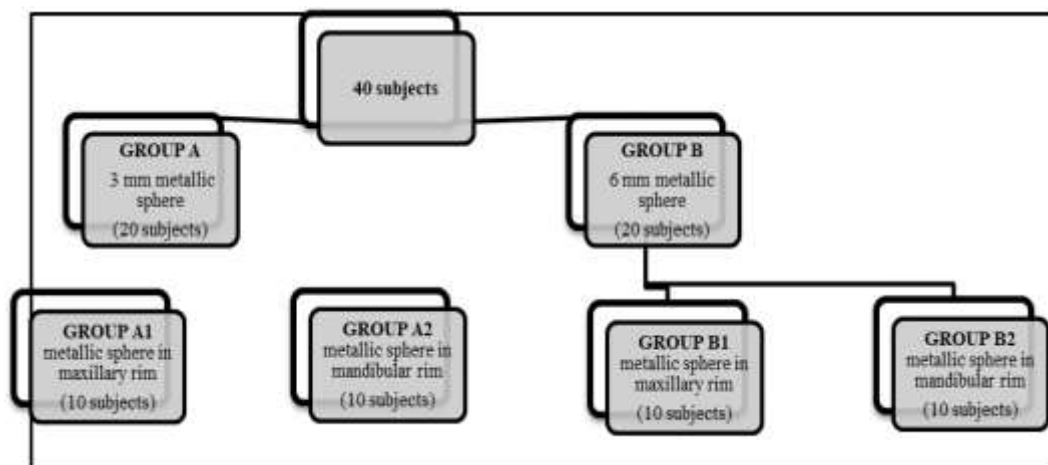
to the alveolar crest. It also endow with estimation of bone height, vital structures, and any pathological conditions in the area.³ Panoramic radiography with the introduction of digital panoramic radiography has the years trounce many confines of controlled magnification in the vertical dimensions, decreased overlapping of tooth contact areas and single point contact of the rotating beam onto the object to allow for a sharper, well defined images.⁴

Also digital image acquisition results in reduced processing time and aided with variety of image manipulation tools.⁵ Foremost shortcoming of panoramic radiography is magnification, discrepancy in magnification occur according to the type of equipment used and the position of the desired landmarks during image acquisition.⁶ Also, the amount of magnification is not the uniform throughout. Distortion results from varied magnification in the horizontal and vertical dimensions in different parts of an image.³ Considering a standard magnification ratio for assessment during treatment planning is complex and should be avoided.⁶ As panoramic radiograph is most commonly used diagnostic tool and aids in treatment planning, the present study was conducted to evaluate the variation in vertical magnification of digital panoramic machine in relation to eight regions of maxillary and mandibular edentulous arches.

MATERIALS & METHODS

This prospective study conducted on edentulous patients attending the OPD

seeking for complete denture fabrication, and was approved by the Institutional human ethics committee & Institutional Research & Development committee. A total of 40 individuals, including both males and females, were randomly selected for the study after obtaining their written informed consent. The total sample was divided into 2 groups of 20 subjects each, according to the variation in diameter of metallic balls (3mm & 6mm) used in the study. These groups were further divided into 2 subgroups each of 10 patients according to the arch of placement of specified radiopaque reference object (metallic sphere) i.e., maxillary or mandibular arch (Flow chart: 1). In first subgroup metallic ball was placed at 4 sites in maxillary arch and in second subgroup metallic ball were placed at 4 sites in mandibular arch. Metallic balls in each arch at a time were placed in anterior canine region and posterior 1st molar region bilaterally on the edentulous arch considering adjacent associate anatomical landmarks in mind to identify the position on edentulous arch.



FLOW CHART: 1 Sample distribution

Primary impression of the selected edentulous individual was made using impression compound and metallic non perforated impression tray and primary cast was prepared using dental plaster. On the prepared primary cast, temporary base plate was fabricated using cold cure acrylic both for maxillary and mandibular arch. Small

circular slots were prepared in canine region and molar region bilaterally in order to seat the radiopaque reference object i.e., metallic sphere as close as possible to alveolar crest. Then a wax rim of desired vertical height was fabricated over the base plate in which the metallic spheres were thereby placed. (fig. 1a and 1b)

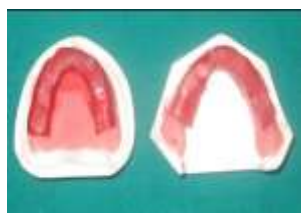

Figure: 1a



Figure 1b

The prepared base plate with wax rim was placed in patient's mouth and patient was positioned in digital panoramic machine KODAK 8000 PANORAMIC SYSTEM following proper protection and safety measures. (fig.2)

The radiograph thus obtained had the radiographic markers in position which was

later on subjected to metric analysis in vertical dimensions for each sphere using Trophy Dicom Imaging Software. For measurement in vertical directions, most prominent points in the vertical planes were marked and the diameters of the reference spheres were measured. (fig.3)

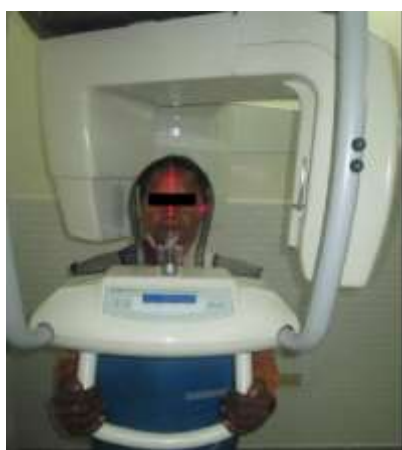

Figure.2: PATIENT POSITIONED IN PANORAMIC MACHINE

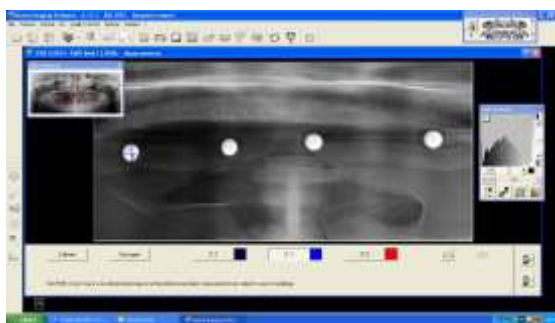


Figure.3: METRIC ANALYSIS OF OBTAINED RADIOGRAPH DONE ON DICOM IMAGING

STATISTICAL ANALYSIS

The statistical analysis was done using SPSS (Statistical Package for Social Sciences) Version 15.0 statistical Analysis Software. The values were represented in Number (%) and Mean±SD. *T* test was applied to compare the radiographic and real values and student "t" test was employed to test the significance of two means.

Calculation of mean radiographic diameter was done and percentage mean magnification was calculated using the formula as follows;

$$\text{Percentage (\%) magnification} = \left(\frac{\text{radiographic diameter}}{\text{original diameter}} \right) \times 100$$

$$\text{Magnification factor} = 1 + \left(\frac{\text{\% magnification}}{100} \right)$$

RESULT & DISCUSSION

Magnification of maxillary right posterior region, right anterior region, left anterior region, left posterior region vertically (Paired 't' test) (Table 1)

The percentage vertical magnification in maxillary posterior region ranges from 3.33% to 5.67% in a group A1 with 3 mm metallic sphere as reference object whereas its value in group B1 with 6 mm metallic sphere as reference object ranges from 4.83% to 7%. The percentage vertical magnification in maxillary anterior region ranges from 2.67% to 3% in a group with 3 mm metallic sphere as reference object whereas its value in group with 6 mm metallic sphere as reference object ranges from 2.67% to 3.83%.

Magnification of mandibular right posterior region, right anterior region, left anterior region, left posterior region vertically (Paired 't' test) (Table 2)

The percentage vertical magnification in mandibular posterior region ranges from 3.67% to 4% in a group A2 with 3 mm metallic sphere as reference object whereas its value in group B2 with 6 mm metallic sphere as reference object ranges from 5% to 5.67%. The percentage vertical magnification in mandibular anterior region ranges from -0.33% to 2.67% in a group with 3 mm metallic sphere as reference object whereas its value in group with 6 mm metallic sphere as reference object ranges from 3% to 4.50%.

Comparison of vertical magnification of various metallic spheres among different groups (Table 3)

On comparing the vertical magnification for both the groups a significant difference was obtained with all the values obtained were higher for group B with 6 mm metallic ball except for the percentage magnification in left anterior region which was higher for group A with 3 mm metallic ball.

Comparison of Magnification of metallic sphere of both the dimensions in Maxilla and Mandible (Overall – irrespective of Groups) (Table 4)

On comparing for maxilla and mandible in anterior and posterior region it was observed that all obtained values were obtained statistically significant and were higher in maxilla than in mandible.

Panoramic radiography is pioneer of modern dental radiology, as it produces a single projection image for the visualization of maxillomandibular structures.⁷ The anatomic intricacy of this region makes the diagnostic imaging a complex task, which was resolved by the advent of rotational panoramic radiography unit in 1946 hence revolutionizing the field of medicine and diagnosis. With the passage of time rotational panoramic radiography has

overcome many hurdles of imaging and evolved to the present form of digital acquisition system. Panoramic radiography is often the first-choice method for the implants planning because it provides information of the anatomical and pathological conditions of maxillomandibular region⁸ and vertical bony dimensions⁹ in a single film.

However, magnification is the major disadvantages of this image modality for treatment planning and without knowing the magnification degree and the image distortion, errors in measurements may occur.⁹ Distortion arises because the degree of magnification varies in the horizontal and vertical planes.¹⁰ To determine the exact magnification in a particular area, it requires the use of reference objects with known dimensions. The true magnification is calculated from the ratio of the projected to true length of the reference object.¹¹ The magnification, which differs in the vertical and horizontal direction depending on the anatomic areas, is a basic setback in panoramic radiographs.¹² In spite of these drawbacks, panoramic radiography has been the most commonly employed radiographic technique used for implant treatment planning.² Present study was conducted on edentulous patient keeping the 3mm and 6mm metallic sphere as reference object to determine the magnification of specified regions as sphere eliminates errors due to oblique projections, which is a major drawback with linear objects inclined in vertical plane to X- ray beam.¹³ hence it proves to be a more accurate method of evaluation of magnification which is been also been considered by various authors; Anil S¹⁴, Hoseini Zarch et al¹⁵, Vazquez L et al¹⁶, Ladeira D.B. Set al¹⁷, Yassaei Set al¹⁸, Vazquez L et al¹, Blum IR¹⁹, Tal H et al²⁰, Devlin H et al²¹, Schulze R et al¹³.

Magnification of KODAK 8000 PANORAMIC SYSTEM used in the study has been specified as 1.27+10% by the manufacturer. Present study was conducted for determining the area specific magnification in edentulous patients with

regards to determine the accuracy of radiographic measurements for implant placement. In the present study mean vertical magnification values for maxillary anterior region on right and left side for 3mm metallic sphere was 0.090 ± 0.074 (1.03) and 0.080 ± 0.103 (1.0267) respectively & for 6 mm metallic sphere it was 0.230 ± 0.106 (1.0383) and 0.160 ± 0.084 (1.0267) respectively. Mean vertical magnification values for maxillary anterior region was 0.198 ± 0.253 (1.0458) which was statistically significant. In a study done by Y K Kim et al⁸, on 24 implants placed in maxillary anterior region have specified the mean vertical magnification of 1.296 ± 0.019 . In another study by Gomez - Roman et al¹² mean vertical enlargement ratio at coronal end of placed implant was 1.25 and 1.27 in right and left side of maxillary canine region. The mean vertical magnification of panoramic radiographs in anterior maxilla was proposed to be 1.22 ± 0.02 ²²

In the present study mean vertical magnification values for mandibular anterior region on right and left side for 3 mm metallic sphere was -0.010 ± 0.088 (-0.33) and 0.080 ± 0.092 (1.0267) respectively & for 6mm metallic sphere was 0.270 ± 0.095 (1.0450) and 0.180 ± 0.114 (1.03) respectively. Mean vertical magnification in mandibular anterior region was 0.192 ± 0.248 (1.0443) which was statistically significant. In a study done by Y K Kim et al⁸, on 24 implants placed in mandibular anterior region have specified the mean vertical magnification of 1.2428 ± 0.649 . In another study done by Gomez - Roman et al¹² the mean vertical enlargement ratio at coronal end of placed implant was reported 1.26 and 1.27 in right and left side of mandibular canine region.

In the present study different diameters of metallic sphere were kept at the maxillary posterior region (1st molar) to determine the mean vertical magnification of specified panoramic machine. For the metallic sphere of 3 mm the magnification values for right and left side was 0.1 ± 0.094 (1.0333) and 0.170 ± 0.048 (1.0567) whereas, for 6 mm

sphere it was 0.420 ± 0.114 (1.07) and 0.290 ± 0.120 (1.0483) on right and left side respectively. The mean vertical magnification in maxillary posterior region (1st molar) was 0.3 ± 0.277 (1.0693). Near similar values of mean vertical enlargement has been reported by Gomez- Roman et al¹² in maxillary 1st molar on left and right side as 1.28 & 1.27 respectively. In a study done by Y K Kim et al⁸ vertical magnification 1.29 ± 0.259 was reported.

In the present study determined the mean vertical magnification of mandibular posterior region (1st molar). For the metallic sphere of 3 mm the magnification rate on right and left side was 0.110 ± 0.088 (1.0367) and 0.120 ± 0.092 (1.04) whereas, for 6 mm sphere it was 0.3 ± 0.133 (1.05) and 0.340 ± 0.165 (1.0567) on left and right side respectively. The mean vertical magnification in mandibular posterior region (1st molar) was 0.273 ± 0.267 (1.0631). Gomez- Roman et al¹² in a study reported that mean vertical enlargement in mandibular 1st molar on left and right side was 1.26 & 1.25 respectively. Y K Kim et al⁸ reported that vertical magnification was 1.2517 ± 0.403 whereas, Park JB has concluded that mean magnification of implants in molar and premolar region was 1.27 & 1.31 respectively²³. Study by Thanyakarn et al²⁴ has proposed vertical magnification in 2nd premolar and molar region to be 17% - 28%.

Present study has stated mean vertical magnification values of maxillary anterior and posterior region as 1.0458 and 1.069 whereas, for mandibular anterior and posterior region as 1.0443 and 1.0631 and all these values were statistically significant (<0.001). Mean vertical Magnification values are slightly higher for maxilla than mandible and are higher for posterior region than anteriors. These results were in accordance with Tronje et al (1981), that vertical magnification within the image layer does not exceed 10%. Similar results were also reported by; Kim YK et al⁸ who has proposed that a significant difference between magnification rate of implant

length between maxilla and mandible (<0.005). Also, Park JB²³ has suggested that vertical magnification in maxillary and mandibular region was higher for molars as compared to anterior. In a study done by Kamble RH et al²⁵ have mentioned very slight variation in maxilla and mandible i.e., 19.7% and 20% respectively which was in support with the data of present study. Similarly, Sattayasansskull et al²⁶ have reported higher magnification values in vertical plane for molar region (39%) compared to incisors and premolars (36%) which favors the present study analysis. Also, Thanyakarn C et al²⁴ have supported the result and have concluded that vertical magnification was lower for mandibular premolars than for maxillary second premolars and first molar. Scarfe et al^{27,17} have proposed lower magnification for maxilla and higher for mandible which was in contrast with the present study. In contrast in a study done by Lamia et al²⁸, have proposed that vertical magnification in incisors (30%) is higher compared to canine, premolar and molars (26.6%).

In the present study all the values of vertical mean magnification for all the specified regions of maxilla and mandible were lowest for 3 mm ball followed by 6mm metallic sphere respectively. Range of Mean Magnification rate for 3 mm sized sphere in different regions was from 2.00% to 12.67%. Range of Mean Magnification rate for 6mm sized sphere in different regions was from 3.50% to 11.38%. These numerical values have verified that larger will be the implant size, larger will be the magnification rate. In favor of the present observation, Schulze R¹³ had concluded that larger objects will probably produce larger variation in measurement. Similarly, Park JB²³ has suggested that higher magnification value from the group with implants having longest length. Also, the observation has been supported by Melder et al²⁹. In contrast to present study Devlin H²¹ has compared 2.5mm and 6mm metallic balls and thereby concluded that larger diameter of implant is more reliable.

	Subgroup A1 (n=10)					Subgroup B1 (n=10)				
	Mean magni.	SD	% magni.	't'	'p'	Mean magni.	SD	% magni.	't'	'p'
Right posterior	0.100	0.094	3.33	3.354	0.008	0.420	0.114	7.00	11.699	<0.001
Right anterior	0.090	0.074	3.00	3.857	0.004	0.230	0.106	3.83	6.866	<0.001
Left posterior	0.170	0.048	5.67	11.129	<0.001	0.290	0.120	4.83	7.660	<0.001
Left anterior	0.080	0.103	2.67	2.449	0.037	0.160	0.084	2.67	6.000	<0.001

Table 1: Magnification of maxillary right posterior region, right anterior region, left anterior region, left posterior region vertically (Paired 't' test)

	Subgroup A2 (n=10)					Subgroup B2 (n=10)				
	Mean magni.	SD	% magni.	't'	'p'	Mean magni.	SD	% magni.	't'	'p'
Right posterior	0.110	0.088	3.67	3.973	0.003	0.340	0.165	5.67	6.530	<0.001
Right anterior	-0.010	0.088	-0.33	-0.36	0.726	0.270	0.095	4.50	9.000	<0.001
Left posterior	0.120	0.092	4.00	4.129	0.003	0.300	0.133	5.00	7.115	<0.001
Left anterior	0.080	0.092	2.67	2.753	0.022	0.180	0.114	3.00	5.014	0.001

Table 2: Magnification of mandibular right posterior region, right anterior region, left anterior region, left posterior region vertically (Paired 't' test)

	Subgroup A (n=20)					Subgroup B (n=20)				
	Mean magni.	SD	% magni.	't'	'p'	Mean magni.	SD	% magni.	't'	'p'
Right posterior	0.125	0.084	4.17	9.415	<0.001	0.338	0.139	5.63	15.354	<0.001
Right anterior	0.060	0.096	2.00	3.972	<0.001	0.210	0.106	3.50	12.561	<0.001
Left posterior	0.348	0.609	11.58	3.609	0.001	0.683	0.587	11.38	7.359	<0.001
Left anterior	0.380	0.610	12.67	3.941	<0.001	0.505	0.572	8.42	5.580	<0.001

Table 3: Comparison of vertical magnification of various metallic spheres among different groups

	Maxilla (N=40)					Mandible (N=40)				
	Mean magni.	SD	% magni.	't'	'p'	Mean magni.	SD	% magni.	't'	'p'
Vertical molar	0.300	0.277	6.93	0.228	<0.001	0.273	0.267	6.31	0.204	<0.001
Vertical canine	0.198	0.253	4.58	0.133	<0.001	0.192	0.248	4.43	0.128	<0.001

Table 4: Comparison of Magnification of metallic sphere of both the dimensions in Maxilla and Mandible (Overall – irrespective of Groups)

CONCLUSION

Determination of bone quantity using orthopantomograms with radiologic markers has been used in various previous studies. However, three-dimensional assessment of anatomical structures cannot be done.³⁰ Present study has established that variation in magnification values differ with different panoramic systems and variation in magnification in vertical direction for both maxilla and mandible. This variation in magnification is related to the path of effective rotation centre, source to image receptor distance, object to film distance and position & shape of image layer. So, resultant magnification is specific for each panoramic machine.^{28,31} The present study has established the reliability of radiographic markers as a dependable method for radiographic assessment in edentulous patients.

Declaration by Authors

Ethical Approval: Present was approved by the Institutional human ethics committee & Institutional Research & Development committee. Each subject included in the study was informed about the nature and need of the study and written informed consent was obtained

Acknowledgement: None

Source of Funding: None

Conflict of Interest: The authors declare no conflict of interest.

REFERENCES

1. Vazquez L, Al Din Y N, Belsar U C, Combescure C, Bernand J. Reliability of vertical magnification factor on panoramic radiographs: Clinical Implication for Posterior Mandibular Implants. *Clin. Oral Impl Res.* 2011; 22:1420-1425.
2. Sakakura CE, Morais JAND, Loffredo LCM, Scaf G. A survey of radiographic prescription in dental implant Assessment. *Dentomaxillofacial Radiology.* 2003; 32:397-400.
3. Nikneshan S, Sharafi M, Emadi N. Evaluation of the accuracy of linear and angular measurements on panoramic radiographs taken at different positions *Imaging Sci Dent* 2013; 43: 191-6.
4. Langland O, Sippy F, Morris C, Langlais R. Principles and practice of panoramic radiography. WB Saunders: Philadelphia 1989.
5. Stramotas S, Geenty J P, Petocz P, Ali Darendeliler M. Accuracy of linear and angular measurements on panoramic radiographs taken at various positions in vitro. *European Journal of Orthodontics* 2002; 24:43-52.
6. Yim JH, Ryu DM, Lee BS, Kwon YD. Analysis of digitalized panorama and conebeam computed tomographic image distortion for the diagnosis of dental implant surgery. *J Craniofac Surg* 2011; 22:669-73.
7. Benson B W, Liang H, Flint D J. Panoramic radiography: Digital Technology Fosters Efficiency. *Compendium*, 2011;32(4):6-8.
8. Kim Y-K, Park J-Y, Kim S-G, Kim J-S, Kim J-D. Magnification rate of digital panoramic radiographs and its effectiveness for pre-operative assessment of dental implants *Dentomaxillofacial Radiology* 2011;40: 76-83.
9. Haghnegahdar A, Bronoosh P. Accuracy of linear vertical measurements in posterior mandible on panoramic view. *Dent Res J* 2013; 10:220-4.
10. Schulze R, Krummenauer F, Schalldach F, d'Hoedt B. Precision and accuracy of measurements in digital panoramic radiography *Dentomaxillofacial Radiology* .2000; 29: 52 – 56.
11. Blum IR, Smith GA. A quick and simple method to obtain a radiographic evaluation of remaining alveolar bone height before implant placement. *Australian Dental Journal* 2002;47:(3):266-268.
12. Gomez-Roman et al. Area-Dependent Enlargement Ratios of Panoramic Tomography on Orthograde Patient Positioning and Its Significance for Implant Dentistry. *Int J Oral Maxillofac Implants* 1999; 14:248-257.
13. Schulze R, Krummenauer F, Schalldach F, d'Hoedt B. Precision and accuracy of measurements in digital panoramic radiography *Dentomaxillofacial Radiology* .2000; 29: 52 – 56.
14. Anil S, Al-Ghamdi HS. A Method of Gauging Dental Radiographs during Treatment Planning for Dental Implants. *J Contemp Dent Pract* 2007; (8)6:082-088.

15. Hoseini Zarch SH, Bagherpour A, Javadian Langaroodi A, Ahmadian Yazdi A, Safaei A. Evaluation of the Accuracy of Panoramic Radiography in Linear Measurements of the Jaws. *Iran J Radiol.* 2011; 8(2):97-102.
16. Vazquez L, Nizam Al Din Y, Combescure C, Nedir R, Bischof M, Dohan Ehrenfest DM et al. Accuracy of vertical height measurements on direct digital panoramic radiographs using posterior mandibular implants and metal balls as reference objects. *Dentomaxillofac Radiol* 2013; 42: 20110429.
17. Ladeira DBS, Dibo da Cruz a, Maria de Almeida S, Bóscolo FN. Evaluation of the Panoramic Image Formation in Different Anatomic Positions. *Braz Dent J* 2010;21(5): 458-462.
18. Yassaei S, Ezoddini-Ardakani F, Ostovar N. Predicting the actual length of premolar teeth on the basis of panoramic radiology. *Indian J Dent Res* 2010;21(4):468-473.
19. Blum IR, Smith GA. A quick and simple method to obtain a radiographic evaluation of remaining alveolar bone height before implant placement. *Australian Dental Journal* 2002;47:(3):266-268.
20. Tal H., Moses O. A comparison of panoramic radiography with computed tomography in the planning of implant surgery. *Dentomaxillofac. Radiol.*, 1991; 20(2):40-42.
21. Devlin H, Yuan J. Object position and image magnification in dental panoramic radiography: a theoretical analysis. *Dentomaxillofac Radiol* 2013; 42: 20120045.
22. Bashizade H, Molaei N, Teimoorinezhad A. Evaluation of vertical magnification of panoramic radiography by CT scan sections for dental implant *Journal of Dental Medicine-Tehran University of Medical Sciences* 2013;26(1):64-70.
23. Park JB. The evaluation of digital panoramic radiographs taken for implant dentistry in the daily practice. *Med Oral Patol Oral Cir Bucal.* 2010 Jul 1;15 (4):e663-6.
24. Thanyakarn C., Hansen K., Roblin M., Akesson L. Measurements of tooth length in Tooth length in panoramic radiographs. 1: The use of indicators *Dentomaxillofac. Radiol.* 1992;21(2):26-30.
25. Kamble RH, Patil SV, Hazarey PV, Ghom A G. Evaluation and Comparison of Accuracy of Measuring the Position of Miniscrew Implants using Two-dimensional Orthopantomogram. *Journal of Indian Academy of Oral Medicine and Radiology*,2011;23(2):92-96.
26. Sattayasanskul W, Brook IM, Lamb DJ. Dense hydroxylapatite root replica implantation: Measurement of mandibular ridge preservation. *The international journal of Oral and Maxillofacial Implants* 1988;3: 203-6.
27. Scarfe WC, Eraso FE, Farman AG. Characteristics of the Orthopantomograph OP100. *Dentomaxillofac Radiol* 1998; 27:51- 57.
28. Lamia H. AL-Nakib. Magnification in panoramic radiography. *J Bagh Coll Dentistry* 2005; 17(3): 45- 47.
29. McIver FT, Brogan DR, Lyman GE. Effect of head positioning upon the width of mandibular tooth images on panoramic radiographs. *Oral Surg* 1973; 35: 698 - 707.
30. Schwarz M, Rothman S, Rhodes M, Chafetz N. Computed tomography: Part I. Preoperative assessment of the mandible for endosseous implant surgery. *Int J Oral Maxillofac Implants* 1987; 2:137-141.
31. Bickström A., Welander U., McDavid W.D., Tronje G, Sanderink G.C.H. The effect of system parameters on resolution in rotational panoramic radiography. A mathematical analysis. *Dentomaxillofac. Radiol.* 1989; 18(11):169-176.

How to cite this article: Shweta Dwivedy, Sunira Chandra, Nivedita Tayde, Sudarshan Pandit, Juhi Singh. Evaluation of vertical magnification of a digital panoramic machine kodak 8000 for implant planning in complete edentulous patients. *Int J Health Sci Res.* 2023; 13(9):186-193.
DOI: <https://doi.org/10.52403/ijhsr.20230927>
