

Management of Complicated Crown Fracture with Biodentine Partial Pulpotomy and Fracture Segment Reattachment

Vidhi Thakur¹, Shweta Mittal², Ritika Yadav³

¹Post Graduate Student 3rd Year, Dept of Conservative Dentistry and Endodontics, PGIDS, Rohtak, India.

²Professor, Dept of Conservative Dentistry and Endodontics, PGIDS, Rohtak, India.

³MDS, Conservative Dentistry and Endodontics, PGIDS, Rohtak, India.

Corresponding Author: Shweta Mittal

ABSTRACT

Fracture of maxillary anterior teeth is common in young individuals. Conservative management of complicated crown fractures helps in preservation of tooth structure, vitality and esthetics. This case report describes a conservative technique of managing a case of complicated crown fracture by performing partial pulpotomy with biodentine followed by fracture segment reattachment.

Keywords: Complicated crown fracture, Partial pulpotomy, Fractured segment reattachment

INTRODUCTION

Traumatic dental injuries (TDIs) occur frequently in children and young adults, comprising 5% of all injuries ⁽¹⁾. These often result in crown fractures and are classified as enamel fractures, uncomplicated crown fractures (enamel-dentin fractures), complicated crown fractures (involving enamel, dentin, and exposure of the pulp), and crown-root fractures, which may be uncomplicated (no pulpal involvement) or complicated (with pulpal involvement) or a Class 3 fracture. ⁽²⁾

Complicated crown fractures accounts for 0.9%-13% of all dental injuries. ⁽³⁾ Management of these fractures depends on multiple factors such as time lapse between trauma and the initiation of treatment, level and position of tooth fracture line, stage of root development, pulpal involvement, availability of displaced tooth fragments and concomitant alveolar bone injury ⁽⁴⁾.

Considering these factors, various treatment approaches available include removal of fractured segment and

restoration ⁽⁵⁾, root canal treatment or vital pulp therapy procedures followed by reattachment of the fractured segments or composite build up or crowns, gingivectomy and crown lengthening ⁽⁶⁾, orthodontic extrusion with/without gingivoplasty ^(5,6), extraction followed by fixed partial denture or implant ⁽⁷⁾. A conservative approach should be our first option at treating such fractures owing to advancements in vital pulp therapy and adhesive dentistry. Fracture reattachment is widely accepted technique. It restores the tooth integrity and color by conserving original tooth structure.

Vital pulp therapy (VPT) is a conservative treatment for reversible pulpal injuries that promotes pulp tissue healing and stimulates hard tissue formation in order to preserve pulp vitality. These include partial and full pulpotomies. Partial pulpotomy involves the removal of 2-3 mm from the inflamed coronal pulp beneath the exposure followed by placement of a suitable agent over the remaining coronal pulp and a restoration that provides a hermetic seal ⁽⁸⁾. Traditionally, calcium

hydroxide (CH) was the most favored material for VPT; however, American Academy of Pediatric Dentistry guidelines and several authors have recommended Mineral trioxide aggregate (MTA) as a more suitable option than CH.⁽⁹⁾ However, discoloration was a major drawback for its use in anterior teeth. With the advent of calcium silicate based cements, recent alternatives such as Biodentine (BD) have been introduced to combat the drawbacks of MTA. BD is a biocompatible and bioactive material that promotes pulp healing when applied directly in contact with the pulp tissue.⁽¹⁰⁾ Currently, only few case reports have been published related to BD pulpotomies on permanent traumatized teeth⁽¹¹⁻¹³⁾

This case report aims to describe and evaluate the outcome of re-attachment of a fractured segment of a mature anterior tooth with pulpal exposure treated with biodentine partial pulpotomy.

CASE REPORT

A 19-year-old male patient reported to the Department of Conservative Dentistry and Endodontics Post Graduate Institute of Dental Sciences, Rohtak, Haryana with a crown fracture in the upper front left region of the jaw 2 hours after sports injury. The patient carried the fractured segment with him wrapped in a tissue. Patient complained of mild sensitivity with no pain.

The fractured segment was immediately immersed in normal saline. A detailed history of patient was taken. Patient's medical history was not significant. Extra oral examination revealed no sign of asymmetry and abnormality. Intraoral examination revealed horizontally oblique fracture involving the pulp with respect to maxillary left central incisor. Tooth showed positive response to electric pulp test, pulp exposure was visible and was sensitive to stimuli. The tooth showed no signs of mobility, displacement or soft tissue lacerations. Alveolar bone was intact with no sign of fracture.

Radiographic examination revealed mature permanent tooth with complicated crown fracture [Fig 1(A)]. Periapical changes were not appreciated.

The fractured segment was reapproximated to the remaining tooth structure. On approximation, it was well adapted with no gap between the two segments. A conservative treatment approach with biodentine partial pulpotomy was planned. The patient was explained about the procedure and consent was taken.

Patient was anesthetized by using 2% lignocaine hydrochloride with epinephrine 1:80,000 (ICPA Health Products Ltd, Ankleshwar, India) and the tooth was isolated using a rubber dam [Fig 1(B)]. A sterile round diamond bur at high speed with water as coolant was used to remove superficial 2 mm of the exposed pulp from the pulp chamber. Pulp tissue was then irrigated with 3% sodium hypochlorite (NaOCl). A cotton pellet soaked with NaOCl was gently placed on the exposed pulp tissue for five minutes to disinfect and obtain hemostasis [Fig 1(C)]. Once hemostasis was obtained, Biodentine was mixed according to the manufacturers' instructions and was applied using an amalgam carrier [Fig 1(D)]. After allowing the cement to set for 10 to 12 minutes, the cement was covered with glass ionomer cement before proceeding for fractured segment reattachment.

Internal dentin grooves were prepared on the fragment and the tooth. The tooth and the fragment were acid etched with 37% phosphoric acid (Ivoclar Vivadent Eco Etch) for 15 seconds and rinsed thoroughly and dried showing the frosty appearance [Fig 1(E, F, G)]. Two coats of bonding agent (Econom Bond) were applied and cured followed by flowable composite application (Ivoclar Vivadent TE-Econom Bond) and reattachment of the fragment [Fig 1(H)]. Every surface was cured for 40 seconds. After reattachment, over contouring was done in which a preparation was made on the buccal surface around the fracture line by means of a cylindrical

diamond-finishing bur. The surface was then etched; bonded and composite restoration (Ivoclar Vivadent Econom Plus) was done and cured as described earlier. Final finishing and polishing were done with finishing burs and polishing disks. Final radiograph was taken [Fig 1(I)].

Follow up was done at 1, 3 and 12 months. Pulp vitality was maintained and tooth showed no clinical symptoms. Periapical radiograph was normal with no periapical changes [Fig 1(J)].

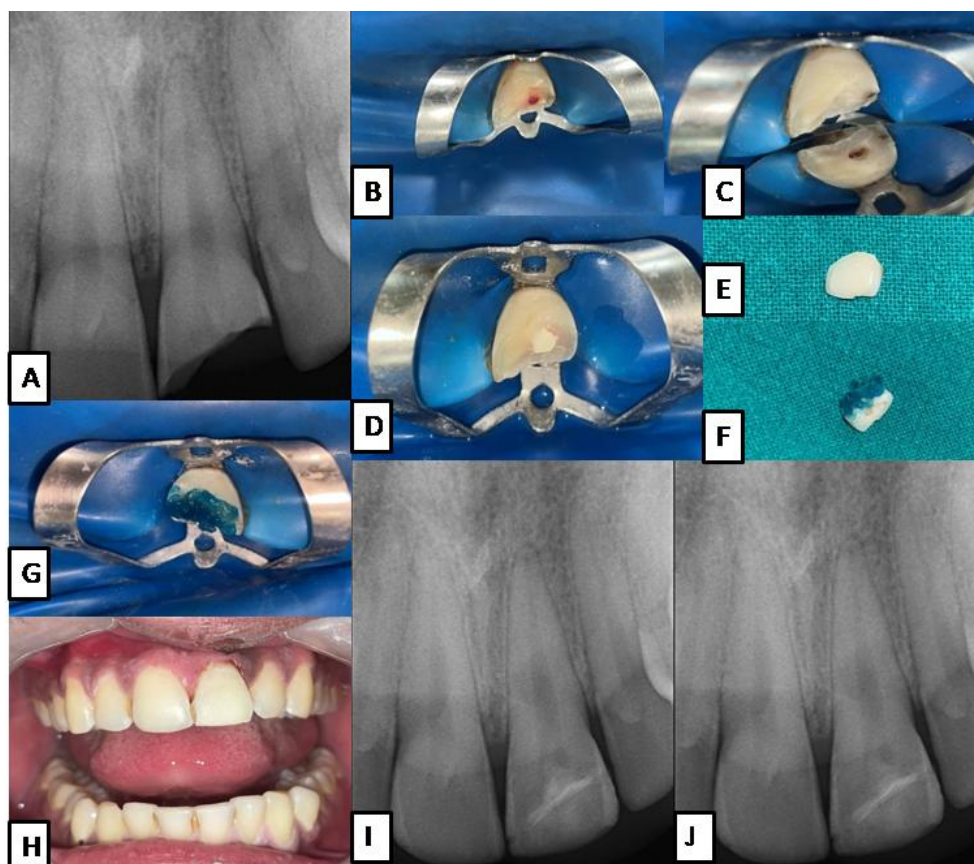


Fig 1(A) Preoperative Radiograph (B) Preoperative Clinical picture (C) Partial pulpotomy and haemorrhage control (D) Biodentine placed (E) Fractured segment (F, G) Etched fragment and tooth (H) Post operative clinical picture (I) Post operative radiograph (J) 12 month follow up radiograph

DISCUSSION

Complicated crown fractures can be treated by endodontic root canal treatment followed by crown or can be conservatively managed with a favorable prognosis by the virtue of advances in vital pulp therapy procedures. The primary objective should be conservation of the tooth structure and preservation of pulp vitality. Thus, treatment plan should be based on current understanding of pulpal inflammation after traumatic dental injury.⁽¹⁴⁾

In the present case report partial pulpotomy was preferred as a treatment modality because the patient reported within 24 hours and pulp exposure was small (less

than 1 mm). Cvek *et al.* reported that partial pulpotomies after complicated crown fractures had a 96% success rate.⁽⁸⁾ Preservation of pulp vitality, cell rich coronal pulp tissue are the advantages offered by partial pulpotomy which ultimately provide better healing potential and physiologic dentin deposition.⁽²⁾ In the case described above, the coronal 2 mm of pulp tissue was removed and bleeding stopped within 5-7 mins to achieve a healthy pulp stump. Absolute disinfection was ensured throughout the procedure. The success criteria of partial pulpotomy for such cases relies on ability to control pulpal haemorrhage and visual inspection of an

underlying healthy pulp stump.⁽¹⁴⁾ Various materials have been employed for pulpotomy procedures. Traditionally, calcium hydroxide (CH) was the most favoured material for VPT.⁽⁶⁾ In recent times, MTA has been extensively used as it induces a thicker and a higher quality of hard tissue barrier and displays milder inflammatory response.⁽¹⁵⁾

In this case report, Biodentine was used to overcome the discoloration concern associated with the use of MTA. Quality of hard tissue barrier is similar to that formed by MTA. Also, Biodentine has a setting time of 10-12 minutes as compared to longer setting time of MTA.⁽¹⁶⁾

If the fractured segment in cases of complicated crown structure is available with the patient, reattachment is a viable option. In this case, the fragment was available en mass and closely adapted to the fractured tooth. The segment reattachment technique has been widely accepted with the development of composites and resin adhesives.⁽⁶⁾ This technique requires only a thin layer of composite resin and restores the original form and color of the tooth that often provides the best aesthetic result. The light cure flowable composite ensures accurate fracture segment adaptation and color stability. Additionally, in the present case, preparation of internal groove in the dentine and over contoured preparation provide highest fracture strength recovery and highest bond strength recovery⁽¹⁷⁾ as compared to simple reattachment.

One of the disadvantages associated with the reattachment procedure is excessive dehydration of the segment possess a risk of discoloration.⁽¹⁸⁾ Another problem is the possible debonding of the fractured segment following second trauma. In this case, the fractured segment was immediately immersed in normal saline to prevent dehydration. Preparation of internal groove in the dentine and over contoured preparation was done to ensure good retention.

The case was followed for one year. The electric pulp test and cold test showed a

response similar to the adjacent tooth and radiograph showed no signs of periodontal ligament widening or periapical changes.

CONCLUSION

Complicated crown fractures can be managed conservatively following a minimal intervention strategy employing pulpotomy and fracture segment reattachment procedure. Complete understanding of techniques, risk vs benefit ratio, evidence, cost and patient consent should be taken into account when choosing a treatment plan. Biodentine pulpotomies are a successful alternative to MTA and Calcium hydroxide when treating anterior traumatized teeth. Long term follow ups are must to assess tooth prognosis and treat complications as early as possible, if any.

Acknowledgement: None

Conflict of Interest: None

Source of Funding: None

REFERENCES

1. Bourguignon C, Cohenca N, Lauridsen E, Flores MT, O'Connell AC, Day PF, Tsilingaridis G, Abbott PV, Fouad AF, Hicks L, Andreasen JO. International Association of Dental Traumatology guidelines for the management of traumatic dental injuries: 1. Fractures and luxations. *Dental Traumatology*. 2020 Aug; 36(4):314-30.
2. Bakland LK. Revisiting traumatic pulpal exposure: Materials, management principles, and techniques. *Dental Clinics*. 2009 Oct 1; 53(4):661-73.
3. Martin Trope, Frederic Barnett, Asgier Sigurdsson, Noah Chivian. The role of endodontics after dental traumatic injuries. In: Hargreaves K, Cohen S, editors. *Cohen's pathways of the pulp*. 10 ed. St. Louis: Mosby; 2010. p. 620-54.
4. Aggarwal V, Logani A, Shah N. Complicated crown fractures—management and treatment options. *International endodontic journal*. 2009 Aug; 42(8):740-53.
5. Olsburgh S, Jacoby T, Krejci I. Crown fractures in the permanent dentition: pulpal

- and restorative considerations. Dental Traumatology. 2002 Jun;18(3):103-15.
6. Trushkowsky RD. Esthetic, biologic, and restorative considerations in coronal segment reattachment for a fractured tooth: a clinical report. Journal of Prosthetic Dentistry. 1998 Feb 1;79(2):115-9.
 7. Meiers JC, Freilich MA. Chairside prefabricated fiber-reinforced resin composite fixed partial dentures. Quintessence International. 2001 Feb 1;32(2).
 8. Cvek M. A clinical report on partial pulpotomy and capping with calcium hydroxide in permanent incisors with complicated crown fracture. Journal of endodontics. 1978 Jan 1;4(8):232-7.
 9. American Academy of Pediatric Dentistry. Guidelines on pulp therapy for primary and immature permanent teeth.
 10. Malkondu Ö, Kazandağ MK, Kazazoğlu E. A review on biodentine, a contemporary dentine replacement and repair material. BioMed research international. 2014 Jun 16;2014.
 11. Martens L, Rajasekharan S, Cauwels R. Pulp management after traumatic injuries with a tricalcium silicate-based cement (Biodentine™): a report of two cases, up to 48 months follow-up. European Archives of Paediatric Dentistry. 2015 Dec;16(6):491-6.
 12. Villat C, Grosgeat B, Seux D, Farge P. Conservative approach of a symptomatic carious immature permanent tooth using a tricalcium silicate cement (Biodentine): a case report. Restorative Dentistry & Endodontics. 2013 Nov;38(4):258.
 13. Borkar SA, Ataide I. Biodentine pulpotomy several days after pulp exposure: Four case reports. Journal of conservative dentistry: JCD. 2015 Jan;18(1):73.
 14. Fatima S, Alam S, Kumar A, Andrabi SM, Rehman A. Minimal intervention treatment of crown-root fracture in a mature permanent tooth by MTA pulpotomy and Fragment Reattachment: A Case Report. Australian Endodontic Journal. 2020 Dec 12.
 15. Witherspoon DE, Small JC, Harris GZ. Mineral trioxide aggregate pulpotomies: a case series outcomes assessment. The Journal of the American Dental Association. 2006 May 1;137(5):610-8.
 16. Kaur M, Singh H, Dhillon JS, Batra M, Saini M. MTA versus Biodentine: review of literature with a comparative analysis. Journal of clinical and diagnostic research: JCDR. 2017 Aug;11(8):ZG01.
 17. Pusman E, Cehreli ZC, Altay N, Unver B, Saracbası O, Ozgun G. Fracture resistance of tooth fragment reattachment: effects of different preparation techniques and adhesive materials. Dental Traumatology. 2010 Feb;26(1):9-15.
 18. Maitin N, Maitin SN, Rastogi K, Bhushan R. Fracture tooth fragment reattachment. Case Reports. 2013 Jul 12;2013: bcr2013009183.
- How to cite this article: Thakur V, Mittal S, Yadav R. Management of complicated crown fracture with biodentine partial pulpotomy and fracture segment reattachment. *Int J Health Sci Res.* 2021; 11(6):152-156. DOI: <https://doi.org/10.52403/ijhsr.20210623>
