

Schwannoma of the Nasal Cavity: A Rare Case Report

Rashmi Monteiro², Bhavana Garg¹, Indu Choudhary¹

¹Assistant Professor, ²Senior Resident,
Department of Pathology, Pacific Medical College and Hospital, Udaipur, Rajasthan

Corresponding Author: Indu Choudhary

ABSTRACT

Various soft tissue lesions occurring in the nasal cavity clinically present as nasal polyps. Schwannoma is a rare neoplasm of the nose and peripheral nervous system and belongs to the group of nerve sheath tumors. Herein, we report a case of schwannoma in the nasal cavity due to its rarity. A 46 years old female came with complains of headache, pain in the left nostril, disturbed sleep, hyposmia, post nasal drip and left sided nasal blockage. On rhinoscopy, nasal septum deviation to the right and a polypoidal mass in the left nasal cavity was noted. Computed tomography of nose and PNS revealed a well-defined heterogeneously enhancing round to oval shaped soft tissue density lesion in the left nasal cavity. Functional endoscopic sinus surgery under general anaesthesia was performed for the excision of the mass and was sent for histopathological examination. Histopathological examination showed it to be schwannoma and it was similar to their soft tissue counterparts. To conclude, schwannoma must be considered as a possibility, when a patient presents with a soft tissue mass in the nasal cavity.

Keywords: Schwannoma, nerve sheath tumors, nasal polyp.

INTRODUCTION

Schwannoma belongs to the group of nerve sheath tumors. It is composed of differentiated neoplastic Schwann cells and is rarely malignant. It is also called as neurilemmoma and neurinoma. It is a benign encapsulated tumor with a dimorphic histology composed of cellular or Antoni A regions with loose myxoid Antoni B areas. Occurrence of polypoidal lesions is commonly noted in the nasal cavity but usually they are inflammatory polyps. Nerve sheath tumors rarely arise in the nasal cavity and mostly arise from the branches of trigeminal nerve. [1] 25-45% of schwannomas are located in the head and neck region, among which only 4% cases of schwannomas occur in the sinonasal cavity. [2]

We herein report a rare case of schwannoma arising from the nasal cavity.

CASE REPORT

A 46 years old female, housewife, came to the ENT OPD with complains of headache in bilateral temporal region which was dull in character, pain in the left nostril, disturbed sleep and hyposmia since 6 months. She also complains of post nasal drip and left sided nasal blockage since 1 year. She experienced nasal obstruction more during night time. There was no history of nasal bleeding, facial numbness, visual or hearing disturbances.

On clinical examination the nasal dorsum appeared normal. Eyeball movements and all cranial nerve examination were normal. On rhinoscopy, the nasal septum was deviated to the right side and a polypoidal mass was noted in the left nasal cavity. Computed tomography of nose and PNS revealed a well-defined heterogeneously enhancing round to oval shaped soft tissue density lesion measuring 33 x 25 mm in the left nasal cavity possibly arising from the lateral wall of the nasal

cavity without erosion or destruction of the underlying bone and nasal septum. The radiological findings suggested a benign lesion.

Under general anaesthesia, functional endoscopic sinus surgery was performed. Piecemeal removal of the polyp was done. Hemostasis was achieved and packing was done. Post-operative period was uneventful. The mass removed was sent for histopathological examination.

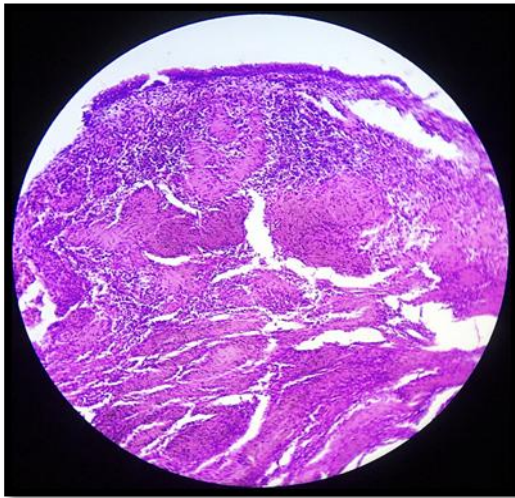


Figure 1 - Lesion lined by stratified squamous epithelium with underlying tissue showing spindle shaped cells arranged in interlacing fascicles with nuclear palisading. Antony A and Antony B areas, (H&E, 40x)

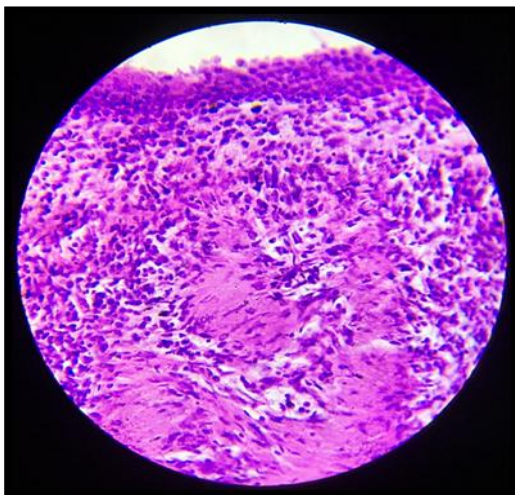


Figure 2 - Verocay bodies (H&E, 40x)

Grossly, multiple irregular, grey white, soft tissue fragments were received, altogether measuring 2x1x1cm. Microscopic examination of the sections studied revealed multiple fragments, partly lined by squamous metaplasia. Underlying tissue

exhibited a benign neoplasm with dimorphic growth pattern, composed of spindle cells, arranged in hypercellular (Antoni A) and hypocellular (Antoni B) areas (Figure 1). Hypercellular areas show eosinophilic cell bodies, nearly encircled by rows of nuclei, forming Verocay bodies (Figure 2). The nuclei are elongated, occasionally pointed and wavy. The hypocellular areas are loosely arranged in a myxoid matrix accompanied by thin strands of collagen. Few congested blood vessels and scattered chronic inflammatory infiltrate were noted. No necrosis or increased mitotic activity was observed. Positivity for S-100 protein was noted on immunohistochemistry (Figure 3) which confirmed our diagnosis of nasal schwannoma.

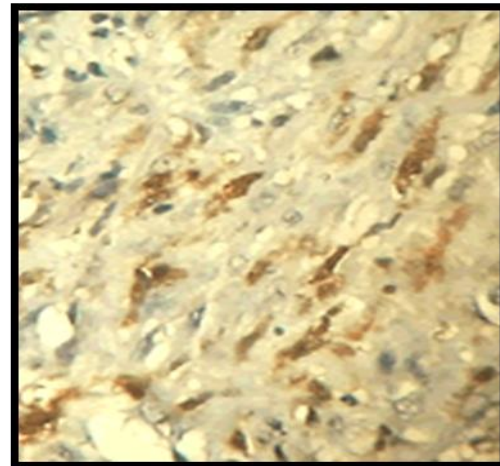


Figure 3- Positivity for S-100 (IHC 1000x)

On follow up, the patient was asymptomatic and showed no evidence of residual tumor or recurrence on nasal endoscopy.

DISCUSSION

Schwannomas belong to the group of nerve sheath tumors, composed of differentiated neoplastic Schwann cells. They are mostly benign and rarely transform into malignant tumors. [3-5] The most common site of involvement is peripheral nerves of the skin and subcutaneous tissue of the head and neck and along the flexor surfaces of the extremities. Schwannomas occurring in head and neck account for 25-45 % and only 4 % of this occurs in the

sinonasal tract. [2] Only a few cases of Schwann cell tumors occurring in nasal cavity, alae nasi, ethmoid region, frontal sinus, sphenoid sinus and maxilla have been reported in the literature. [2]

According to the review done by Mosalleum and Phillips the mean age of presentation of schwannomas in nasal cavity was 39 years, ranging from 11-82 years and a female predominance was noted with F:M ratio of 1.8:1. [1] Our patient was a 46 years old female. Nasal obstruction is the most common symptom of a nasal cavity schwannoma, followed by epistaxis, while other less common symptoms include visual disturbances, cranial nerve palsy, facial swelling and exophthalmos. [6-10] Mostly cases are associated with the deviation of the nasal septum.

Differential diagnosis of schwannoma in the nasal cavity is neurofibroma, meningiomas, angiofibroma, glomangiopericytoma, leiomyomas, inflammatory polyps, inverted papilloma, melanoma and Neuroblastoma. [1,11] Schwannomas showing ancient change may be wrongly diagnosed as malignant peripheral nerve sheath tumors. Strong immunostaining for S-100 is observed in schwannomas that can differentiate them from malignant peripheral nerve sheath tumors. [11]

Debulking is usually the treatment done for benign schwannomas, with close follow up. Complete surgical excision is encouraged, depending on the site and extension of the lesion. [11] Approach through endoscopy has made it possible to excise the tumor in a piecemeal fashion. After excision of the lesion, recurrence is rare but malignant changes in a long standing benign schwannoma have been reported, therefore a close follow-up is recommended. [11] In the present case there was no recurrence on follow-up.

CONCLUSION

Schwannomas occurring in the nasal cavity are rare. They clinically present as a nasal polyp. Radiological findings may

suggest the indolent nature of the tumor and may show bone destruction or soft tissue invasion, if present. Histopathology remains the gold standard method for giving the accurate diagnosis. Schwannomas should be considered as a differential diagnosis when a soft tissue mass is noted in the nasal cavity.

REFERENCES

1. Mosalleum EM, Phillips VM. Schwannoma of the nasal cavity: A case report and a review. *Sudan Med Monit* 2015;10:27-30.
2. Singh M, Bhagat S, Sharma DK, Monga R, Chhabra N. A large sinonasal schwannoma: a rare entity. *Int J Otorhinolaryngol Head Neck Surg* 2017;3:1126-9.
3. Leu YS, Chang KC. Extracranial head and neck schwannomas: A review of 8 years experience. *Acta Otolaryngol* 2002;122:435-7.
4. Colreavy MP, Lacy PD, Hughes J, Bouchier-Hayes D, Brennan P, O'Dwyer AJ, *et al.* Head and neck schwannomas – A 10 year review. *J Laryngol Otol* 2000;114:119-24.
5. Purohit JP, Sharma VK. Malignant schwannoma of nasal cavity. *Indian J Otolaryngol Head Neck Surg* 1997; 49:62-3.
6. Jacopo G, Micaela I, Italo C, Luigi C, Larocca LM, Gaetano P. Atypical sinonasal Schwannomas: A difficult diagnostic challenge. *Auris Nasus Larynx*. 2009;36:482-6.
7. Berlucchi M, Piazza C, Blanzuoli L, Battaglia G, Nicolai P. Schwannoma of the nasal septum: A case report with review of the literature. *Eur Arch Otorhinolaryngol* 2000;257:402-5.
8. Ohashi R, Wakayama N, Kawamoto M, Tsuchiya S, Okubo K. Solitary nasal schwannoma: Usefulness of CD34 and calretinin staining for distinction from histological mimics. *J Nippon Med Sch* 2013;80:300-6.

9. Hu J, Bao YY, Cheng KJ, Zhou SH, Ruan LX, Zheng ZJ. Computed tomography and pathological findings of five nasal neurilemmomas. *Head Neck Oncol* 2012;4:26.
10. Wada A, Matsuda H, Matsuoka K, Kawano T, Furukawa S, Tsukuda M. A case of schwannoma on the nasal septum. *Auris Nasus Larynx* 2001;28: 173-5.
11. Dhawle MS, Rathod SG, Bhatkule MA, Bindu RS. Sinonasal Schwannoma–A Case Report. *Journal of clinical and diagnostic research: JCDR*. 2017 May; 11(5):ED22.

How to cite this article: Monteiro R, Garg B, Choudhary I. Schwannoma of the nasal cavity: a rare case report. *Int J Health Sci Res*. 2020; 10(1):117-120.
